

## RESEARCH FINGERPRINT

## IDENTIFIER

LJMHR-226575

## PEER REVIEW

Double Blind

## SIMILARITY CHECK

Perplexity AI and iThenticate

## ACCESS

Open Access

## LANGUAGE

English

## PRINT ISSN

2515-5784

## ONLINE ISSN

2515-5792

## EDITION

## ABBREVIATION

LJMHR

## VOLUME

26

## ISSUE

4

## YEAR

2026

## KEY DATES

## RECEIVED

2026-03-23

## ACCEPTED

2026-04-30

## CATALOGING

## CROSSMARK DOI

10.34257/LJMHR226575UK

## MESH CLASS

D001047, D002121, D014082

## NLMC CLASS

WU 230

## Article Record

# Calcium Hydroxide Induced Apexification in an Immature, Non-Vital Permanent Tooth – A Case Report

CORRESPONDENCE → +



## AUTHORS &amp; AFFILIATIONS

**Dr. Nagaveni NB ¶\***

Professor

**Dr. Disha P. Temker**

ζ Post-graduate student

**Dr. Apratim Ganguly**

ζ Post-graduate student

**Dr. Mallikarjuna K**

Γ Professor and HOD

¶ Department of Pediatrics and Preventive Dentistry, College of Dental Sciences, Davangere, India

## ABSTRACT

The purpose of the present manuscript is to show case successful formation of apical barrier in an immature young permanent tooth following dental trauma using calcium hydroxide as an intra-canal medicament. Following 9 month follow-up, apical barrier formation and absence of periapical radiolucency was evident on intraoral periapical radiographic examination with clinical absence of signs and symptoms. This case report strongly confirms that calcium hydroxide still remains as age old, gold standard medicament in inducing apical barrier formation thereby facilitating a dental practitioner to perform smooth root canal treatment.

Index Terms: Apexification • Apical barrier formation • Blunder bus canal • Calcium hydroxide • Immature • non-vital tooth

## FUNDING

No external funding was declared for this work.

## CONFLICTS

The authors declare no conflict of interest.

## AI USAGE

No generative AI was used for analysis or results.

## HOW TO CITE


NB et al. (2026). Calcium Hydroxide Induced Apexification in an Immature, Non-Vital Permanent Tooth – A Case Report. London Journal of Medical and Health Research, 26(4), 24-30. DOI: 10.34257/LJMHR226575UK

ACCESS  
ONLINE

**METADATA CONTINUATION**

---

**AUTHOR CONTACT QR LEDGER**

Dr. Nagaveni NB[[\* 

---

**ARCHIVAL RECORD**

LJMHR · Vol 26 · Issue 4 · 2026  
Article ID LJMHR-226575 · DOI 10.34257/LJMHR226575UK  
Print ISSN 2515-5784 · Online ISSN 2515-5792

## CASE REPORT

# Calcium Hydroxide Induced Apexification in an Immature, Non-Vital Permanent Tooth - A Case Report

Dr. Nagaveni NB<sup>¶\*\*</sup>, Dr. Disha P. Temker<sup>¶a</sup>, Dr. Apratim Ganguly<sup>¶a</sup>, and Dr. Mallikarjuna K<sup>¶b</sup>

## QUALIFICATIONS / ROLES

\* Professor  
a Post-graduate student  
b Professor and HOD

## AFFILIATIONS

¶ Department of Pediatrics and Preventive Dentistry, College of Dental Sciences, Davangere, India

## Abstract

The purpose of the present manuscript is to show case successful formation of apical barrier in an immature young permanent tooth following dental trauma using calcium hydroxide as an intra-canal medicament. Following 9 month follow-up, apical barrier formation and absence of periapical radiolucency was evident on intraoral periapical radiographic examination with clinical absence of signs and symptoms. This case report strongly confirms that calcium hydroxide still remains as age old, gold standard medicament in inducing apical barrier formation thereby facilitating a dental practitioner to perform smooth root canal treatment.

**Keywords:** Apexification, Apical barrier formation, Blunder bus canal, Calcium hydroxide, Immature, non-vital tooth

**Correspondence:** Dr. Nagaveni NB

## 1 Introduction

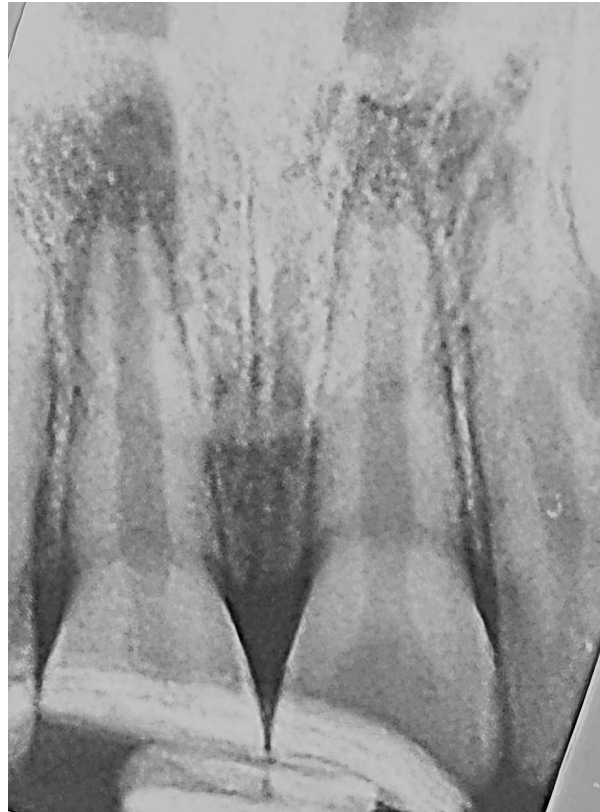Occurrence of dental trauma is more common in children and teenagers due to frequent fall and sport activities [1,2]. When dental trauma involves young permanent teeth, its management is a great challenge not only for a paediatric dentist but for all dental specialists [1-3]. Young permanent teeth exhibit wide pulp canal, wide open apex and thin dentin walls. Therefore, using conventional endodontic treatment comprising root canal treatment is not possible as it does not provide tight hermetic seal [4,5]. As a result, to obtain apical barrier formation, calcium hydroxide cement was introduced to overcome this issue, which successfully resulted in apical barrier formation [6]. However, calcium hydroxide exhibited various disadvantageous like loss of root dentinal fluid, long-term follow-up for barrier formation and brittleness leading to the fracture of the root on long term usage. To overcome the short comings of calcium hydroxide material Mineral Trioxide Aggregate Cement (MTA) was introduced in the endodontic field which provided immediate apical plug barrier so that immediate root canal treatment can be performed. However, MTA has also showed few disadvantages making it inappropriate in case of large apical opening cases [7]. The 'quest' went on and finally resulted in introduction of different alternative techniques [8-12]. However, the newly introduced alternatives requires increased cost, equipment and protocols. Therefore, to render immediate, cost-effective and appropriate justice to the patient, practitioner has to practice sometimes the well-established treatment protocol like calcium hydroxide apexification. The purpose of the current manuscript is to show

case successful formation of calcium hydroxide introduced apical barrier formation in a 10 year old Indian male patient following dental trauma.

## 2 Case report

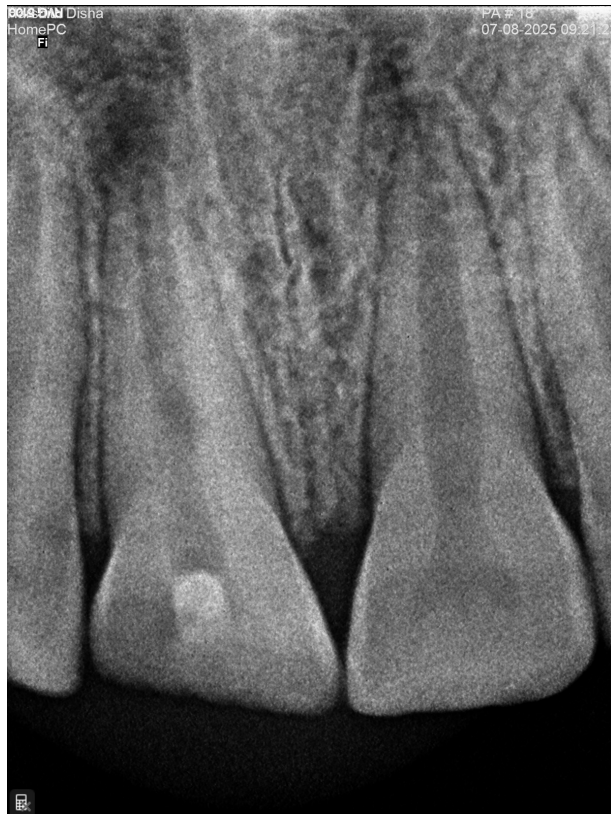A 10 year old male patient reported to the department of Pediatric and Preventive Dentistry complaining of pain in the upper front tooth since fifteen days. Patient was moderately built and well nourished. Patient reported a past history dental trauma due to fall one year back. Following clinical examination, Ellis' class IV fracture pertaining to permanent maxillary right central incisor was present. Tooth was discoloured and found tender to percussion test with absence of clinical gingival abscess. To rule out the condition of the root and apical region, patient was subjected to radiographic examination. On intraoral periapical radiograph (IOPA), incomplete root formation and wide open apex was noticed. There was periapical radiolucency measuring 1.5x1.5 mm size (Figure 1). Considering clinical and radiographic findings, a treatment plan consisting of calcium hydroxide apexification was planned.

In the first appointment, an access cavity was prepared with a straight line entry access into the root canal. Working length was determined within 1 mm of the radiographic apex. Following this, complete debridement of canal was done followed by thorough irrigation with normal saline. Later, canal was dried using paper points. Calcium hydroxide powder was mixed with normal saline and this mixture was placed into the canal and pushed to the short of apex using plugger. Finally, access opening was

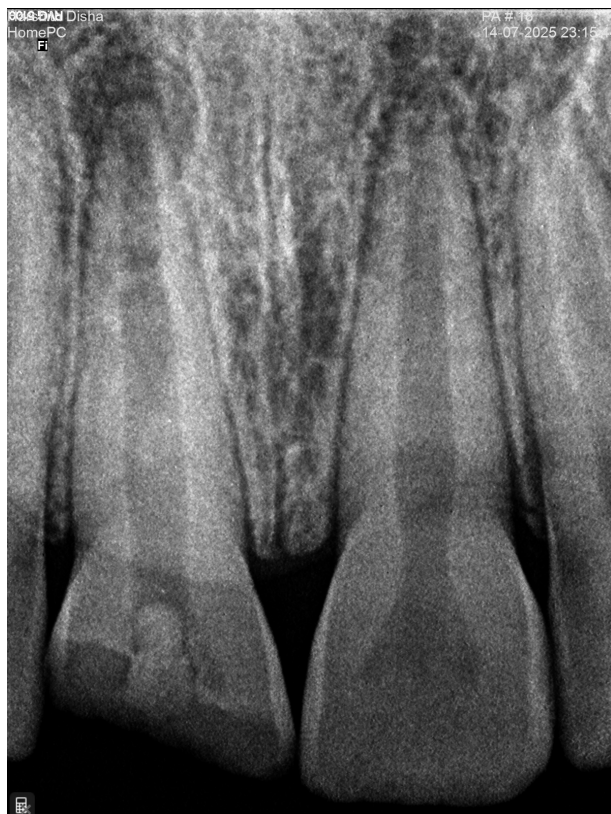

**Figure 1.** Permanent maxillary right central incisor with open apex and periapical radiolucency

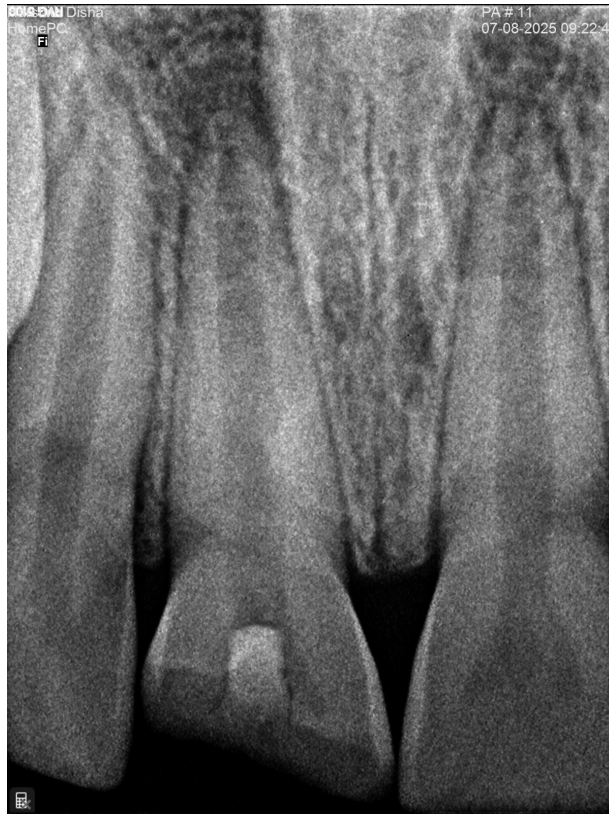closed using glass ionomer cement. Patient was followed up every 3 months once for a period of 9 months (Figures 2, 3 and 4). Following 9 months follow-up, radiographic examination was performed which showed complete formation of the root apex with complete periapical healing, absence of periapical radiolucency and with no clinical signs and symptoms (Figure 4). Presence of apical barrier formation was confirmed using a 30 size paper point which provided a resistant or stop and absence of haemorrhage, sensitivity and exudate. Patient was scheduled for further treatment.



**Figure 2.** 3 month post-operative radiograph of 11



**Figure 3.** 6 month post-operative radiograph of 11



**Figure 4.** 9 month post-operative radiograph showing apical barrier formation and periapical healing in 11.

### 3 Discussion

The completion of root development and closure of the root apex takes place till 3 years following eruption of the tooth. Dental traumatic injuries affect 30% of children and often result in pulpal inflammation and necrosis with subsequent incomplete development of dentinal wall and root apices. The treatment of pulpal injury during this period enables a significant challenge for all dental practitioners. The importance of careful case diagnosis and accurate pulpal treatment are very essential and should not be overemphasized. The standard/golden rule of the endodontic practice is to debride and obturate the root canals efficiently and three dimensionally as possible in an appropriate amount of time and appointments. Long back, the clinical management of the blunder buss canal usually consisted of surgical approach constituting apicectomy procedure for placement of an apical seal into the fragile, open and flaring apex. But, apicectomy technique further reduces the root length resulting in a very unfavourable crown root ratio. Therefore, the treatment of choice for necrotic young permanent teeth is apexification which involves induction of apical closure to produce more favourable conditions for conventional root canal treatment [1-4]. The most commonly suggested medicament of choice is calcium hydroxide. In 1964, Kaiser, a great pioneer and researcher was the one who proposed that this material mixed with camphorated parachlorophenol (CMCP) would stimulate the formation of a calcified barrier across the root apex [13].

Extensive review of pediatric endodontic literature exhibited numerous materials for apexification procedure comprising of calcium hydroxide in combination with sterile water, saline, local anesthetic, zinc oxide paste with cresol and iodoform, camphor-

ated parachlorophenol, tricalcium phosphate, chlorhexidene, cresatin and polyantibiotic paste. However, all these different materials have shown some promising results. Although recent novel techniques like use of MTA and regenerative endodontic procedures have been introduced calcium hydroxide still remains as a gold standard in management of open apex in immature permanent teeth [7-12]. Different factors which contribute to the success and wide acceptance of calcium hydroxide in the literature are its easy availability for clinician and affordability for patients and increased success rate [13].

The mechanism behind the barrier formation is associated with the alkalinity of non-setting calcium hydroxide which stimulates the formation of mineralized and fibrous tissue by the granulation tissue cells in the apical part of the root canal. It also acts as disinfectant and stimulates the physical barrier. Other postulated mechanisms of calcium hydroxide are presence of high calcium concentration which increases the activity of calcium dependent pyrophosphatase, direct effect on the apical and periapical soft-tissue, antibacterial activity and high pH, which may activate alkaline phosphatase activity. The final mineralized tissue formed consists of osteodentine, bone, osteocementum or sometimes combination of the three. The newly formed apical barrier prevents the passage of toxins and bacteria into periapical tissues from root canals. The calcific barrier formed can be either a complete or an incomplete hard tissue bridge at the root end or a few millimetres short of it. In case series reported by Nagaveni et al [6], the barrier was formed at the apex in both cases. In one case it appeared as a radiopaque line measuring 1 mm and in another case it was 2 mm thick. The calcific barrier formed is confirmed clinically by using a paper point inserting into the canal and felt for 'resistance' or 'stop' and there should be absence of intracanal

bleeding, exudate or absence of pain. The same procedure was followed in the present case too. In the case presented here calcific barrier was formed across the root apex. From previous report [6] and from the present case, it is evident that placement of calcium hydroxide inside the root canal is very important for apical barrier formation to be at the apex. If the cement is placed short of the apex, the barrier will form short of the apex. Therefore, proper working length determination is highly essential so that the cement can be easily placed exactly at the apex or slightly into periapical region. This procedure finally results in a proper barrier at the root apex not short of apex or with incomplete apex.

There are various opinions regarding the concentration and number of calcium hydroxide dressing for the apical barrier formation. A pioneer author based on his experiments suggested that the amount of calcium hydroxide in the single root canal dressing was sufficient to initiate and complete the barrier in 92% of the teeth [14]. Chosack et al [15] explained that repeated root filling is not required as CAOH is only required to initiate healing process. It has to be replaced if there are any symptoms or when dislodgment of the medicament happens. Nagaveni and co-authors reported two cases in that apical barrier formation happened following only single dressing change in one case. The frequency of CAOH dressing change is one among different variables which is under clinician's control and which has an effect on the speed of barrier formation. There are various studies showcasing that, when the frequency of change was low, rapid barrier formation was seen and there was also some studies where the frequency of dressing change was high, there was slow barrier formation [16-20]. Hence it is concluded that, if the root apex is disturbed by repeated instrumentation and dressing changes then the time required for apex formation prolongs. Therefore it was also suggested that a single dressing is sufficient to stimulate the apical barrier formation. Sheehy and Roberts suggested that use of calcium hydroxide for apical barrier formation was successful in 74-100% of cases and the average time for apical barrier formation was ranging from 5 months to 20 months [16]. The two cases reported by Nagaveni et al showed that the time required for apical barrier formation was 9 months to 2 years [6]. The present case strongly witness on successful closure of root apex in an immature non-vital permanent tooth using an age old, gold standard simple technology of CAOH assisted apexification. The apical barrier was formed after 7 months following calcium hydroxide apexification.

#### 4 Conclusion

Based on the present case report and from existing literature, it was concluded that calcium hydroxide medicament still remains a gold standard in inducing apical barrier formation in the management of necrotic, immature young permanent teeth. Although time required is long, it is easy to perform by a practitioner, cost-effective to the patients thereby providing successful results. However, long term clinical trials are essential to compare longevity of the tooth with other endodontic procedures dealing with wide open apex.

#### 5 References

1. Shashikiran ND, Reddy VV, Nagaveni NB. Knowledge and attitude of 2,000 parents (urban and rural – 1,000 each) with regard to avulsed permanent incisors and their emergency management, in and around Davangere. *J Indian Soc Pedod Prev Dent* 2006; 24(3): 116-21.
2. Nagaveni NB, Umashankara KV. Tooth fragment embedded in the lower lip for 10 months following dentoalveolar trauma: a case report with literature review. *Burns Trauma*. 2014; 28; 2(3): 141-5.
3. Nagaveni NB, Bajaj M, Lobo N, Poornima P. Treatment regime for crown fractures: autogenous tooth fragment reattachment – case reports. *Int J Dent Oral Health* 2015; 1 (6): 1-3.
4. Nandini R Katta, Poornima P, Shruthi A, Nagaveni NB. Traumatic avulsion management by allotransplantation. A rare case report with two years of successful follow-up. *Int J Med Dent Case Rep*. 2015; 2(1): 1-4.
5. Nagaveni NB, Poornima P, Bajaj M, Mathew MG, Soni AJ. Revascularization of a nonvital, immature permanent tooth using amniotic membrane: A novel approach. *Int J Clin Pediatr Dent*. 2019, 12(2): 150-152.
6. Nagaveni NB, Umashankara KV, Radhika NB, Manjunath S. Successful closure of the root apex in non-vital permanent incisors with wide open apices using single calcium hydroxide (caoh) dressing – report of 2 cases.
7. Shabahang S, Torabinejad M, Boyne PP, Abedi H, McMillan P. A comparative study of root-end induction using osteogenic protein-1, calcium hydroxide and mineral trioxide aggregate dogs. *J Endod* 1999; 25: 1-5.
8. Nagaveni NB, Poornima P, Mathew MG, Soni AJ, Khan MM. A comparative evaluation of revascularization done in traumatized immature, necrotic anterior teeth with and without platelet-rich fibrin: a case report. *Int J Clin Pediatr Dent*. 2020; 13(1): 98-102.
9. Nagaveni NB, Poornima P, Joshi JS, Pathak S, Nandini DB. Revascularization of immature, non-vital permanent tooth using platelet-rich fibrin in children. *Pediatr Dent* 2015; 37(1): 1-6.
10. Nagaveni NB, Pathak S, Poornima P, Joshi JS. Revascularization induced maturogenesis of non-vital immature permanent tooth using platelet-rich-fibrin. A case report. *J Clin Pediatr Dent*, 2016, 40(1): 26-30.
11. Nagaveni NB, Kumari KN, Poornima P, Reddy V. Management of an endo-perio lesion in an immature tooth using autologous platelet-rich fibrin: a case report. *J Indian Soc Pedod Prev Dent*. 2015; 33(1): 69-73.
12. Nagaveni NB, Praveen RB, Umashankar KV, Pranav B, Sreedevi R, Radhika NB. Efficacy of platelet-rich-plasma (PRP) in bone regeneration after cyst enucleation in pediatric patients – a clinical study. *J Clin Pediatr Dent*. 2010; 35(1): 81-7.
13. Kaiser H, editor. Management of wide open apex canals with calcium hydroxide. 21<sup>st</sup> annual meeting of the American Association of Endodontists: Washington DC. Apr, 1964.
14. Chawla HS. Apical closure in a non-vital permanent tooth using one Ca(OH)<sub>2</sub> dressing. *ASDC J Dent Child*. 1986; 53: 44-7.

15. Chosack A, Sela J, Cleaton-Jones P. A histological and quantitative histomorphometric study of apexification of nonvital permanent incisors of vervet monkeys after repeated root filling with a calcium hydroxide paste. *Endod Dent Traumatol.* 1997; 13: 211-7.
16. Sheehy EC, Roberts GJ. Use of calcium hydroxide for apical barrier formation and healing in non-vital immature permanent teeth: A review. *Br Dent J.* 1997; 183: 241-6.
17. Gawthaman M, Vnodh S, Mathian VM, Vijayaraghavan R, Karnakaran R. Apexification with calcium hydroxide and mineral trioxide aggregate: Report of two cases. *J Pharm Bioallied Sci* 2013; 5(Suppl 2): S131-S134.
18. Anantharaj A, Praveen P, Venkararaghavan K, Prathibha RS, Sudhir R, Murali Krishanan B. Challenges in pulpal treatment of young permanent teeth a review. *J Dent Scien Res* 2011; 2: 142.
19. Shikha D, Mukunda KS, Arun A, Rao SM. Apexification: A review. *J Dent Sci Res.* 2012; 3: 41-4.
20. Rafter M. Apexification: A review. *Dent Traumatol.* 2005; 21: 1-8.