IN THIS JOURNAL

Stain in Diagnosis of Tubercular

Clinical Improvement in a Patient

Place of Transcervical Amnioinfusion

Management of Preterm Prema Rupture

London Journals Press

www.journalspress.com

ISBN: 978-1-7340132-1-4

LONDON JOURNAL OF MEDICAL AND HEALTH RESEARCH

Volume 20 | Issue 1 | Compilation 1.0

© Copyright 2020 London Journals Press

COMPILED IN UNITED KINGDOM

ENGLISH

London
Journals Press

LONDON JOURNAL OF MEDICAL AND HEALTH RESEARCH

Volume 20 | Issue 1 | Compilation 1.0

PUBLISHER

London Journals Press
1210th, Waterside Dr,Opposite Arlington Building, Theale, Reading
Phone:+444 0118 965 4033 Pin: RG7-4TY United Kingdom

SUBSCRIPTION

Frequency: Quarterly

Print subscription
$280USD for 1 year
$500USD for 2 year
(color copies including taxes and international shipping with TSA approved)

Find more details at https://journalspress.com/journals/subscription

ENVIRONMENT

Copyright © 2020 by London Journals Press

All rights reserved. No part of this publication may be reproduced, distributed, or transmitted in any form or by any means, including photocopying, recording, or other electronic or mechanical methods, without the prior written permission of the publisher, except in the case of brief quotations embodied in critical reviews and certain other noncommercial uses permitted by copyright law. For permission requests, write to the publisher, addressed “Attention: Permissions Coordinator,” at the address below. London Journals Press holds all the content copyright of this issue. London Journals Press does not hold any responsibility for any thought or content published in this journal; they belong to author's research solely. Visit https://journalspress.com/journals/privacy-policy to know more about our policies.

London Journals Press Headquaters

1210th, Waterside Dr,
Opposite Arlington
Building, Theale, Reading
Phone:+444 0118 965 4033
Pin: RG7-4TY
United Kingdom

Reselling this copy is prohibited.
Available for purchase at www.journalspress.com for $50USD / £40GBP (tax and shipping included)

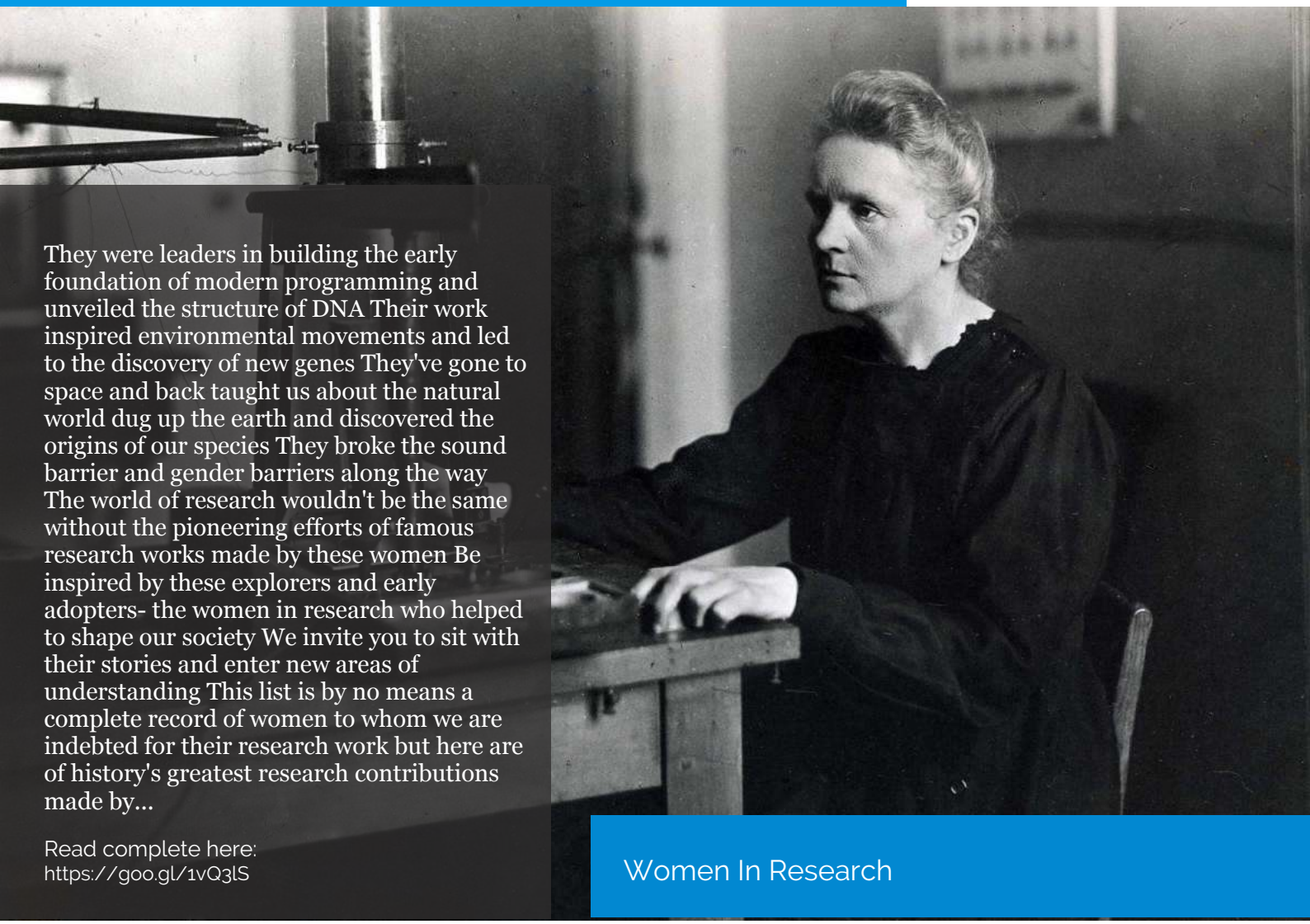

They were leaders in building the early foundation of modern programming and unveiled the structure of DNA Their work inspired environmental movements and led to the discovery of new genes They've gone to space and back taught us about the natural world dug up the earth and discovered the origins of our species They broke the sound barrier and gender barriers along the way The world of research wouldn't be the same without the pioneering efforts of famous research works made by these women Be inspired by these explorers and early adopters- the women in research who helped to shape our society We invite you to sit with their stories and enter new areas of understanding This list is by no means a complete record of women to whom we are indebted for their research work but here are of history's greatest research contributions made by...

Read complete here:
https://goo.gl/1vQ3lS

Women In Research

E-learning and the future of...

Education is one of the most important factors of poverty alleviation and economic growth in the...

Read complete here:
https://goo.gl/SQu3Yj

Writing great research...

Prepare yourself before you start Before you start writing your paper or you start reading other...

Read complete here:
https://goo.gl/np73jP

© 2020 London Journals Press

Journal Content
In this Issue

London Journals Press



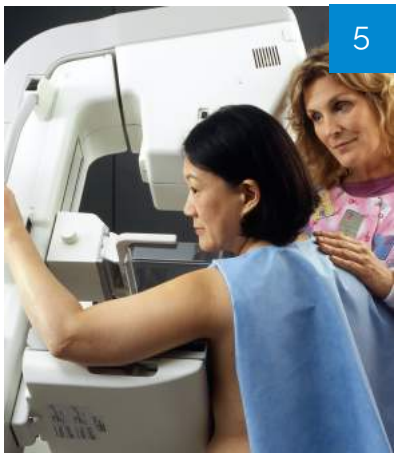



i. Journal introduction and copyrights

ii. Featured blogs and online content

iii. Journal content

iv. Editorial Board Members

1. Clinical Improvement in a Patient:... ***pg. 1- 4***

2. Ovarian Teratoma Fistulating to the Skin ***pg. 5-7***

3. Efficacy of Auramine-O Over ZN Stain in… ***pg. 9-16***

4. The Place of Transcervical Amnioinfusion... ***pg.17-24***

v. London Journals Press Memberships

© 2020 London Journals Press

Editorial Board

Curated board members

Dr. Robert Caldelli

CNIT - National Interuniversity Consortium for Telecommunications Research Unit at MICC Media Integration and Communication Center Ph.D., Telecommunications and Computer Science Engineering, University of Florence, Italy

Dr. Xiaoxun Sunx

Australian Council for Educational Research Ph.D., Computer Science University of Southern Queensland

Dariusz Jacek Jakóbczak

Department of Electronics and Computer Science, Koszalin University of Technology, Koszalin, Ph.D., Computer Science, Japanese Institute of Information Technology, Warsaw, Poland.

Dr. Yi Zhao

Harbin Institute of Technology Shenzhen Graduate School, China Ph.D., The Hong Kong Polytechnic University Hong Kong

Dr. Rafid Al-Khannak

Senior Lecturer Faculty of Design, Media and Management Department of Computing Ph.D Distributed Systems Buckinghamshire New University, United Kingdom

Prof. Piotr Kulczycki

Centre of Information Technology for Data Analysis Methods, Systems Research Institute, Polish Academy of Sciences, Faculty of Physics and Applied, Computer Science AGH University of Science and Technology, Poland

Dr. Shi Zhou

Senior Lecturer, Dept of Computer Science, Faculty of Engineering Science, Ph.D., Telecommunications Queen Mary, University, London

Prof. Liying Zheng

School of Computer Science and Technology, Professor for Computer Science, Ph.D., Control Theory and Control Engineering, Harbin Engineering University, China

Dr. Saad Subair

College of Computer and Information Sciences, Alazaeim Alazhari University, Khartoum North, Sudan, Associate Professor of Computer Science and Information Ph.D., Computer Science Bioinformatics, University of Technology Malasiya

Gerhard X Ritter

Emeritus Professor, Department of Mathematics, Dept. of Computer & Information, Science & Engineering Ph.D., University of Wisconsin-Madison, USA

Dr. Ikvinderpal Singh

Assistant Professor, P.G. Deptt. of Computer Science & Applications, Trai Shatabdi GGS Khalsa College, India

Prof. Sergey A. Lupin

National Research, University of Electronic Technology Ph.D., National Research University of Electronic Technology, Russia

Dr. Sharif H. Zein

School of Engineering, Faculty of Science and Engineering, University of Hull, UK Ph.D., Chemical Engineering Universiti Sains Malaysia, Malaysia

Prof. Hamdaoui Oualid

University of Annaba, Algeria Ph.D., Environmental Engineering, University of Annaba, University of Savoie, France

Prof. Wen Qin

Department of Mechanical Engineering, Research Associate, University of Saskatchewan, Canada Ph.D., Materials Science, Central South University, China

Luisa Molari

Professor of Structural Mechanics Architecture, University of Bologna, Department of Civil Engineering, Chemical, Environmental and Materials, PhD in Structural Mechanics, University of Bologna.

Prof. Chi-Min Shu

National Yunlin University of Science and Technology, Chinese Taipei Ph.D., Department of Chemical Engineering University of Missouri-Rolla (UMR) USA

Prof. Te-Hua Fang

Department of Mechanical Engineering, National Kaohsiung University of Applied Sciences, Chinese Taipei Ph.D., Department of Mechanical Engineering, National Cheng Kung University, Chinese Taipei

Dr. Fawad Inam

Faculty of Engineering and Environment,
Director of Mechanical Engineering,
Northumbria University, Newcastle upon Tyne,
UK, Ph.D., Queen Mary, University of London,
London, UK

Dr. Rocío Maceiras

Associate Professor for Integrated Science,
Defense University Center, Spain Ph.D., Chemical
Engineering, University of Vigo, SPAIN

Muhammad Hassan Raza

Postdoctoral Fellow, Department of Engineering
Mathematics and Internetworking,
Ph.D. in Internetworking Engineering,
Dalhousie University, Halifax Nova Scotia,
Canada

Rolando Salgado Estrada

Assistant Professor,
Faculty of Engineering, Campus of Veracruz,
Civil Engineering Department, Ph D.,
Degree, University of Minho, Portugal

Abbas Moustafa

Department of Civil Engineering,
Associate Professor, Minia University, Egypt, Ph.D
Earthquake Engineering and Structural Safety,
Indian Institute of Science

Dr. Babar shah

Ph.D., Wireless and Mobile Networks,
Department of Informatics,
Gyeongsang National University,
South Korea

Dr. Wael Salah

Faculty of Engineering,
Multimedia University Jalan Multimedia,
Cyberjaya, Selangor, Malaysia, Ph.D, Electrical and
Electronic Engineering, Power Electronics
and Devices, University Sians Malaysia

Prof. Baoping Cai

Associate Professor,
China University of Petroleum,
Ph.D Mechanical and Electronic Engineering,
China

Prof. Zengchang Qin

Beijing University of Aeronautics
and Astronautics Ph.D.,
University of Bristol,
United Kingdom

Dr. Manolis Vavalis

University of Thessaly,
Associate Professor, Ph.D.,
Numerical Analysis,
University of Thessaloniki, Greece

Dr. Mohammad Reza Shadnam

Canadian Scientific Research and Experimental Development Manager-Science,
KPMG LLP, Canada, Ph.D., Nanotechnology,
University of Alberta, Canada

Dr. Gang Wang

HeFei University of Technology,
HeFei, China, Ph.D.,
FuDan University, China

Kao-Shing Hwang

Electrical Engineering Dept.,
Nationalsun-Yat-sen University Ph.D.,
Electrical Engineering and Computer Science,
Taiwan

Mu-Chun Su

Electronics Engineering,
National Chiao Tung University, Taiwan,
Ph.D. Degrees in Electrical Engineering,
University of Maryland, College Park

Zoran Gajic

Department of Electrical Engineering,
Rutgers University, New Jersey, USA
Ph.D. Degrees Control Systems,
Rutgers University, United States

Dr. Homero Toral Cruz

Telecommunications,
University of Quintana Roo, Ph.D.,
Telecommunications Center for Research and Advanced Studies National Polytechnic Institute, Mexico

Nagy I. Elkalashy

Electrical Engineering Department,
Faculty of Engineering,
Minoufiya University, Egypt

Vitoantonio Bevilacqua

Department of Electrical and Information Engineering Ph.D., Electrical Engineering
Polytechnic of Bari, Italy

Dr. Sudarshan R. Nelatury

Pennsylvania State University USA Ph.D., Signal Processing Department of Electronics and Communications Engineering,
Osmania University, India

Prof. Qingjun Liu

Professor, Zhejiang University, Ph.D.,
Biomedical Engineering,
Zhejiang University, China

Sanjukta Pookulangara

College of Merchandising,
Hospitality and Tourism,
University of North Texas, USA Ph.D, Fashion
Merchandising, University of Missouri Columbia

Prof. Yaohua Zhu

Hong Kong Polytechnic University,
China, PhD. Applied Science and Engineering,
Metallurgy and Materials,
Aston University, UK

Jeng-Da Chai

Associate Professor, Department of Physics,
National Taiwan University,
Excellent Junior Research Investigators,
Ministry of Science and Technology,
Career Development Award,
National Taiwan University

Prof. Peter K. Law

Huazhong University of Science and Technology,
Ph.D., University of Toronto B.Sc.,
McGILL University

Yas Al-Sultani

Ph.D. Image processing Enhancement
using Fuzzy Set Theory Arabian Gulf University,
Constituencies, Training and Continuous
Teaching Center, Iraq

Prof. Dimitrios A. Papaconstantopoulos

School of Physics, Astronomy, and Computational
Sciences, George Mason University, USA
Ph.D., Theoretical Solid State Physics
University of London(UK)

Dr. Abdelkader Zarrouk

Faculty of Sciences, Dept. of Chemistry
Laboratory Applied Chemistry and Environment
Mohammed First University Ph.D.,
Mohammed First Unversity Oujda, Morocco

Prof. Tai-Yin Huang

Associate Professor of Physics , Pennsylvania
State University, Penn State Lehigh Valley,
Ph.D., Physics, University of Cincinnati,
President of the Lehigh Valley,
Taiwanese Women Association

Prof. Dr. Ahmed Asaad Ibrahim Khalil

National Institute for Laser Enhanced Sciences,
NILES Cairo University, Giza, Egypt Ph.D.,
Experimental Physics V Institute
Engineering Application of Lasers
University Bochum, Germany

Dr. Mohamed Salem Badawi

Department of Physics,
Awarded Junior Radiation Physics Medal,
7th Radiation Physics and Protection
Conference, Ismailia, Egypt

Prof. Marie-Christine Record

Department of Chemistry,
Aix-Marseille University Ph.D.,
Materials Sciences, Montpellier University,
France

Prof. Hakan Arslan

Mersin University Ph.D.,
Chemistry Nigde University
Turkey

Prof. Wanyang Dai

Department of Mathematics,
Nanjing University, China
Ph.D., Applied Mathematics,
Georgia Institute of Technology, USA

Dr. Hyongki Lee

Assistant Professor,
University of Houston
Ph.D. in Geodetic Science,
Ohio State University, USA

Nicola Mastronardi

Consiglio Nazionale delle Ricerche,
Ph.D. Applied Mathematics Katholieke
Universiteit Leuven
Belgium

Prof. Saad Belkhiat

Setif University, Ph.D., Physics
University of Sétif
Algeria

Dr. Arvind Chhabra

University of Connecticut Health Center
USA Ph.D., Biotechnology Central
Drug Research Institute

Mohamed Shaaban Ali

Department of Anaesthetics,
Al Salam International Hospital,
The State of Kuwait PhD,
Cerebral Monitoring during cardiac surgery,
University of Wales, Cardiff, UK

Prof. Tarek Aboul-Fadl Mohammad Hassan

Vice Dean for Education and Student Affairs,
Department of Medicinal Chemistry,
Faculty of Pharmacy, Assiut University

Prof. Anthony Bridgwater

European Bioenergy Research Institute,
Director of EBRI, Leader of Aston University
Bioenergy Research Group,
Edwin Walker Prize winner

Prof. Ewa Szczepanska-Sadowska

Medical University of Warsaw,
Poland Ph.D., Medical University of Warsaw,
Poland

Prof. Gjumrakch Aliev

University of Atlanta, Ph.D.,
Cardiovascular Biology and Pathology,
Moscow State University

Prof. Elsayed Ibrahim ELAGAMY

Department of Applied Medical Sciences,
Qassim University, Kingdom of Saudi Arabia,
Ph.D., Dept. of Comparative Medicine,
Mc Gill University

Shen Hu

Division of Oral Biology and Medicine,
Jonsson Comprehensive Cancer Center,
University of California, Ph.D.,
Bioanalytical Chemistry, Wuhan University,
China

Rahul Mahavir Nandre

College of Veterinary Medicine,
Kansas State University, Kansas, USA Ph.D.,
Veterinary Medicine Chonbuk National University,
South Korea

A. C. Matin

Department of Microbiology and Immunology,
Stanford University School of Medicine Stanford,
California Ph.D., Microbiology,
University of California, Los Angeles

Wei Wang

Professor, Public Health School of
Medical Sciences, Ph.D., Edith Cowan University,
Australia

Prof. Filippo Berto

Department of Management and Engineering,
University of Padua, Italy
PH.D, University of Florence

Prof. Bernardino Benito

Department of Accounting and Finance,
Faculty of Economics and Business,
Ph.D. in Economics and Business,
University of Murcia, SPAIN

Dr. Dimitrios Vortelinos

Department of Accounting,
Economics and Finance, University of Lincoln,
UK Ph.D., Financial Economics,
University of Peloponnese, Greece

Victor J. Tremblay

Department of Economics,
Oregon State University Ph.D.,
Economics Washington State University

Dr. Emmily Mugasia

Department of Education planning and
Management, Masinde Muliro University of Science
and Technology Kakamega – Kenya.

Dr. Randall Xu

School of Business,
Accounting Department University of Houston
-Clear Lake Ph.D. Accounting University of Alabama

Prof. Bartlomiej Kaminski

Information Technology and Management Rzeszow
University Poland Ph.D., Department of Economics
University of Warsaw, Poland

Prof. Ubaldo Comite

University of Calabria,
Arcavacata – Rende,
Italy University Giustino Fortunato,
Benevento – Italy Ph.D.,
Economy and Management
of Public Administrations

Prof. Birendra (Barry) Mishra

Professor of Accounting
A. Gary Anderson Graduate School of Management
University of California, Riverside,
USA Ph.D., Accounting University of Texas, Austin

Xuebing Yang

Assistant Professor,
Economics Penn State Altoona Ph.D.,
University of Oklahoma USA

Prof. Robin H. Luo

Professor of Finance ALHOSN University, UAE
Adjunct DBA Faculty Doctoral Supervisor
University of Liverpool/Laureate, UK Ph.D.,
Nanyang Technological University
Singapore

Omonijo Ojo

Student Industrial Work Experience
Scheme Covenant University, Ota,
Ogun-State Obafemi Awolowo
University Sociology of Development Covenant
University, University Ota, Nigeria

Dr. Haijing Dai

Assistant Professor Chinese University of
Hong Kong Department of Social Work Doctor of
Philosophy Social Work and Sociology University of
Michigan, Ann Arbor

Prof. Yung C. Shin

Purdue University,
USA Ph.D.,
University of Wisconsin, USA

Dr. Xiaochun Cheng

Middlesex University,
UK Ph.D.,
Jilin University China

Prof. Tatiana Kovacikova

COST Office Belgium Ph.D.,
University of Zilina
Slovakia

Dr. José Reinaldo Silva

University of São Paulo Ph.D.,
University of São Paulo
Brazil

Prof. Chang-Hwan Lee

Dong Guk University,
South Korea Ph.D.,
University of Connecticut USA

Prof. Qiuqi Ruan

Beijing Jiaotong University B.S.,
Northern Jiaotong University Beijing

Prof. Victor J. Tremblay

Oregon State University Ph.D.,
Washington State University,
University of California
USA

Prof. Vassili Kolokoltsov

University of Warwick,
UK Ph.D., Moscow State University,
Russia

Scan to know paper details and
author's profile

Clinical Improvement in a Patient with Parkinson's Disease and Vascular Dementia Receiving PCSK9 Inhibitor for Ischemic Heart Disease: A Case Report

Alexander M. Swan, Hein Linn Thant, .Chit Pyone Myet Chai, Htet Htet Khaing,
Min Zaw Thein, Yadanar Win Lei & Moe Thuzar
University of Medicine, Yangon, Myanmar

ABSTRACT

Dementia is a disorder that is characterized by a decline in one or more of the cognitive functions (learning and memory, language, executive functions, attention, motor and social abilities). [5]The dysfunctions are usually severe enough to interfere with the patient's daily activities and independence. The main under-lying cause of vascular dementia is cerebrovascular disease or insufficient cerebral microvascular circulation. [7] The vascular dementia should be treated for vascular risk factors, especially hypertension, diabetes, hypercholesterolemia, smoking and inactivity.[8], [9]. The standard pharmacological interventions are Acetylcholinesterase inhibitors (donepezil, galantamine) and N-Methyl- D-aspartate receptor antagonists (Memantine). However, recovery of lost cognitive function beyond the initial recovery from vascular dementia is not likely. Moreover, Parkinson disease is another common neurological disease, caused by loss of dopaminergic neurons of substantia nigra pars compacta. The primary treatments are anticholinergics (benztropine, trihexyphenidyl), dopamine precursors (levodopa, carvidopa), COMT inhibitors (Entacapone), MAO B inhibitor (Selegiline), and Amantadine. Above treatments can slow down the disease progression but they cannot reverse the disease course. Here we are reporting a patient with dementia and parkinson's disease who was significantly improved by adminis- tration of PCSK9 inhibitor.

Keywords: vascular dementia, parkinson, pcsk9 inhibitor, microvascular circulation.

Classification: NLMC Code: WG 200, WL 359

Language: English

London Journals Press

LJP Copyright ID: 392861

London Journal of Medical and Health Research

Volume 20 | Issue 1 | Compilation 1.0

© 2020. Alexander M. Swan, Hein Linn Thant, .Chit Pyone Myet Chai, Htet Htet Khaing' Min Zaw Thein, Yadanar Win Lei & Moe Thuzar. This is a research/review paper, distributed under the terms of the Creative Commons Attribution-Noncom-mercial 4.0 Unported License http://creativecommons.org/licenses/by-nc/4.0/), permitting all noncommercial use, distribution, and reproduction in any medium, provided the original work is properly cited.

Clinical Improvement in a Patient with Parkinson's Disease and Vascular Dementia Receiving PCSK9 Inhibitor for Ischemic Heart Disease: A Case Report

Alexander M. Swan[α], Hein Linn Thant[σ], Chit Pyone Myet Chai[ρ], Htet Htet Khaing[Ø] Min Zaw Thein[¥], Yadanar Win Lei[§] & Moe Thuzar[χ]

ABSTRACT

Dementia is a disorder that is characterized by a decline in one or more of the cognitive functions (learning and memory, language, executive functions, attention, motor and social abilities). [5]The dysfunctions are usually severe enough to interfere with the patient's daily activities and independence. The main under-lying cause of vascular dementia is cerebrovascular disease or insufficient cerebral microvascular circulation. [7] The vascular dementia should be treated for vascular risk factors, especially hypertension, diabetes, hypercholesterolemia, smoking and inactivity.[8], [9]. The standard pharmacological interventions are Acetylcholinesterase inhibitors (donepezil, galantamine) and N-Methyl-D-aspartate receptor antagonists (Memantine). However, recovery of lost cognitive function beyond the initial recovery from vascular dementia is not likely. Moreover, Parkinson disease is another common neurological disease, caused by loss of dopaminergic neurons of substantia nigra pars compacta. The primary treatments are anticholinergics (benztropine, trihexyphenidyl), dopamine precursors (levodopa, carvidopa), COMT inhibitors (Entacapone), MAO B inhibitor (Selegiline), and Amantadine. Above treatments can slow down the disease progression but they cannot reverse the disease course. Here we are reporting a patient with dementia and parkinson's disease who was significantly improved by administration of PCSK9 inhibitor.

Keywords: vascular dementia, parkinson, pcsk9 inhibitor, microvascular circulation.

Author α: AOA Prof of Medicine, Rutgers New Jersey Medical School, 185 S Orange Ave, Newark, NJ 07103. MD, FACP Department of Medicine Rutgers New Jersey Medical School/ Nephrology Hypertension Renal Transplant & Renal Therapy,LLC. 1030 St. Georges Ave, Suite LL-1, Avenel, NJ 07001,USA.
α: President, Garden State Kidney Center, 345 Main Street, Woodbridge, NJ 07095.
σρ¥§χ: Clinical Researcher, Nephrology Hypertension Renal transplant and Renal Therapy, LLC 1030 St. Georges Avenue, Suite: Lower Level-1, Avenel, NJ 07001
σ Ø: University of Medicine 2, Yangon, Myanmar
σ ρ ¥ §: University of Medicine 1, Yangon, Myanmar

I. INTRODUCTION

Total number of people with dementia worldwide in 2015 is estimated at 47 million. Total number of new cases of dementia each year worldwide is nearly 9.9 millions, implying 1 new case every 3 seconds.[2] Vascular dementia is the second most common form of dementia after Alzheimer's Disease(AD)[6].In 1969, Mayer-Gross et al described this syndrome and reported that hypertension is the cause in approximately 50% of patients.[6] Patients with stroke are at increased risk for vascular dementia.[6] The prevalence rate of dementia is 9 times higher in patients with stroke than in controls[10]. One year after a stroke, 25% of patients develop newonset dementia. [10] Within 4 years following a stroke,

© 2020 London Journals Press

the relative risk of dementia incident is 5.5%. The prevalence of vascular dementia is higher in men than in women.[10].Approximately 60,000 Americans are diagnosed with Parkinson's disease each year, and this number does not reflect the thousands of cases that go undetected.[3] An estimated 7 to 10 million people worldwide are living with Parkinson's disease.[3] Parkinson's disease affects nerve cells in the brain that produce dopamine. Parkinson's disease symptoms include muscle rigidity, tremors and changes in speech and gait. Loss of pigmented dopaminergic neurons of the substantia nigra pars compacta and presence of lewy bodies. By means of improving cerebral vascular supply with PCSK9 inhibitor, the loss of dopaminergic neurons and memory function can be restored .

II. CASE REPORT

88 years old Female presented with 3 months onset of dementia and 6 months duration of parkinsonism features. Her Past medical history was significant for long standing uncontrolled Hypertension diabetes Mellitus with compli-cations, hypercholesterolemia, hypertrigly ceridemia, anxiety disorder, ischemic heart disease, transient ischemic attack, osteoporosis and peripheral vascular disease. She also complained of having essential tremors for years . Medication listincluded Valsartan, oxalate, Digoxin, Hydrochlorothiazide, Aspirin, Omeprazole, Benazepril, Rosuvastatin calcium, Denosumab, Amlodipine besylate, Ticagrelor, Olopatadine, Bupropion, Evolocumab, Hydroxyc hloroquine, Strovite , Carvedilol, Colesevelam hydrochloride, Isosorbide, Doxercalciferol and Sucralfate.

Then, she started getting PCSK9 inhibitor injection.

Before treatment, her total cholesterol level was 189 mg/dl, HDL 61 mg/dl, LDL 101 mg/dl. Post treatment cholesterol was 134 mg/dl, HDL 76 mg/dl, LDL 45 mg/dl respectively.

After 3 months of PCSK9 inhibitor therapy, her Minimental state examination (MMSE) scoresubsequently increased and her dementia stage declined from stage 3 to stage 1 according to Global Deterioration Scale for Assessment of Primary Degenerative Dementia (GDS).

III. GLOBAL DETERIORATION SCALE FOR ASSESSMENT OF PRIMARY DEGENERATIVE DEMENTIA (GDS).[1]

The most common scale is often referred to simply as GDS or by its more formal name theReisberg Scale. The GDS divides the disease process into seven stages based on the amount of cognitive decline. This test is most relevant for people who have Alzheimer's disease, since some other types of dementia (i.e, frontotemporal dementia) do not always include memory loss.

Diagnosis	Stage	Signs and Symptoms
No dementia	Stage 1: No Cognitive Decline	In this stage the person functions normally, has no memory loss and is mentally healthy.People with No dementia would be considered to be in stage 1.
No dementia	Stage 2: Very Mild Cognitive Decline	This stage is used to describe normal forgetfulness associated with aging; for example, forgetfulness of names and where familiar objects were left. Symptoms are not evident to loved ones or the physician.
No dementia	Stage 3: Mild Cognitive Decline	This stage includes increased forgetfulness, slight difficulty concentrating, decreased work performance. People may get lost more often or have difficulty finding the right words. At this stage, a person's loved ones will begin to notice a cognitive decline. Average duration: 7 years before onset of dementia.

© 2020 London Journals Press

Early stage	Stage 4: Moderate Cognitive Decline	This stage includes difficulty concentrating, decreased memory of recent events and difficulties managing finances or traveling alone to new locations. People have trouble completing complex tasks efficiently or accurately and may be denial about their symptoms. They may also start withdrawing from family or friends because socialization becomes difficult.At this stage a physician can detect clear cognitive problems during a patient interview and exam.Average duration: 2 years
Mid stage	Stage 5: Moderately Severe Cognitive Decline	People in this stage have major memory deficiencies and need some assistance to complete their daily activities (dressing,bathing,preparing meals).Memory loss is more prominent and may include major relevant aspects of current lives; for example, people may not remember their address or phone number and may not know the time or day or where they are. Average duration : 1.5 years
Mid stage	Stage 6: Severe Cognitive Decline (Middle Dementia)	People in stage 6 require extensive assistance to carry out daily activities. They start to forget names of close family members and have little memory of recent events. Many people can remember only some details of earlier life. They also have difficulty counting down from 10 and finishing tasks. Incontinence (loss of bladder or bowel control) is a problem in this stage.Ability to speak declines. Personality changes such as delusions (believing something to be true that is not), compulsions (repeating a simple behavior such as cleaning) or anxiety and agitation may occur. Average duration: 2.5 years
Late stage	Stage 7: Very	People in this stage have essentially no ability to speak or
	Severe	communicate. They require assistance with most activities
	Cognitive	(e.g using the toilet, eating). They often lose psychomotor
	Decline (Late	skills, for example, the ability to walk. Average duration: 2.5
	Dementia)	years

IV. DISCUSSION AND CONCLUSION

In patients with vascular risk factors, there is an inadequate cerebral circulation in microvascular level from high cholesterol. The impaired circulation can lead to damaging of nerve cells which can result or worsen dementia and parkinsonism.

Currently available treatments can slow down the disease progression but they can not reverse the disease course.Numerous new treatments are being investigated in various stages of clinical trials. However much can be offered to support and improve the lives of people with dementia, their careers and families.

PCSK9 inhibitor is a human monoclonal IgG2 directed against Human Proprotein Convertase Subtilisin Kexin 9 (PCSK9). [4]It binds to PCSK9 and inhibits circulating PCSK9 from binding to low-density lipoprotein (LDL) recept or (LDLR), preventing PCSK9-mediated LDLR degradation and permitting LDLR to recycle back to the liver cell surface.[4] Thereby, it increases the number of LDLRs available to clear LDL from the blood, and lowers LDL-C levels to reduce the risk of myocardial infarction, stroke and improve coronary and cerebral revascularization in adults with stablished cardiovascular disease[4]

Evaluation of this patient shows that she had impaired microvascular circulation resulting from hypercholesterolemia, Peripheral vascular disease, DM and hypertension which could damage the neuronal cells.

© 2020 London Journals Press

PCSK 9 inhibitor is a game changer in management of hypercholesterolemia which can effectively lower LDL level. Lowering of LDL level can have a beneficial effect in microvascular circulation resulting in revascularization. The improvement of signs and symptoms of Parkinsonism and dementia was assumed to be from restoration of blood supply to dopaminergic neurons and memory neuronal cells by PCSK 9 inhibitor therapy.

ABBREVIATIONS

NMDA: N- Methyl- D- aspartic acid or N-Methyl-D-aspartate; HCTZ: Hydrochloro thiazide; LDL: low density lipoprotein; HDL: high density lipoprotein; MMSE; mini mental state examination; COMT: catechol- O-methyltransferase.

REFERENCE

1. Reisberg, B., Ferris, S.H., de Leon, M.J., and Crook, T. (1982). The Global Deterioration Scale for assessment of primary degenerative dementia. *American Journal of Psychiatry*, 139(9), pp.1136-1139.
2. World Health Organization. (2017). *10 facts on dementia*. [online] Available at:http://www.who.int/features/factfiles/dementia/en/
3. Parkinson association of Carolina, Statistics on Parkinson's disease https://www.Parkinsonassociation. org/facts-about parkinsons-disease/
4. Pi.amgen.com.[online] Available at: https://www.pi.amgen.com/~/media/amgen/repositorysites/pi-amgen-com/repatha/repatha_pi_hc p_english. pdf
5. Wright, C., DeKosky, S., Kasner, S. and Wilterdink, J. *Up To Date*. [online] Uptodate. com. Available at:https://www. uptodate.com/contents/ treatment-and-preve ntion-of-vasculardementia?search=vascular% 20dementia&source=searc_result&selectedTit le=2~58&usage_type=default&display_rank= 2
6. Alagiakrishnan, K., Xiong, G., Talavera, F., Memon, M. and Masaki, K.*Vascular dementia*.[online] Medscape. Available at: https://emedicine.medscape.com/article/292-105-overview.
7. Smith EE. Clinical presentations and epidemio- logy of vascular dementia. Clin Sci (Lond) 2017; 131:1059.
8. Dichgans, M. and Zietemann, V. (2012). Preven- tion of Vascular Cognitive Impairment. *Stroke*, 43(11), pp.3137-3146.
9. Douiri A, McKevitt C, Emmett ES, et al. Long-term effects of secondary prevention on cognitive function in stroke patients. Circulation 2013: 128:1341.
10. Alagiakrishnan, K., Talavera, F., Xiong, G., Memon, M. and Masaki, K. Vascular Dementia: Background, Pathophysiology, Epidemiology. [online] Emedicine.

© 2020 London Journals Press

Scan to know paper details and
author's profile

Ovarian Teratoma Fistulating to the Skin

Rahantasoa Finaritra CFP, Rakotomena SD, Mosa F, Randrianarijon H, Samison LH & Rakoto Ratsimba HN

ABSTRACT

Introduction: Mature ovarian teratoma is a benign tumor of the ovary derived from pluripotent germ cells. It can be complicated by infection following rupture of its membrane in the peritoneal cavity or fistulation. The objective of our study is to discuss the diagnostic means as well as the surgery of a dermoid cyst of the ovary.

Observation: The patient had undergone appendectomy in 2001. Two subumbilical fistulous orifices had appeared on the scar with nauseous yellowish liquid. The diagnosis of fistulized dermoid cyst was made intraoperatively during the exploratory laparotomy. The evolution was favorable, with a simple operative follow-up.

Conclusion: The diagnosis is histological. A conservative treatment is recommended knowing that the haunting remains a degeneration in women who are already menopausal.

Keywords: complications; ovary; teratoma.

Classification: NLMC Code: WJ 500

Language: English

London Journals Press

LJP Copyright ID: 392862

London Journal of Medical and Health Research

Volume 20 | Issue 1 | Compilation 1.0

© 2020. Rahantasoa Finaritra CFP, Rakotomena Sd, Mosa F, Randrianarijon H, Samison Lh& Rakoto Ratsimba Hn. This is a research/review paper, distributed under the terms of the Creative Commons Attribution-Noncom-mercial 4.0 Unported License http://creativecommons.org/licenses/by-nc/4.0/), permitting all noncommercial use, distribution, and reproduction in any medium, provided the original work is properly cited.

Ovarian Teratoma Fistulating to the Skin

Rahantasoa Finaritra CFP[α], Rakotomena SD[σ], Mosa F[ρ], Randrianarijon H[Ø], Samison LH[¥] & Rakoto Ratsimba HN[§]

ABSTRACT

Introduction: Mature ovarian teratoma is a benign tumor of the ovary derived from pluripotent germ cells. It can be complicated by infection following rupture of its membrane in the peritoneal cavity or fistulation. The objective of our study is to discuss the diagnostic means as well as the surgery of a dermoid cyst of the ovary.

Observation: The patient had undergone appendectomy in 2001. Two subumbilical fistulous orifices had appeared on the scar with nauseous yellowish liquid. The diagnosis of fistulized dermoid cyst was made intraoperatively during the exploratory laparotomy. The evolution was favorable, with a simple operative follow-up.

Conclusion: The diagnosis is histological. A conservative treatment is recommended knowing that the haunting remains a degeneration in women who are already menopausal.

Keywords: complications; ovary; teratoma.

I. BACKGROUND

Mature ovarian teratoma is a benign tumor of the ovary derived from pluripotent germ cells. However, some aspects of its pathology, classification and management remain unclear. Also known as dermoid cyst, it accounts for 10-20% of all ovarian tumors [1]. The localisation is bilateral in 10% of cases. Infection may be complicated by rupture of the membrane in the peritoneal cavity [2]. Our case reports a right ovarian teratoma infiltrating the left ovary and fistulating. The aim of our observation is to discuss the diagnostic means and surgery for a dermoid cyst of the ovary.

II. OBSERVATION

A 45-year-old woman had had a fistulized abscess in her abdomen. Her gynecological and obstetrical history was marked by repeated dysmenorrhea since her menarche, six pregnancies including one that was terminated with intrauterine curettage in 2001. The patient had an appendectomy in 2001. Her menopause occurred in 2011. Two sub umbilical fistulous orifices had appeared on the scar with an inexhaustible foul-smelling yellowish liquid. His general state was preserved, without fever. The hemoglobin level was 12g/dL and the leucocyte level 4G/L. The rest of the tests also showed no particularity. Ultrasonography showed an intraperitoneal fluid collection communicating to the skin through the abdominal wall. The open midline laparotomy confirmed the continuity of the fistula with the abdominal wall. The right ovary had presented a recent ovarian mass with pasty contents and embryonic remnants (hair, teeth). The mass measured 10 X 10 cm. It adhered strongly to the rectus and to the bladder. The left ovary had also fistulized to the right ovary.

A bilateral adnexectomy was performed. The cyst was ruptured at the time of dissection but without dissemination of its contents into the peritoneum. No digestive wound was found. A drain was put in place and maintained for two days. Immediately after the operation, the patient was transferred to the ward. She had benefited from biantibiotherapy for seven days. The transit had resumed on D2 postoperatively. The postoperative rehabilitation was early. The evolution was favorable with complete healing after ten days.

© 2020 London Journals Press

Image 1: Intraoperative image showing fistula trajectory at the expense of dermoid cyst
Source: Department of Visceral Surgery,Joseph Ravoahangy Andrianavalona University Hospital Center,Antananarivo,Madagascer

III. DISCUSSION

Our patient was 45 years old. In the literature the peak age is between 20 and 30. Although it is a germinal tumor arising from remnant embryonic tissue, it can be observed at any age. This is due to its nature that can be silent for a long time [1]. There is a right predominance of unilateral forms, and the cyst is bilateral in 10% of cases. Our patient had presented a right ovarian teratoma fistulating on the left ovary [3, 4]. Spontaneous rupture is the second most frequent complication in 0.3 to 2% of cases. It may be iatrogenic following puncture or ovarian cystectomy [2,3]. The main risk of a ruptured dermoid cyst is the development of chemical peritonitis by releasing deposits of neutral fat, fatty acid crystals, cholesterol, and epidermal cells in the abdomen. In reported cases, the clinical signs may also be a pelvic mass syndrome, a chronic pelvic pain [1].

Abdominal ultrasound is the first diagnosis examination of ovarian teratoma. Abdominal pelvic CT scan may reveal a cystic, fluid-dense process with rounded calcifications and irregular thickened wall [5]. Only histological examination can confirm the germinal nature of the tumor, as well as confirm its benign nature or the degeneration of the teratoma. In our observation, abdominal ultrasonography objectified an intraperitoneal fluid collection with a fistulous path to the skin.

Laparoscopic ovarian cystectomy remains the standard gold standard in the treatment of benign cysts of the unruptured ovary. Our case was an already fistulated teratoma adhering strongly to the wall. A laparotomy was necessary to reduce the risk of viscerolysis [6]. Cystectomy makes it possible to preserve as much as possible of the capital of primordial follicles for women of childbearing age. However, in postmenopausal women, adnexectomy is recommended to reduce the risk of iatrogenic rupture of the cyst and to prevent a lesser risk of ovarian teratoma degeneration. Laparoscopy is increasingly preferred in developed countries for the resection of dermoid cysts [7]. This technique is less

© 2020 London Journals Press

invasive and preserves the integrity of the ovarian tissue by being less aggressive, but nevertheless presents a greater risk of rupture of the cyst [6]. Laparoscopic conservative approach to borderline ovarian tumors remains a potentially safe alternative for young women who wish to preserve their potential of procreation. The recurrence rate after pregnancy is not influenced by this approach [7]. The fistula trajectory in our clinical case had favored adhesions, which motivated the surgeon to perform open surgery from the outset. In the case of an intraoperative rupture like ours, it is recommended to perform a lavage with warm saline solution of the peritoneal cavity to avoid the secondary occurrence of chemical peritonitis. This procedure minimizes this risk to less than 1%.

A systematic check of the contralateral ovary intraoperatively as well as a postoperative pelvic ultrasound scan allows the condition of both ovaries to be assessed later to detect any impact on the fertility of young women.

While mature teratomas are slow-growing cystic lesions, immature teratomas can degenerate with incomplete resection. In some literature, immature teratomas are classified as malignant germ cell tumors because of their ability to metastasize [8,9,10]. Grade 3 immature teratomas have a highly malignant potential and their rapid local and distant progression is responsible for higher recurrence and death rates with a 5-year survival rate of 90-100% with chemotherapy [11].

IV. CONCLUSION

The diagnosis of a dermoid cyst is histological [11]. A cystectomy is preferred in women of childbearing age. Laparoscopy is increasingly indicated, but laparotomy is indicated for large cysts [6]. Conservative treatment is recommended, bearing in mind that a degeneration in women who have already reached menopause is possible [5].

REFERENCES

1. Jama FE, Al Ghamdi AA, Gasim T, Al Dakhiel SA, Rahman J, Rahman MS. Ovarian tumors in children and adolescents a clinical study of 52 patients in a university hospital. J Pediatr Adolesc Gynecol. 2011;24:25–8.
2. Garner MM, Hernandez-Divers SM, Raymond JT. Reptile neoplasia: a retrospective study of case submissions to a specialty diagnostic service. Vet Clin North Am Exot Anim Pract. 2004;7:653–71.
3. Doss N, Jr, Forney JP, Vellios F, Nalick RH. Covert bilaterality of mature ovarian teratomas. Obstet Gynecol. 1977;50:651–3.
4. Pepe F, Lo Monaco S, Rapisarda F, Raciti G, Genovese C, Pepe P. An unusual case of multiple and bilateral ovarian dermoid cysts. Case report. G Chir. 2014;35:75–7.
5. Peterson CM, Buckley C, Holley S, Menias CO. Teratomas: a multimodality review. Curr Probl Diagn Radiol. 2012;41:210–9.
6. Bollen N, Camus M, Tournaye H, De Munck L, Devroey P. Laparoscopic removal of benign mature teratoma. Hum Reprod. 1992;7: 1429–32.
7. Laberge PY, Levesque S. Short-term morbidity and long-term recurrence rate of ovarian dermoid cysts treated by laparoscopy versus laparotomy. J Obstet Gynaecol Can. 2006;28: 789–793.
8. Shimura K, Matsumoto M, Sugahara T, Yamamoto T, Ogiso N, Urata Y, Okubo T. Mature cystic teratoma coexisting with clear-cell carcinoma in the ovary. J Obstet Gynaecol Res. 2017;43:408–11.
9. Sugiyama T, Kamura T, Kigawa J, Terakawa N, Kikuchi Y, Kita T, Suzuki M, Sato I, Taguchi K. Clinical characteristics of clear cell carcinoma of the ovary. Cancer. 2000;88:2584–9.
10. Harada M, Osuga Y, Fujimoto A, Fujii T, Yano T, Kozuma S. Predictive factors for recurrence of ovarian mature cystic teratomas after surgical excision. Eur J Obstet Gynecol Reprod Biol. 2013;171:325–8.
11. Newman SJ, Brown CJ, Patnaik AK. Malignant ovarian teratoma in a red-eared slider (Trachemys scripta elegans) J Vet Diagn Invest. 2003;15:77–81.

© 2020 London Journals Press

This page is intentionally left blank

© 2020 London Journals Press

Scan to know paper details and
author's profile

Efficacy of Auramine -O Stain Over ZN Stain in Diagnosis of Tubercular Lymphadenitis

Rajat Kumar, Khushbu Kumari & Dr. S.S. Hiremath

ABSTRACT

Background: Lymphadenopathy is one of the most common extrapulmonary manifestations accounting to around 30-40% of Tuberculosis. In high incidence of Tuberculosis globally, it is highly important for a clinician to take a quick decision for the patient in order to identify highly serious tuberculosis positive patient and start therapy. FNAC has become a popular tool in giving a rapid diagnosis.

Demonstration of acid-fast organisms is a fool proof evidence of tuberculosis as various cytomorphological pictures may differentiate from other diseases.

Objective: To analyse the efficacy of Fluorescent stain Auramine-O over Ziehl-Neelsen stain in identifying tubercle bacilli in Lymph node aspirates.

Material & Methods: A total of 120 patients referred to the Department of Pathology, SNMC & HSK Hospital, Bagalkot for FNAC of palpable lymph node lesions suspicious for tuberculosis were taken for study. FNAC was done using the standard method.

Keywords: acid-fast bacilli; auramine-o; fnac; fluorescent microscopy.

Classification: NLMC Code: WH 700

Language: English

London Journals Press

LJP Copyright ID: 392863

London Journal of Medical and Health Research

Volume 20 | Issue 1 | Compilation 1.0

© 2020. Rajat Kumar,Khushbu Kumari & Dr. S.S. Hiremath.This is a research/review paper, distributed under the terms of the Creative Commons Attribution-Noncom-mercial 4.0 Unported License http://creativecommons.org/licenses/by-nc/4.0/), permitting all noncommercial use, distribution, and reproduction in any medium, provided the original work is properly cited.

Efficacy of Auramine -O Stain Over ZN Stain in Diagnosis of Tubercular Lymphadenitis

Rajat Kumar[α], Khushbu Kumari[σ] & Dr. S.S. Hiremath[ρ]

ABSTRACT

Background: Lymphadenopathy is one of the most common extrapulmonary manifestations accounting to around 30-40% of Tuberculosis. In high incidence of Tuberculosis globally, it is highly important for a clinician to take a quick decision for the patient in order to identify highly serious tuberculosis positive patient and start therapy. FNAC has become a popular tool in giving a rapid diagnosis.

Demonstration of acid-fast organisms is a fool proof evidence of tuberculosis as various cytomorphological pictures may differentiate from other diseases.

Objective:

- *To analyse the efficacy of Fluorescent stain Auramine-O over Ziehl-Neelsen stain in identifying tubercle bacilli in Lymph node aspirates.*

Material & Methods: A total of 120 patients referred to the Department of Pathology, SNMC & HSK Hospital, Bagalkot for FNAC of palpable lymph node lesions suspicious for tuberculosis were taken for study. FNAC was done using the standard method. Smears from aspirates were subjected to routine cytological stains. Results were categorized into six (6) cytomorphological patterns:

(i) Epithelioid Granuloma with Langhans' giant cells and caseous necrosis.

(ii) Numerous epithelioid cells and granulomas in a reactive background.

(iii) Caseous necrosis with few epithelioid cells.

(iv) Caseous necrosis with few lymphocytes and histiocytes. No epithelioid cells.

(v) Only caseous necrosis without any cell type.

(vi) Tubercular abscess showing predominantly neutrophils along with epithelioid cells.

ZN stain, Pap stain & Auramine-O fluorescent stains were used to detect acid fast bacilli. A protocol for the examination of the positivity for AFB with a grading system was used.

Results: Among 120 cases of tubercular lymphadenitis, the most common cytomorphological pattern seen is pattern II & VI. Ziehl-Neelsen stain demonstrated 20.83% (25/120) positive cases whereas Auramine-O stain demonstrated 53.33% (64/120).

Conclusion: Fluorescent method in combination with cytomorphological pattern of Tubercular lymphadenitis is useful for evaluating lymph node lesions.

Keywords: acid-fast bacilli; auramine-o; fnac; fluorescent microscopy.

Author α: M.D (Pathology),Dy. M.S, Department of Pathology, Lab. In charge, Central Hospital, NCL, M.P,India. Singrauli-486889.

σ: M.D, DCP (Pathology) Consultant, Chitranshu Pathology Lab., Anapra, Sonebhadra-231220, U.P,India.

ρ: M.D, D.C.P (Pathology) Professor, Department of Pathology, S.N Medical College, Bagalkot-587102, Kernataka,India.

I. INTRODUCTION

Tuberculosis (TB) is the major health problem in the world since 1993 when it was declared as a

© 2020 London Journals Press

global emergency by the World Health Organization (WHO). [9] Extra-Pulmonary tuberculosis (EPTB), particularly tuberculous lymphadenitis (TBL), continues to be a major health problem in developing countries.[11] India has the highest burden of tuberculosis. The World Health Organisation (WHO) statistics for 2015 give an estimated incidence of 2.2 million cases of TB for India out of a global incidence of 9.6 million. [13] Tuberculosis continues to be a major health problem in our country and is the single largest cause of loss in a healthy life year in the productive age groups. [7] FNAC can be an important tool in suspecting TB lymphadenitis based on identifying epithelioid granulomas and caseous necrosis. Smear examination is believed to be simple, cheap, quick, practicable and effective case finding methods for developing countries. As tubercular bacilli are very slow growing organisms, culture results are available after a period of three to six weeks. [7] Ziehl-Neelsen is the most extensively used procedure for the determination of Mycobacterium tuberculosis in smears. [7] Fluorescent staining by Auramine is another method of staining. In this a smear is made from the specimen and stained with fluorescent stain called Auramine-O. Auramine stain enters the wall of Mycobacterium Tuberculosis bacterial cell and makes them glow against dark background under UV light. [52] Lymphadenopathy is one of the most common extrapulmonary manifestations accounting to around 30-40% of TB. [6] FNAC can be an important tool in suspecting TB lymphadenitis based on identifying epithelioid granulomas and caseous necrosis. Conventional Ziehl-Neelsen (ZN) method of detection of acid - fast bacilli (AFB) is simple and rapid but lacks sensitivity ranging from 20% to 43%. Hence, the Fluorescent method for detection of AFB has proven more effective than the ZN method. [6] The most important advantage of fluorescence microscope technique is that the slides can be examined at a lower magnification, thus allowing the examination of a much larger area per unit of time. The tubercular bacilli stand out as bright objects against dark background in fluorescence microscopy which makes them easily identifiable hence causing less eye strain.

Strain:

Depending upon the cytomorphological appearances, TB lymph node aspirates were subdivided further into Six (06) patterns: [6].

1. Epithelioid granulomas with Langhans' giant cells and caseous necrosis.
2. Numerous epithelioid cells and granulomas in a reactive background.
3. Caseous necrosis with few epithelioid cells.
4. Caseous necrosis with few lymphocytes and histiocytes. No epithelioid cells.
5. Only caseous necrosis without any other cell type.
6. Tubercular abscess showing predominantly neutrophils along with epithelioid cells.

II. MATERIAL & METHODS

Sources of data:

- The present study is a prospective study based on FNAC sampling of 120 cases of suspected tubercular lymphadenitis over a period of Dec 2016 to May 2018 (18 months) in the Department of Pathology, S.N Medical College & H.S. Kumareshwar Hospital, Bagalkot.
- Ethical clearance has been obtained from the "Institutional Ethical Committee" of S. N.

Medical College, Bagalkot:

After clinical examination, with prior consent, fine needle aspiration will be done on all referred cases of clinically diagnosed tuberculous lymphadenitis. Air dried smear will be subjected to Ziehl-Neelsen, Auramine- O and Giemsa Stain. Prior fixation in 95% ethyl alcohol will be done for H&E and Papanicolaou stain.

- Auramine-O Stain & Papanicolaou stains are also seen under Fluorescent Microscope.
- Light microscopy & Fluorescent Microscopy findings will be analysed.

© 2020 London Journals Press

Inclusion criteria for the study group:

- Clinically Diagnosed cases of Tuberculous Lymphadenitis.

Exclusion criteria for the study group:

- Non-cooperative Patient.
- Cytological Diagnosis other than Tuberculous Lymphadenitis.
- Diagnosed cases of T.B Lymphadenitis who are under anti tubercular treatment.

As per study done by Kulkarni. M.H et al, Sensitivity of ZN and Auramine stain of 58% and 81% respectively .

Statistical analysis: Data will be analysed using SPSS software. Proportion and percentage is used for qualitative data. Sensitivity, Specificity, Positive predictive value, Negative Predictive value and Diagnostic accuracy for Auramine-O Stain will be calculated.

Patients were clinically evaluated and an informed consent was obtained for the FNAC procedure. The limitations and complications of FNAC were explained to the patients.

Air dried & heat fixed smears used for ZN stain & Auramine-O fluorescent stain. The slides were examined under 10x & 40x & the ZN stain with oil immersion field.

Interpretation of aspiration was done as follows:

- Assessment of the adequacy of material in the smear.
- Cytomorphological features: overall cell population & predominant pattern were
- assessed by examination under low power. The individual cell morphology for
- epithelioid cell morphology, Langhans' type of giant cell, lymphocytes etc. was
- studied under high power.

Grading of Ziehl-Neelsen staining [7]

- More than 10 AFB per oil immersion field Positive 3+
- 1-10 AFB per oil immersion field Positive 2+
- 10-99 AFB per 100 oil immersion field Positive 1+
- 1-3 AFB per 100 oil immersion field Doubtful Positive.
- No AFB per 100 oil immersion field Negative.

Doubtful positive cases were taken as scantily positive due to the presence of occasional Bacilli.

Interpretation:

-Smears were examined carefully in a linear pattern or three horizontal sweeps by scanning at least 50-100 fields before reporting as negative or positive. Observation done under lower power magnification using fluorescent microscope.

Bacilli appear as bright yellow to orange against a dark background.

Positive smears are graded into four categories based on the grading system used by Central TB Division, Directorate General of Health Services, Ministry of Health and Family Welfare, RNTCP Manual for sputum smear fluorescence microscopy. New Delhi 110011.

Grading of Auramine-Rhodamine staining [60] Fluorescence staining using 20x objective.

Reporting

- 100 AFB/20fields Positive, 3+
- 11-100 AFB/50fields Positive, 2+
- 1-10 AFB/100fields Positive, 1+
- 1-3 AFB/100fields Doubtful positive/repeat
- No AFB per 100fields Negative.

Internal quality control measures taken for reagents and smears. The containers of all reagents with the date first opened were noted. Any material found to be unsatisfactory, for instance poor quality of reagents, expired reagents, change of colour of the reagents on exposure to atmospheric air, scratched slides etc. were discarded.

Standardisation of AO fluorescent staining:

- Known positive and negative smears of about 8-10 sputum samples were stained & studied

© 2020 London Journals Press

for standardization of Auramine-O staining.

- It included proved and confirmed Grade 1+ to 3+ positive smears and two negatives smears.

III. RESULTS

In the present study, the age of the patients ranged from 3 months to 80 years. Sex Ratio: Male: Female=1.06:1. Evening rise of Fever, loss of weight (10% loss of weight in 3 months), lymphadenopathy are prominent features. Loss of weight is the most common clinical presentation seen.

Fever (Evening rise of temperature) shows 46.67% cases. Loss of weight (10% loss in last 3 months) 51.67% cases. Lymphadenopathy 31.67% cases. Fever Loss of weight Lymphadenopathy 8.33% cases.

Most common Lymph node involvement is the cervical group of lymph nodes in 62.5% cases.

Single group of lymph nodes were involved in 107cases.Generalized lymphadenopathy was seen in 13 cases involved. Matted group of lymph nodes was noticed in 55 cases. Nature of the aspirate was blood mixed. Most common cytomorphological pattern seen is Caseous necrosis with few lymphocytes and histiocytes. No epithelioid cells.
In clinically diagnosed cases,
Auramine-O shows

- Sensitivity=76% PPV=29.69%,
- Specificity=52.63% NPV=89.29% Diagnostic Accuracy =57.5%

whereas ZN shows

- Sensitivity = 70%
- Specificity=97.1%

at 95% confidence limit.

IV. CONCLUSION

It shows that Auramine-O is more sensitive than ZN stain in the diagnosis of Tubercular Lymphadenitis especially in Paucibacillary cases & less specific in diagnosis of tuberculosis in lymph node aspirates.

The Auramine-O stain detected acid fast bacilli in a greater number of cases when compared to Ziehl-Neelsen stain. A statistically significant differentiation was seen in the detection of acid-fast bacilli by the AO stain with a significant p value. No acid-fast bacilli were observed in 56 cases (Auramine-O, ZN, Pap).

Cases POSITIVE p-value*

ZN Stain 25(20.8%) ,Auramine -O stain 64(53.3%) p=0.0001(Significant) *Based on Z test.

V. DISCUSSION

Koch first described the tubercle bacilli in 1882, which is now known as mycobacterium tuberculosis. Mycobacteria are now known to comprise a large group of acid-fast, alcohol-fast, aerobic or microaerophilic, non-spore forming, non-motile bacilli.[17] Ghali et al. (1984) first demonstrated auto fluorescence of pneumocystic carinii in Pap stained smear. Their results indicated eosin to be responsible for the autofluorescence. Its value in the fluorescent microscopic diagnosis is well established. In Pap stained smear the slightly curved, beaded tubercle bacilli may be readily identified. [17] An advantage of fluorescent microscopy lies in the ease with which bacilli can be detected due to color contrast, allowing for a larger area of the smear to be scanned at lower magnification when compared with conventional ZN staining. Since the Pap stain is routinely used in cytology, it saves the time and material that would be involved in

© 2020 London Journals Press

any extra staining and also avoids the use of toxic or carcinogenic substances such as phenol and rhodamine, which are used in A-R staining method.[10].

Goyal. R. et al. (2013) reported that Fluorescent Microscopy greatly improves the diagnostic value of sputum smear especially in patients with low density of bacilli that are likely to be missed on Ziehl Neelsen stained smear. [7].

Thakur. B et al. (2013) also found that, Conventional ZN method for AFB plays a key role in the diagnosis & monitoring of treatment of Tuberculosis. Its major disadvantage is low sensitivity, time consuming, and oil immersion use. Fluorescent microscopy plays an important role for detection of MTB because lower magnifications are used as well as less time consuming.[5] Tuberculosis is a worldwide public health problem in spite of the fact that the causative organism Mycobacterium tuberculosis was discovered 100 years ago. [16] Globally, it is estimated that one-third of the population is asymptomatically infected with tuberculosis. [16].

ZN stain is commonly used throughout the world and still remains the standard method against which new tests must measure. [8] . The Utilization of auramine-O, fluorescent dye instead of carbol fuchsin, was first proposed in 1930 but found widespread application in industrialized countries only. [9].

Study conducted by Osman. A.N et al. (2014) revealed that Fluorescent staining is regarded as a more reliable method due to more intensive binding of mycolic acid of the bacilli to phenol auramine-o, so that the bacilli can stand out sharply against black background to allow rapid & accurate screening under low power microscope.[9].

A Patient with positive smears carries the greatest no. of tubercle bacilli and is the most infectious and hence the most important patient to be detected early. Fluorescence microscopy using fluorochromes (Auramine-Rhodamine) is more sensitive and rapid as compared to conventional microscopy using Ziehl-Neelsen (ZN) staining. [18].

Holani et al have successfully demonstrated presence of tubercle bacilli in saliva using fluorochromes staining. [18] Pap stain allows prospective as well as retrospective analysis of cases in which material for staining by other methods is not available and obviates need to restain existing slides. [18].

An advantage of fluorescence microscopy lies in the ease with which the bacilli can be detected due to the color contrast, allowing for a larger area of the smear to be scanned at lower magnification when compared to conventional ZN staining. Since the Pap stain is routinely used in cytology, it saves the time and material that would be involved in any extra staining and also avoids the use of toxic or carcinogenic substances such as phenol and rhodamine, which are used in A-R staining method.[18].

FNAC of lymph nodes is a safe, simple and inexpensive definite diagnostic procedure to render a prompt diagnosis, especially in lymph node aspirates, where biopsies are not done commonly. The limitations are with necrotic lymphadenopathy, heterogenous swelling with limited representative aspirates, where if the clinician is unsatisfied with the cytological diagnosis further workup like biopsy is required in order to make a reliable diagnosis. [14].

© 2020 London Journals Press

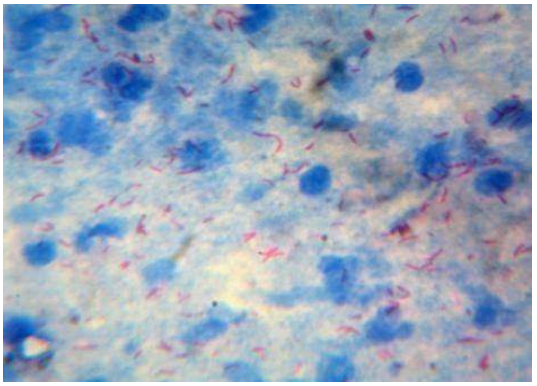

Fig. 1: AFB Positive 3+ (ZN Stain)

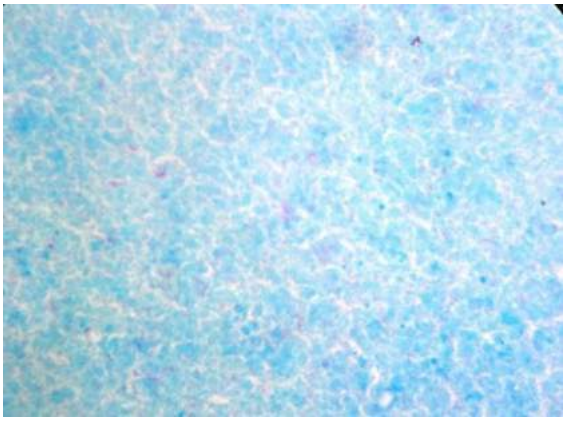

Fig.2: AFB Positive 2+ (ZN Stain)

Fig. 3: Auramine- O Stain 2+ (20X)



Fig.4: Auramine- O Stain 3+ (20X)

REFERENCES

1. Sen R, Marwah N, Gupta K.B, Marwah S, Arora R, Jain K; cytomorphologic patterns in tuberculous lymphadenitis; Ind. J.Tub.1999, 46,125.
2. Krishnaswami H, Job C. K; The role of Ziehl-Neelsen and fluorescent stain in tissue section in the diagnosis of tuberculosis; Ind. J. Tub.,1999,10,13.
3. Mukherjee A, Kalra N, Beena K.R; Immunohistochemical detection of myco-bacterial antigen in tuberculous lym-phadenitis; Ind. J. Tub.; 2002,49,213.
4. Annam V, Kulkarni M.H, Puranik R B; Comparison of the modified fluorescent method and conventional Ziehl-Neelsen method in the detection of acid fast bacilli in lymph node aspirates; cytojournal;2009;6;3.
5. Thakur B, Mehrotra R, Nigam J S; correlation of various techniques in diagnosis of tuberculous lymphadenitis on fine needle aspiration cytology; Pathology research international; Hindwani publishing corporation; 2013; article ID824620.
6. Nalini mohan C, Annam V, Gangane N; Efficacy of Fluorescent method over conventional ZN method in detection of acid fast bacilli among various cytomorphological pattern of tubercular lymphadenitis; IJSR;9, vol.4,2015.
7. Goyal R, Kumar A; A comparison of Ziehl-Neelsen staining and Fluorescent microscopy for diagnosis of Pulmonary Tuberculosis; IOSR-JDMS;5, vol.8,2013.
8. Hanif ain ul qurat, Muhammad J, Hussain T, Sheikh A. A. et al; Evaluation of conventional and molecular techniques in diagnosis of clinical samples of Mycobacterium Tuberculosis; World applied sciences;30(6); 762-764;2014.

© 2020 London Journals Press

9. Osman N A, Mustafa M A, Hassan M K, Tarek M M; comparative study of Auramine-O staining and Ziehl-Neelsen for diagnosis of pulmonary tuberculosis; nat. sci 2014;12(11); 59-63.
10. Lunawat P.P, Mapuskar A A ,Ganvir SM, Hazarey VK, Mapuskar MA, Kulkarni D; Detection of acid fast bacilli in saliva using Papanicolaou stain induced fluorescence method versus fluorochrome staining: An evaluation study; J Int oral health 2015;7(7); 115-120.
11. Abdissa K, Mulualem T, Abdella K, Bekele A, Bezabih M, Abede G; Diagnostic performance of fluorescent light emitting diode microscopy for tuberculous lymphadenitis in a high-burden setting; tropical medicine and international health,20(2);2015;1543-1548.
12. Mitra SK, Misra RK, Roi P; Cytomorphological pattern of tubercular lymphadenitis and its comparison with Ziehl-Neelsen staining and culture in eastern up.(Gorakhpur region); J cytol 2017;34;139-43.
13. Krishna M, Gole SG, Comparison of conventional Ziehl-Neelsen method of acid fast bacilli with modified bleach method in tuberculous lymphadenitis; J. cytol 2017;34;188-92.
14. Gojiya P, Goswami A, Shah S; Evaluation of fine needle aspiration cytology of cervical lymphadenopathies at tertiary care center; apalm; vol.5,1,2018.
15. Singh N, Singh A, Chauhan R, Singh P, Verma N; Fine needle aspiration cytology in evaluation of lymphadenopathy in pediatric age group: our experience at tertiary care centre.; international journal of contemporary medical research 2016;3(5);1347-1351.
16. Bhumbla U, Gyaneshwari ; A comparative study of Ziehl-nelson staining and auramine staining in sputum samples for the diagnosis of pulmonary tuberculosis; IJBR;05(06);2014.
17. Krishna M, Kumar A; Autofluorescence in pap stain in the sputum of suspected pulmonary tuberculosis and compared with other AFB stains; J. Evolution Med. Dent.sci. 2016;5(16): 755-757.
18. Lunawat P.P, Mapuskar A.A, Ganvir S.M, Hazarey VK, Mapuskar MA, Kulkarni D; Detection of acid fast bacilli in saliva using Papanicolaou stain induced fluorescence method versus fluorochrome staining: An Evaluative study. J Int Oral Health 2015;7(7);115-120. 19. Park K, Textbook of social & preventive medicine,22nd edition, 2013.
19. WHO (2011) Policy framework for implementing new tuberculosis diagnostics, March 2010.
20. World Health Organization (WHO), "Tuberculosis Fact Global And Regional Incidence," Sheet No. 104-2006; 1992.
21. Flick LF. Development of our knowledge of tuberculosis. Philadelphia: Wickersham; 1925.
22. Rosenblatt MB. Pulmonary Tuberculosis: Evolution of Modern Therapy. Bull NY Acad Med 1973; 49:163-96.
23. Roopa AN, Suma MN and Shariff S. Role of fine needle aspiration cytology and fluid cytology in Extrapulmonary tuberculosis. Diagnostic Cytopathology 2012; 41: 392–398
24. Wares F, Balasubramanian R, Mohan A, Sharma SK. Extrapulmonary Tuberculosis: Management and Control. Agarwal & Chauhan Editors.
25. Tuberculosis Control in India. New Delhi: Directorate General of Health Services, Ministry Of Health And Family Welfare; 2005.P.95-114.
26. Dani S. Zander, Carol F. Faver. Pulmonary Pathology, a Volume In The Series Foundations In Diagnostic Pathology. Churchill Livingstone Elsevier; 1st Edi 2008 .
27. Patrick H, Henry Dan L, Longo. Enlargement of Lymph Nodes and Spleen. In Kasper DI, Braunwald E, Fauci AS, Hauser SI, Longo DI, Jameson JI:
28. Harrison's Principles Of Internal Medicine, Volume 1, 19th Edition,Mcgraw Hill. 2008: 370-372.
29. Gupta AK, Nayar, and Chandra M. Critical Appraisal of Fine Needle Aspiration Cytology in Tuberculous Lymphadenitis. Acta Cytologica 1992; 36: 391-394.

© 2020 London Journals Press

30. World Health Organization (WHO) Tuberculosis Fact Global and Regional Incidence 2006; Sheet No.104:101.
31. Parveen K, Momen A, Khodeza tul K. Frequency of tuberculosis in patients with enlarged lymph nodes and its cost-effective first line of diagnosis in our country. J. Dhaka National Med. Coll. Hos. 2011; 17 (02): 34-39.
32. Arora B, Arora DR. Fine needle aspiration cytology in diagnosis of tuberculous lymphadenitis. Indian J Med Res. 1990; 91:189-92.
33. Sharma SK & Mohan A. Extrapulmonary tuberculosis. Indian J Med Res 120, October 2004, pp 316-353.
34. Shariff S and Thomas JA. Fine needle aspiration cytodiagnosis of clinically suspected tuberculosis in tissue enlargements. Acta Cytological 1991 March April.; 35: 333-336.
35. Singh A, Singh A, Chauhan R, Singh P, Verma N; Fine needle aspiration cytology in evaluation of lymphadenopathy in Pediatric age group; our experience at tertiary care centre. International Journal of Contemporary Medical Research 2016;3(5):13471351.
36. Ioachim HL, Medeiros LJ. The normal lymph node. In: Ioachim's lymph node pathology. 4th ed. Philadelphia: Wolters Kluwer/ Lippincott Williams & Wilkins; 2009. p. 1–14
37. Van den Oord JJ, De Wolf-Peeters C, Desmet VJ, et al. Nodular alteration of the paracortical area. An in situ immunohistochemical analysis of primary, secondary, tertiary T- nodules. Am J Pathol. 1985; 120:55–66.
38. Roberto N. M , Joseph D. K, L. Jeffrey Medeiros ; Atlas of Lymph Node Pathology; chapter 1; Springer ; New York ; 2013 .
39. Asano S. Granulomatous lymphadenitis. J Clin Exp Hematop. 2012; 52:1–16.
40. Roberto N.M , Joseph D.K , L. Jeffrey Medeiros ; Atlas of Lymph Node Pathology ;chapter 5; Springer ; New York ; 2013 .
41. Aggarwal P, Wali JP, Singh S, et al. A clinico-bacteriological study of peripheral tuberculous lymphadenitis. J Assoc Physicians India. 2001; 49:808–12.
42. Hochedez P, Zeller V, Truffot C, et al. Lymph-node tuberculosis in patients infected or not with HIV: general characteristics, clinical presentation, microbiological diagnosis and treatment. Pathol Biol (Paris). 2003; 51:496–502.
43. Askota D.K, Prasad R, Kumar Sinha B, Amatya RC. Distribution of lymph nodes in the neck in cases of tuberculous cervical lymphadenitis. Acta Otolaryngol. 2004; 124:1095–8 .
44. Wu RI, Mark EJ, Hunt JL. Staining for acid-fast bacilli in surgical pathology: practice patterns and variations. Hum Pathol. 2012; 43:1845–51.
45. Ramakrishnan L. Revisiting the role of the granuloma in tuberculosis. Nat Rev Immunol. 2012; 12:352–66.
46. Logan's, Lucas DR, Cheng JD, et al. Spindle cell tumours associated with mycobacteria in lymph nodes of HIV-positive patients: "Kaposi sarcoma with mycobacteria" and "mycobacterial pseudotumor". Am J Surg. Pathol. 1999; 23:656– 61.

© 2020 London Journals Press

Scan to know paper details and
author's profile

The Place of Transcervical Amnioinfusion in the Management of Preterm Premature Rupture of Membranes Remote from Term in a Private Institution

Olusanya Abiodun & Omobolaji Oguntoyinbo

ABSTRACT

Background: pPROM complicates about 10% of pregnancies and it occurs in populations of low socioeconomic status. It is a major cause of neonatal morbidity and mortality. The objective of this study was to determine the usefulness of therapeutic transcervical amnioinfusion in prolonging the latency period and thereby leading to the reduction of morbidity associated with pPROM.

Methodology: This study was conducted in the department of Obstetrics and Gynaecology of Sacred Heart Hospital, lantoro. In this study, a total of 51 patients that met the inclusion criteria were recruited. Diagnosis of pPROM was strictly by gentle sterile speculum with evidence of either a gush of fluid from external cervical os or pool of liquor in the posterior fornix of the vagina in antenatal patients whose gestation ages were within the inclusion criteria. Statistical Package for Science Student (SPSS) version 21 was used in the analysis of data collected.

Keywords: amnioinfusion, pregnancy, reduced liquor, pprom.

Classification: NLMC Code: WQ 211

Language: English

London Journals Press

LJP Copyright ID: 392864

London Journal of Medical and Health Research

Volume 20 | Issue 1 | Compilation 1.0

© 2020. Olusanya Abiodun & Omobolaji Oguntoyinbo. This is a research/review paper, distributed under the terms of the Creative Commons Attribution-Noncom-mercial 4.0 Unported License http://creativecommons.org/licenses/by-nc/4.0/), permitting all noncommercial use, distribution, and reproduction in any medium, provided the original work is properly cited.

The Place of Transcervical Amnioinfusion in the Management of Preterm Premature Rupture of Membranes Remote f rom Term in a Private Institution

Olusanya Abiodun[α] & Omobolaji Oguntoyinbo[σ]

ABSTRACT

Background: pPROM complicates about 10% of pregnancies and it occurs in populations of low socioeconomic status. It is a major cause of neonatal morbidity and mortality. The objective of this study was to determine the usefulness of therapeutic transcervical amnioinfusion in prolonging the latency period and thereby leading to the reduction of morbidity associated with pPROM.

Methodology: This study was conducted in the department of Obstetrics and Gynaecology of Sacred Heart Hospital, lantoro. In this study, a total of 51 patients that met the inclusion criteria were recruited. Diagnosis of pPROM was strictly by gentle sterile speculum with evidence of either a gush of fluid from external cervical os or pool of liquor in the posterior fornix of the vagina in antenatal patients whose gestation ages were within the inclusion criteria. Statistical Package for Science Student (SPSS) version 21 was used in the analysis of data collected.

Results: The mean age of the patients was 26.5years while the gestational age group 26-29weeks constituted 51% with the mean gestational age constituting 29.7weeks.13.7% of the patients recruited exhibited the indices of sepsis measured compared to 86.3% that did not exhibit any evidence of sepsis. Our study did not find any statistically significant relationship between transcervical route amnioinfusion and sepsis with the chi-square being 0.123 and the relative risk (RR) of 0.750 {95% CI 0.150 to 3.750}. Latency period was greatly increased in the test group compared to the control with a chi-square(X^2) of 0.000. Only one baby in the test group had asphyxia compared to 10 babies in the control arm of the study with X^2 of 0.003. There was a statistically significant relationship between birth weight at birth in the test group compared to the control group with a X^2 of 0.000. There was no maternal or neonatal death in this study.

Conclusion: Transcervical route amnioinfusion is as safe as the transabdominal route in carefully selected patients; this route is less invasive and cheaper compared to the transabdominal method and it will find usefulness in resource-constraint environments. It raises the liquor volume and prolongs latency period in patients thereby contributing to the improvement in neonatal outcome.

Keywords: amnioinfusion, pregnancy, reduced liquor, pprom.

Author α σ: Department of obstetrics and gynaecology, Sacred Heart Hospital, Abeokuta, postcode 110001, Nigeria.

I. INTRODUCTION

Rupture of membranes is an integral part of the normal and abnormal labour process.[1] Preterm premature rupture of membranes (pPROM) is defined as the spontaneous rupture of the foetal membranes before the onset of labour.[1-4] Premature rupture of membranes (PROM) complicates approximately 10% of pregnancies,

© 2020 London Journals Press

with 3% of pregnant women having pPROM before 37weeks of gestation.[1,5]pPROM is more likely to occur in populations of lower socioeconomic status and complicates one-quarter to one-third of preterm births.[5-7]It is a major cause of neonatal morbidity and mortality because these babies are born preterm.[8]Presently pPROM can be classified into pre-viable pPROM this occurs before the age of viability[9], pPROM remote from term this occurs from the age of viability to approximately 31weeks, and pPROM near term that occurs approximately from 32 to 36weeks of gestation[1].

Few clinical conditions in obstetrics are as challenging as pPROM remote from term.[10]Management is influenced by gestational age and the presence of complicating factors, such as clinical infection, abruptio placentae, labour, or non-reassuring foetal status.[11] The aetiology is multifactorial.[1]It is hypothesized that a weakness in the foetal membranes occurs as a result of either a stretch or degradation of the extracellular matrix.[12]Other factors include ascending infection from the lower genital tract that serves a potential reservoir for bacteria that ultimately ascend into the cervix to cause inflammation and infection[1], history of cervical insufficiency, antepartum bleeding, multiple gestations, previous PROM or preterm labour, tobacco use, cervical cerclage, and amniocentesis[8]. However, most cases of preterm PROM occur in otherwise healthy women without identifiable risk factors.[9]

In recent years, different strategies had been tried to decrease neonatal morbidity and mortality rates resulting from pPROM.[8] None of these strategies has proved to be consistently effective, reproducible, or applicable to most centres.[8]Infusing physiologic solution into the amniotic cavity was suggested as a treatment modality to prolong the latency period and prevent complications that are associated with a reduction in amniotic fluid volume in cases of pPROM.[13,14]The latency period is defined as the interval between rupture of membranes and onset of labour.[15] Amnioinfusion (AI) entails infusion of normal saline or Ringer's lactate solution into the uterine cavity to replace the lost amniotic fluid.[16]Apart from prolonging the latency period there is some evidence to show that restoring amniotic fluid volume with saline or a similar fluid following pPROM may be beneficial for preterm babies (by preventing infection, lung hypoplasia and death) and mothers (by preventing endometritis after delivery).[17,18]

Amnioinfusion can be carried out either through the abdominal route[19] or cervical route[20,21]. Since transabdominal amnioinfusion is carried out through a sterile field compared to the transcervical route it should theoretically be associated with less risk of infection, it is not without its own risk of complications like placenta abruption and chorioamnionitis.[8,21]

The objective of this study was to determine the usefulness of transcervical AI in prolonging the latency period of pregnancies complicated by pPROM and improvement in maternal and neonatal outcome.

II. METHODOLOGY

This study was a prospective randomized-controlled study that spanned over a 12month period starting from January 1st 2017 to December 31st 2017 in the Obstetrics and Gynaecology unit of Sacred Heart Hospital, Lantoro, Abeokuta in Ogun State. The hospital is a 300 bedded hospital with the Obstetrics and Gynaecology unit having 88beds in various parts of the department. The hospital is the first hospital in Nigeria with clienteles from the whole of the South-West of Nigeria as well as the Republic of Benin. The hospital engages in the training of postgraduate medical doctors in family medicine as well as nursing students.

Ethical approval was sought and obtained from the Ethical committee of the hospital. All consenting pregnant women who presented to the antenatal clinic and the antenatal or labour ward that met the inclusion criteria that included singleton foetus between 26 and 33weeks, history of drainage of liquor, objective demonstration of

© 2020 London Journals Press

drainage of liquor by sterile speculum examination in addition to ultrasound diagnosis of amniotic fluid index (AFI) is ≤3.0cm, cervical dilatation ≤4cm, no sign of labour, and whose foetus was alive as confirmed by ultrasound scan were recruited into the study. However, patients that declined to participate, those with multiple foetuses, intrauterine foetal death as confirmed by ultrasound scan, cervical dilatation ≥4cm, ultrasound diagnosis of amniotic fluid index ≥3.0cm, lethal foetal congenital anomaly, no objective demonstration of drainage of liquor by a gentle speculum examination, and presence of chorioamnionitis were excluded from the study.

Designed proforma was used to obtain the necessary information that was relevant to the study.

Written informed consent was obtained from all pregnant women that met the inclusion criteria. The target populations were those between 26 and 33 weeks + 0days; 26weeks was selected as the lowest cutoff point, though the age of viability in our environment is 28weeks, this was to increase the number of patients recruited.

The unit protocol for determining eligibility for this study started with ensuring that the gestational age was between 26weeks and 33weeks + 0days, the history of drainage of liquor that must be confirmed by gentle sterile speculum in the antenatal ward or labour ward depending on where the recruitment took place. The AFI of ≤3.0cm and foetal viability as determined by the ultrasound scan. All patients that were eligible had AI done twice weekly using the transcervical route and ultrasound scan for foetal wellbeing monitoring before delivery. As part of routine care management of the unit all patients with pPROM remote-from-term are routinely placed on erythromycin tablet 500mg three times daily as a form of prophylaxis unless otherwise stated, and antepartum intramuscular dexamethasone injection administration for foetal lung maturity. The eligible patients were not excluded from this care management.

The unit elected to carry out the AI using the transcervical route because it is easier, less invasive compared to the transabdominal route, there was no need for any special skill to carry out the procedure, and this did not constitute an additional cost for us. Maximum of 250ml of saline was instilled during each session of AI, this is to reduce triggering uterine contractions. Strict asepsis was observed during the procedure in order to reduce the risk of chorioamnionitis to the barest minimum. There were two arms to the study ie one arm had AI and the other arm was the expectant conservative arm. The two arms were matched for gestational age; this was done in order to assess if AI had any effect in prolonging the latency period thereby leading to an improvement in neonatal outcome.

SPSS version 21 was used in the analysis of data

Maternal outcome:

Final gestational age at delivery

Sepsis/endometritis

Need to change antibiotics from prophylaxis to treatment

Death

Neonatal outcome:

Birth weight

Apgar score

Antepartum foetal death

Neonatal death

III. RESULTS

During the period of study, the total delivery recorded in the Obstetrics Unit of the hospital was 1,699, pPROM complicated 139 of the patients; this gives an incidence of 8.2% in the hospital. 51 patients that met the inclusion criteria were recruited for this study. There was neither maternal death nor neonatal death amongst the studied population. The table.1 displayed the sociodemographic data of the patients recruited for this study; a total number of patients that met the inclusion criteria and recruited for the study was 51 and their gestational ages were between 26

© 2020 London Journals Press

and 33weeks + 0 days respectively. 33.3% of the patients were between the age range of 21 – 25years while only 3.9% were 36years and above. As part of the inclusion criteria for this study the gestational age of patients was from 26weeks to 33weeks, those within 26 - 29weeks constituted 51% and those within 30 – 33weeks were 49% respectively. 23.5% of the patients were nullipara while 3.9% were para4 and above. The patients in the upper socioeconomic class constituted 11.8%, the middle class constituted 64.7%, and the lower class were 23.3%. Table 2 shows the relationship between the two arms of the study group, the two arms were matched for gestational age and there was no statistically significant relationship between the two groups. Figure 1 shows the bar chart depicting the indices of sepsis in both mothers and their foetuses; the indices assessed included maternal pyrexia, maternal tachycardia, uterine tenderness, and foetal tachycardia. Those that had the indices of sepsis present were 7(13.7%) while those without these indices were 44(86.3%) respectively. Figure 2 shows the pie chart depicting those that had prophylactic and treatment with antibiotic respectively. Those that had antibiotic treatment were 10(19.6%) and the patients that had prophylactic antibiotic were 41(80.4%). Table 3 showed that there was no statistically significant relationship between transcervical amnioinfusion and risk for sepsis using the transcervical route with the X^2 of 0.123 and the relative risk (RR) being 0.750 {95% CI 0.150 to 3.750}. Table 4 shows the cross-tabulation between amnioinfusion and latency periods; there is a statistically significant relationship between amnioinfusion and latency period with the X^2 of 0.000. Table 5 shows the cross-tabulation between amnioinfusion and Apgar score of babies whose mothers had amnioinfusion and those that did not, there was also a statistically significant relationship with the X^2 of 0.003, as shown in this table also the Apgar was better in the babies whose mothers had amnioinfusion.

Table 6 showed the relationship between AI and weight of babies in the two arms of the study, the babies in the test arm were heavier at delivery compared to the babies in the controlled arm with a statistically significant relationship between AI and weight.

Table 1: Sociodemographic characteristics of the population studied

Age(years)	Frequency	Percentage
≤20	11	21.6
21-25	17	33.3
26-30	1 8	15.7
31-35	13	25.5
≥36	2	3.9
Gestational age range(weeks) 26-29 30-33	26 25	51 49
Parity 0 1 2 3 ≥4	 12 18 15 4 2	 23.5 35.3 29.4 7.8 3.9
Socioeconomic status Upper class Middle class Lower class	6 33 12	11.8 64.7 23.3

Table 2: Gestational age against amnioinfusion

		Amnioinfusion		X^2
		yes	No	
GA	26-29	14	12	0.494
	30-33	11	14	
Total		25	26	

Table 3: Risk for sepsis against AI through the vaginal route

	Risk for sepsis Yes	No	X^2
Amnioinfusion Yes No	3 4	22 22	0.123
Total	7	44	

© 2020 London Journals Press

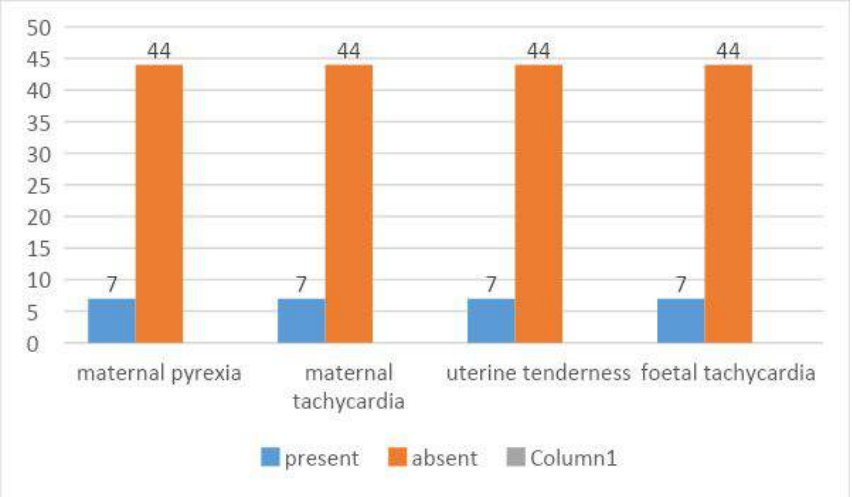

Figure 1: Indices of sepsis in mothers and foetuses

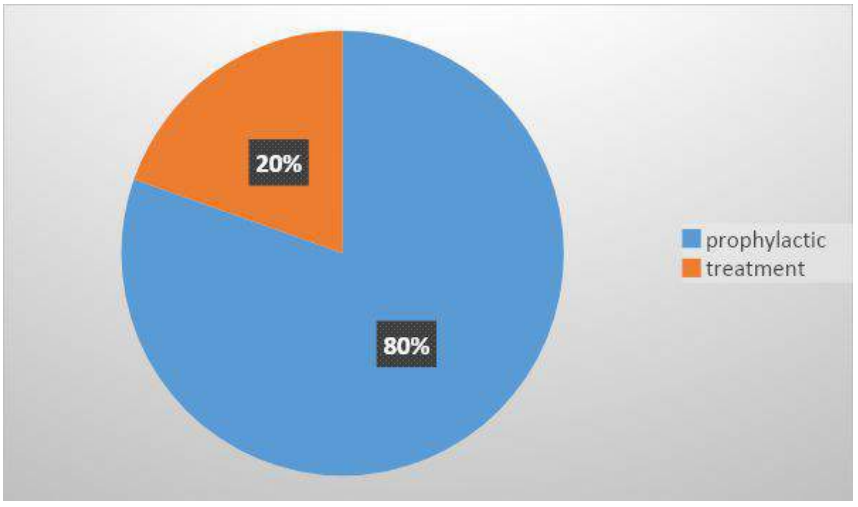

Figure 2: Prophylactic and treatment with antibiotics

Table 4: Relationship between amnioinfusion and latency period

		Latency period			X^2
		<7days	<14days	>14 – 21	
Amnioinfusion	Yes	2	8	15	0.000
	No	16	5	5	

Table 5: Relationship between amnioinfusion and APGAR scores

	APGAR		X^2
	No asphyxia	Asphyxia	
Amnioinfusion			
Yes	24	1	0.003
No	16	10	

© 2020 London Journals Press

Table 6: Relationship between amnioinfusion and weight of babies at delivery

		Weight				X^2
		<900g	900-1500g	1501-2000g	>2000g	
Amnioinfusion	Yes	0	5	15	5	0.000
	No	11	10	4	1	
Total		11	15	19	6	

IV. DISCUSSION

Preterm premature rupture of membranes is one of the leading causes of perinatal morbidity and mortality. Methods to improve neonatal outcome include amnioinfusion; this can be carried out through the transabdominal or vaginal route. None of these methods is devoid of complications. Drainage of liquor triggers labour irrespective of the gestational age, the labour could be spontaneous or iatrogenic. Preterm labour is associated with neonatal morbidity and/or mortality. The volume of residual amniotic fluid is associated with prolongation of latency period and improvement in perinatal outcome.[23]The aim of this study was to determine the usefulness of prophylactic transcervical AI in patients with pPROM between gestational age of 26 and <34weeks in prolonging latency period, and in reducing morbidities associated with preterm delivery.

Theoretically, there is the risk of the possibility of sepsis associated with transcervical AI[8,21], this was not found to be so in our study evidenced by the non-statistically significant relationship between the route chosen for this study and risk for sepsis. The indices for sepsis assessed revealed very few of the participants exhibiting such; only 10 (19.6%) out of the total number of patients recruited needed complete antibiotic treatment. The import of this finding is that with proper patient selection and under strict asepsis AI can be carried out using the transvaginal route as well with minimal risk of sepsis.

The latency period in the intervention group was also found to be prolonged compared to the control group; this finding was consistent with findings in Cochrane review by Hofmeyr et al[17], van Teeffelen et al[18], Fatima et al[23], Gazetti et al[24], and Qazi et al[25]. Apgar scores of the babies were significantly improved with only one baby being asphyxiated compared to 10 babies in the control arm. This procedure also had a positive influence on the weight of these babies though this was not found to be so in the Cochrane review carried out by Hofmeyr et al[17]. This stands to reason since the increase in latency will translate into a longer duration of pregnancy and ultimately increase in birth weight. During the period of this study, no perinatal death was recorded this high survival rate is comparable with the high survival rate found by Locatelli et al[26]as well as Hofmeyr et al[17] where a high survival rate of 92% and 87.3% respectively were recorded in patients that had amnioinfusion compared to the control group.

In conclusion, in carefully selected patients and observing strict asepsis transcervical AI is as safe as transabdominal route AI. This route ie transcervical AI is less invasive compared to transabdominal route AI and it will definitely find usefulness in the resource-constraint environment thereby contributing to the reduction on neonatal morbidity and mortality.

Conflict of interest:

The authors have none.

REFERENCES

1. Mercer B. Preterm Premature Rupture of the Membranes. Glob. libr. women's med., (ISSN: 1756-2228) 2008; DOI 10.3843/ GLOWM. 10120.

© 2020 London Journals Press

2. Fowlie A. Preterm pre-labour rupture of membranes, In: Arukumaran S, Symonds IM, Fowlie A (eds): Oxford Handbook of Obstetrics and Gynaecology. 2nd edition New Delhi, Oxford Universit Press 2004; 247-249.
3. Okeke TC, Enwereji JO, Okoro OS, Adiri CO, Ezugwu EC, Agu PU. The Incidence and Management Outcome of Preterm Premature Rupture of Membranes (PPROM) in a Tertiary Hospital in Nigeria. American Journal of Clinical Medicine Research, 2014, Vol. 2, No. 1, 14-.
4. American College of Obstetricians and Gynaecologists. Premature rupture of membranes. Practice Bulletin No. 172. Obstet Gynecol 2016; 128:e165–77.
5. Mercer BM. Preterm premature rupture of the membranes: current approaches to evaluation and management. Obstet. Gynecol. Clin. North Am. 2005;32:411-28.
6. Meis JP, Ernest M, Moore ML: Causes of low birthweight births in public and private patients. Am J Obstet Gynecol 1987;156:1165.
7. Savitz DA, Blackmore CA, Thorp JM: Epidemiologic characteristics of preterm delivery: Etiologic heterogeneity. Am J Obstet Gynecol 164:467, 1991.
8. Poraj S, Amsalem H, Sha PS, et al. Transabdominal amnioinfusion for premature preterm rupture of membranes: a systematic review and meta-analysis of randomized and observational studies. Am. J. Obstet. Gynecol. 2012;207:393.e 1-11.
9. Practice Bulletin. Premature Rupture of Membranes. vol.128, no. 4, oct,2016:e165-177.
10. Thaddeus PW, Mercer BM. The management of preterm premature rupture of the membranes near the limit of fetal viability. Am. J. Obstet. Gyneco. Sept.2009; 230-240.
11. Mercer BM. Premature Rupture of the membranes. An expert's view. Obstet. Gynecol.. 2003; 178:101.
12. French JI, Mc Gregor JA. The pathobiology of premature rupture of membranes. Semin. Perinatol. 1996;20:344-68.
13. Szabo I, Szilagyi A, Gacs E, Szekely J. Amnioinfusion for management of preterm prelabour rupture of membranes. Lancet 1993;341:443-4.
14. Fisk NM, Ronderos-Dumit D, Soliani A, Nicolini U, Vaughan J, Rodeck CH. Diagnostic and therapeutic transabdominal amnioinfusion in oligohydramnios. Obstet Gynecol 1991;78:270-8.
15. Aaron BC, Julian NR, Errol RN. Contemporary Diagnosis and Management of Preterm Premature Rupture of Membranes. Rev Obstet Gynecol. 2008;1(1):11-22
16. Aetna. Amnioinfusion. Medical Clinical Policy Bulletins. P1-17. http://www.aetna.com/cph/medical/data/400_499/0417.html. *Accessed 26/01/2019.*
17. Hofmeyr GJ, Eke AC, Lawrie TA. Amnioinfusion for third trimester preterm premature rupture of membranes. Cochrane Database of Systematic Reviews 2014, Issue 3. Art. No.: CD000942. DOI: 10.1002/14651858.CD000942.pub3.
18. van Teeffelen ASP, van der Ham DP, Willekes C, Al Nasiry S, Nijhuis JG, Sander van Kuijk S, et al. Midtrimester preterm prelabour rupture of membranes (PPROM): expectant management or amnioinfusion for improving perinatal outcomes (PPROMEXIL – III trial). BMC Pregnancy and Childbirth 2014, 14:128 http://www.biomedcentral.com/1471-2393/14/128.
19. Fisk NM, Ronderos-Dumit D, Soliani A, Nicolini U, Vaughan J, Rodeck CH. Diagnostic and therapeutic transabdominal amnioinfusion in oligohydramnios. Obstet Gynecol 1991;78:270-8.
20. Ogita S, Imanaka M, Matsumoto M, Oka T, Sugawa T. Transcervical amnioinfusion of antibiotics: a basic study for managing premature rupture of membranes. Am J Obstet Gynecol 1988;158:23-7.
21. Sadovsky Y, Amon E, Bade ME, Petrie RH. Prophylactic amnioinfusion during labour complicated by meconium: a preliminary report. Am J Obstet Gynecol 1989;161:613-7

© 2020 London Journals Press

22. Tan LK, Kumar S, Jolly M, Gleeson C, Johnson P. Test amnioinfusion to determine suitability for derail therapeutic amnioinfusion in mid-trimester premature rupture of membranes. Fetal Diagn. Ther 2003; 18:183-189.
23. Fatima S, Tasmin N, Mahmud G. The Effect of Transabdominal Amnioinfusion on Perinatal Outcomes in Preterm Premature Rupture of Membranes. J South Asian Feder Obst Gynae 2014;6(1):28-62.
24. Garzetti G, G, Ciavattini A, De Cristofaro F, La Marca N, Arduini D: Prophylactic Transabdominal Amnioinfusion in Oligohydramnios for Preterm Premature Rupture of Membranes: Increase of Amniotic Fluid Index during Latency Period. Gynecol Obstet Invest 1997;44:249-254. doi: 10.1159/000291538.
25. Qazi M, Saqib N, Ahmed A, Wagay I. Therapeutic amnioinfusion in oligohydramnios during pregnancy (excluding labour). Int J Reprod Contracept Obstet Gynecol 2017; 6: 4577-82.
26. Locatelli A, Vergani P, Di Pirro G, Doria V, Biffi A, Ghidini A. Role of amnioinfusion in the management of premature rupture of membranes at <26weeks' gestation. Am. J. Obstet. Gynecol. 2000 Oct;183(4):878-82.

© 2020 London Journals Press

London Journal Press Membership

For Authors, subscribers, Boards and organizations

London Journals Press membership is an elite community of scholars, researchers, scientists, professionals and institutions associated with all the major disciplines. London Journals Press memberships are for individuals, research institutions, and universities. Authors, subscribers, Editorial Board members, Advisory Board members, and organizations are all part of member network.

Read more and apply for membership here:
https://journalspress.com/journals/membership

For Authors

Author Membership provide access to scientific innovation, next generation tools, access to conferences/seminars /symposiums/webinars, networking opportunities, and privileged benefits.
Authors may submit research manuscript or paper without being an existing member of LJP. Once a non-member author submits a research paper he/she becomes a part of "Provisional Author Membership".

For Institutions

Society flourish when two institutions come together." Organizations, research institutes, and universities can join LJP Subscription membership or privileged "Fellow Membership" membership facilitating researchers to publish their work with us, become peer reviewers and join us on Advisory Board.

For Subscribers

Subscribe to distinguished STM (scientific, technical, and medical) publisher. Subscription membership is available for individuals universities and institutions (print & online). Subscribers can access journals from our libraries, published in different formats like Printed Hardcopy, Interactive PDFs, EPUBs, eBooks, indexable documents and the author managed dynamic live web page articles, LaTeX, PDFs etc.

© 2020 London Journals Press

GO GREEN AND HELP
SAVE THE ENVIRONMENT

JOURNAL AVAILABLE IN

PRINTED VERSION, INTERACTIVE PDFS, EPUBS, EBOOKS, INDEXABLE DOCUMENTS AND THE AUTHOR MANAGED DYNAMIC LIVE WEB PAGE ARTICLES, LATEX, PDFS, RESTRUCTURED TEXT, TEXTILE, HTML, DOCBOOK, MEDIAWIKI MARKUP, TWIKI MARKUP, OPML, EMACS ORG-MODE & OTHER

SCAN TO KNOW MORE

support@journalspress.com
www.journalspress.com

*THIS JOURNAL SUPPORT AUGMENTED REALITY APPS AND SOFTWARES

© Copyright 2020 London Journals Press