

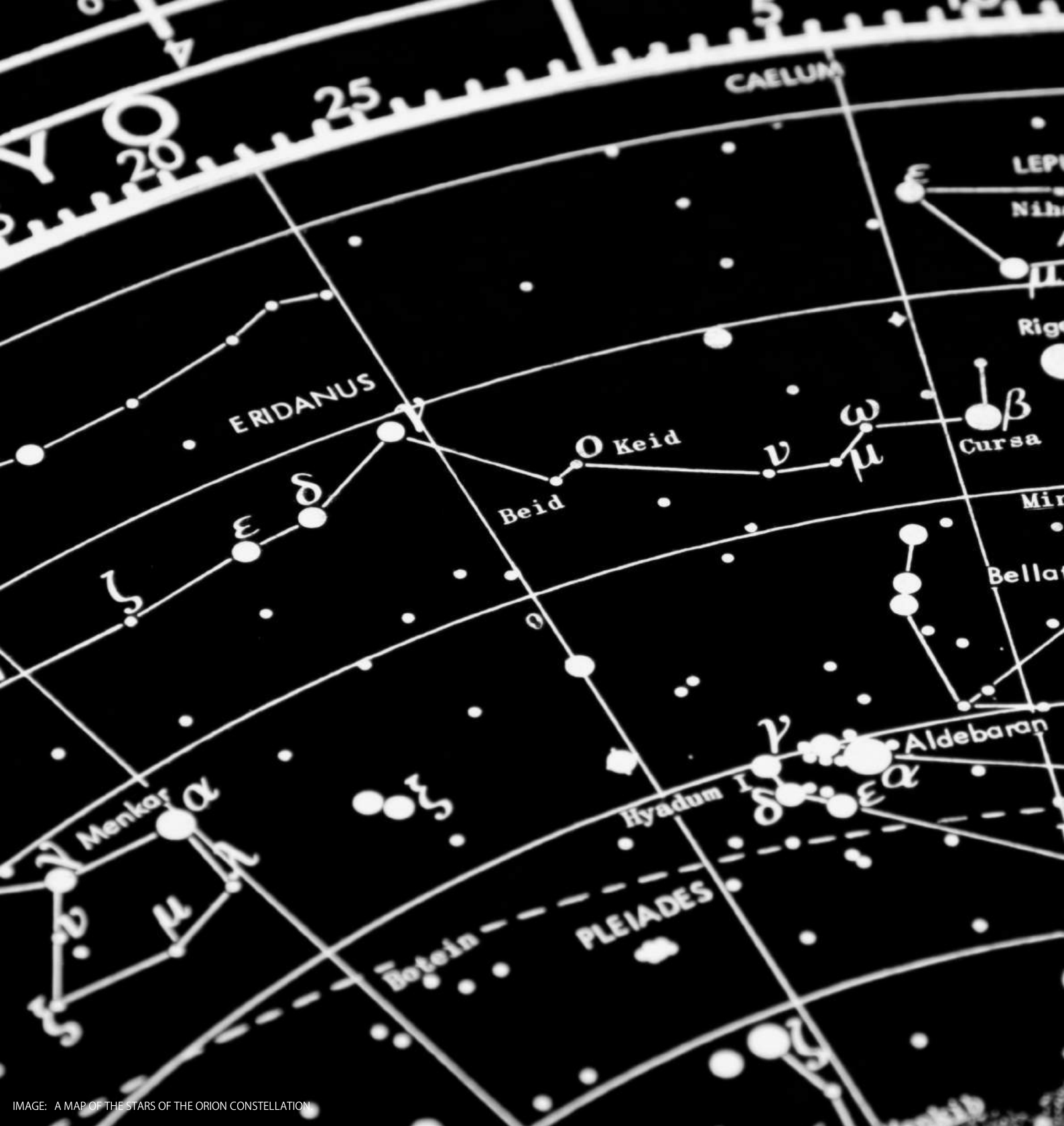

IMAGE: A MAP OF THE STARS OF THE ORION CONSTELLATION

JournalPreview

London Journal of Medical and Health Research
Volume 21 | Issue 4 | Compilation 1.0



JournalPreview

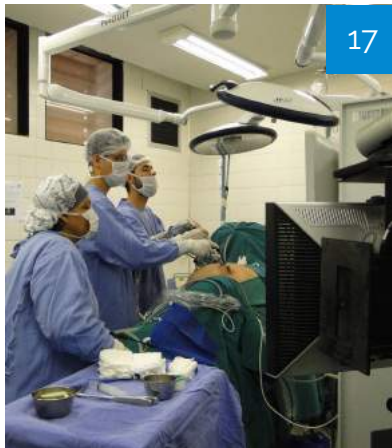London Journal of Medical and Health Research

This document is a pre-published view of London Journal of Medical and Health Research Volume 21, Issue 4 and Compilation 1.0. For any minor changes and updates kindly follow your paper's live editing URL given in sent email or get in touch with our support team at support@journalspress.com or visit our website to use live chat support. This is a beta document thus order, content or existence of papers may alter in the published eJournal.

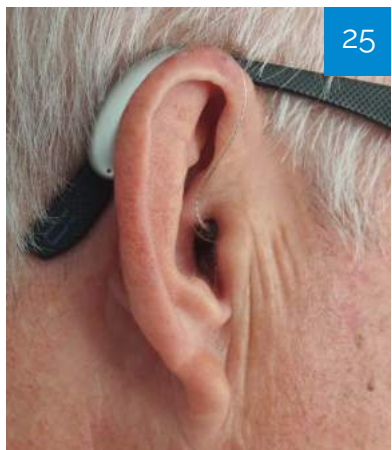
You are requested to kindly acknowledge and approve your research paper in this JournalPreview within three days.



- i. Journal introduction and copyrights
 - ii. Featured blogs and online content
 - iii. Journal content
 - iv. Editorial Board Members
-



- 1. Pancreatic Fistula Hemorrhage and Delayed Gastric...
pg. 1-16
 - 2. Total Laparoscopy Hysterectomy Our Experience at Rural...
pg. 17-24
 - 3. Comparative Study between Hearing Thresholds as...
pg. 25-32
 - 4. Hypertrophic Intracranial Pachymeningitis of a Tuberculosis Etiology...
pg. 33-44
 - 5. Non Traumatic Acute Subdural Hematoma Revealing an...
pg. 45-50
 - 6. Stereotactic Management of a Parafalcine Subdural...
pg. 51-55
-



- v. London Journals Press Memberships



Scan to know paper details and author's profile

Pancreatic Fistula Hemorrhage and Delayed Gastric Emptying: A Major Complication of Pancreaticoduodenectomy

Yehouenou Tessi Romeo Thierry, Jerguigue Hounayda, Latib Rachida & Omor Youssef

Mohamed V University

ABSTRACT

Pancreaticoduodenectomy remains a major therapy in the management of adenocarcinoma of the head of the pancreas and the biliary digestive tract tumors. Postoperative morbidity and mortality remain high. An operative mortality less than 5% in reference centers but can up to 25-50% in others hospitals. These complications are diverse, namely, early hemorrhage, which has the highest postoperative mortality rate, pancreatic fistula, which remains the feared complication, with its attendant complications, and Delayed Gastric Emptying, which remains the most frequent. The CT scan remains the gold standard for monitoring and detecting. No precise etiology could be found for these complications but some risk factors were found. The management of these complications depends on the degree of damage and the hemodynamic state of the patient. The International study group of pancreatic surgery (ISGPS) proposed a classification to harmonize the diagnosis, the degree of these complications, and the appropriate management.

Keywords: pancreaticoduodenectomy pancreatic fistula hemorrhage gastric emptying post operative complication.

Classification: NLMC CODE: WG 590

Language: English



LJP Copyright ID: 392811

London Journal of Medical and Health Research

Volume 21 | Issue 4 | Compilation 1.0



© 2021. Yehouenou Tessi Romeo Thierry, Jerguigue Hounayda, Latib Rachida, Omor Youssef. This is a research/review paper, distributed under the terms of the Creative Commons Attribution-Noncommercial 4.0 Unported License <http://creativecommons.org/licenses/by-nc/4.0/>, permitting all noncommercial use, distribution, and reproduction in any medium, provided the original work is properly cited.

Pancreatic Fistula Hemorrhage and Delayed Gastric Emptying: A Major Complication of Pancreaticoduodenectomy

Yehouenou Tessi Romeo Thierry^α, Jerguigue Hounayda^σ, Latib Rachida^ρ & Omor Youssef^ω

ABSTRACT

Pancreaticoduodenectomy remains a major therapy in the management of adenocarcinoma of the head of the pancreas and the biliary-digestive tract tumors. Postoperative morbidity and mortality remain high. An operative mortality less than 5% in reference centers but can up to 25-50% in others hospitals. These complications are diverse, namely, early hemorrhage, which has the highest postoperative mortality rate, pancreatic fistula, which remains the feared complication, with its attendant complications, and Delayed Gastric Emptying, which remains the most frequent. The CT scan remains the gold standard for monitoring and detecting. No precise etiology could be found for these complications but some risk factors were found. The management of these complications depends on the degree of damage and the hemodynamic state of the patient. The International study group of pancreatic surgery (ISGPS) proposed a classification to harmonize the diagnosis, the degree of these complications, and the appropriate management.

Keywords: pancreaticoduodenectomy-pancreatic fistula-hemorrhage-gastric emptying- post operative complication.

Author α: MD Radiology, Department of Radiology, National Institute of Oncology, UHC Ibn Sina, Mohamed V University, Rabat, Morocco.

σ: MD, Specialist in Radiology, Department of Radiology, National Institute of Oncology, UHC Ibn Sina, Mohamed V University, Rabat, Morocco.

ρ: MD, Professor, Department of Radiology, National Institute of Oncology, UHC Ibn Sina, Mohamed V University, Rabat, Morocco.

ω: MD, Professor, Department of Radiology, National Institute of Oncology, UHC Ibn Sina, Mohamed V University, Rabat, Morocco.

I. INTRODUCTION

Pancreaticoduodenectomy (PD) is an operative technique developed by Whipple in 1935 for the treatment of 3 patients with periampullary tumors [1]. The main indication is tumors of the pancreaticobiliary junction and, in order of frequency, adenocarcinoma of the head of the pancreas, ampulla of Vater, biliary and duodenal tumors. The others are chronic pancreatitis and neuroendocrine tumors. It has a high mortality and morbidity rate. It has been improved over time. It consists of resection of the duodeno - pancreatic block, ligation of the gastroduodenal artery, cholecystectomy. It will be completed by 3 types of anastomosis (figure 1) namely:

- Pancreaticojejunostomy or pancreatic - gastric anastomosis
- hepaticojejunostomy
- Gastrojejunostomy

This technique has developed considerably over time and other variants of the classic technique have been developed in order to reduce complications [2,3]. This mortality and morbidity rate is linked to postoperative complications which are dominated by hemorrhage and pancreatic fistula, which remains the most dreaded. Other complications include vascular complications (thrombosis, arteriovenous fistulas), leaks from anastomoses, biliary fistula, abscesses, Delayed Gastric Emptying, and tumor recurrence. The CT scan plays an important role in the detection of complications. It is correlated with the patient's clinical and biological data. Depending on the case, the most serious complications require a surgical revision [3].

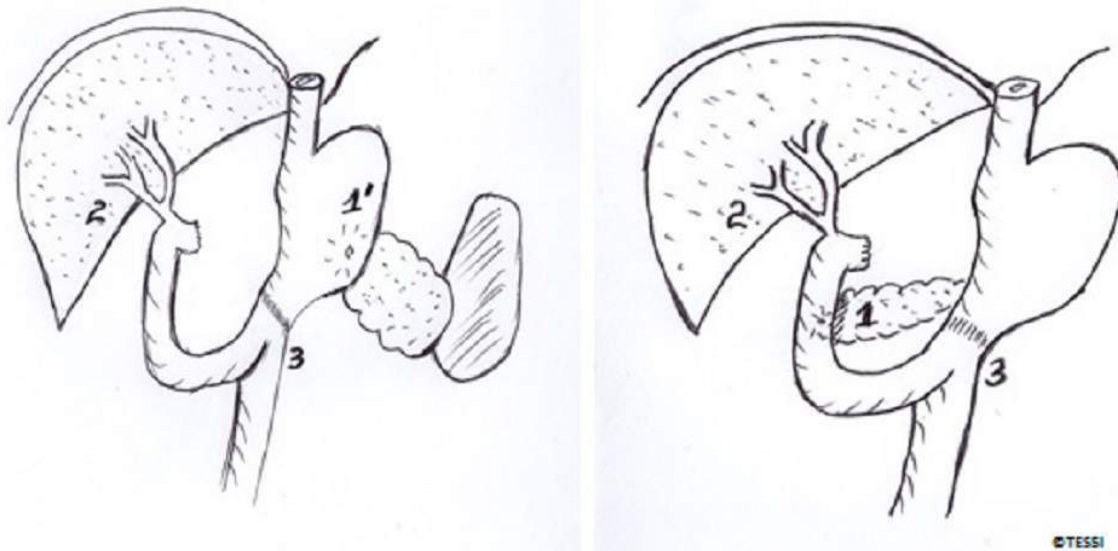


Figure 1: Figure of the anastomoses 1- Pancreatico-jejunal anastomosis 1'- Pancreatico-gastric anastomosis 2- Bilio-jejunal anastomosis 3- Gastro-jejunal anastomosis

II. MORTALITY AND MORBIDITY OF COMPLICATIONS

PD is still indicated for peri-ampullary tumors, particularly adenocarcinoma of the head of the pancreas. Curative surgical resection is the only treatment likely to bring a cure at the cost of high operative morbidity which is less than 5% in reference centers [3]. Juli Busquets et al, in a study, carried out in a specialized center, found a similar 7% postoperative mortality rate in patients with adenocarcinoma of the pancreas who had undergone PD [4]. Peterman D. et al, in a specialized center, found a rate of 6% mortality at 30 days post-op [5]. Morbidity remains high and is between 20 - 50 % depending on the definitions

used [6,7]. Mehta et al, found similar results with mortality of 2.3% and morbidity of 59% [8]. These postoperative complications are in order of frequency: Delayed Gastric Emptying, infections (intra-abdominal abscesses and wound infections), fistulas (mainly pancreatic, but also biliary and digestive), hemorrhage, pancreatitis, cholangitis and, postoperative ileus [5-7,9]. The most frequent postoperative complications of PD are delayed gastric emptying (DGE) in 20% and pancreatic fistula (PF) in 10-15% [5].

In order to standardize studies on complications, the International study group of pancreatic surgery (ISGPS) has proposed a standard classification (Table 1) [10-12]

Table 1: Major complications of duodenopancreatectomy grade (ISGPS)

NGT: Nasogastric tube		
Most common complications of duodenopancreatectomy International study group of pancreatic surgery definitions		Degrees of severity
Delayed Emptying	Gastric Inability to resume feeding (IRF) Standard at Day 7 and prolonged need for NGT	A: IRF D7 and NGT 4-7 days or reinsertion after D 3 B: IRF D14 and NGT 8-14 days or reinsertion after D7 C: IRF D21 and NGT >14 days or reinsertion after D14

Postoperative pancreatic fistula	Drainage containing > 3 x serum amylase value from D 3	A: no clinical consequences B: requires adjustment of postoperative management C: serious situation requiring heavy treatment
Hemorrhage	Can occur <24h or > 24h post-op, intraluminal or extraluminal, moderate or severe	A: <24h, intra- or extraluminal, medium severity B: <24h, intra- or extraluminal, severe severity > 24h, intra- or extraluminal, medium severity C: >24h, intra- or extraluminal, severe severity

III. CT SCAN ROLE

Imaging plays an important role in the detection of these postoperative complications, particularly CT scans, which remain the gold standard in the postoperative follow-up of patients who have undergone PD. The analysis will find the different anastomoses (Figure 2, 3, 4). In the absence of clinical signs and postoperative complications, a CT scan is performed within 3 to 6 months. The technique will be a CT scan without injection and then a CT scan injected with radiologic contrast fluid at 3 to 5ml/s speed, with an acquisition at an arterial time at 30seconds and, then a portal time between 60-90 seconds. This will be followed by multi-planar 3D reconstructions [13]. These resu-

Its must be correlated with the clinical examination and the biological work-up as appropriate. E. Cuellar et al, in a study on the contribution of CT scans in the postoperative period, noted that a systematic CT scan was performed with an average delay of 7.6 ± 0.8 days after surgery. Of the 138 CT scans analyzed, 94 (68%) were considered normal and 44 (32%) abnormal. The sensitivity of routine CT was 55% with a specificity of 75%. The positive predictive value was 39% and the negative predictive value was 85%. Routine CT scan may lead to early detection of complications in association with the presence of clinical and biological symptoms [14].

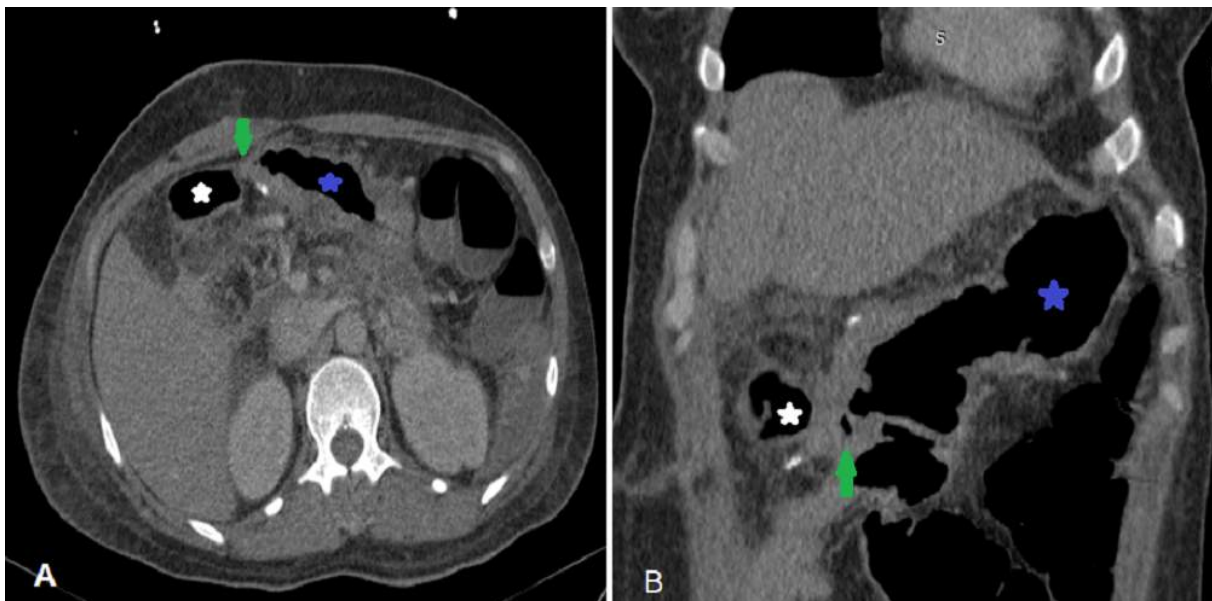


Figure 2: Non-injected abdominal and pelvic CT in axial (A) and coronal (B) sections showing the gastrojejunal anastomosis (green arrow) between the stomach (blue star) and the jejunum (white star). Note the presence of some spontaneously hyperdense clips

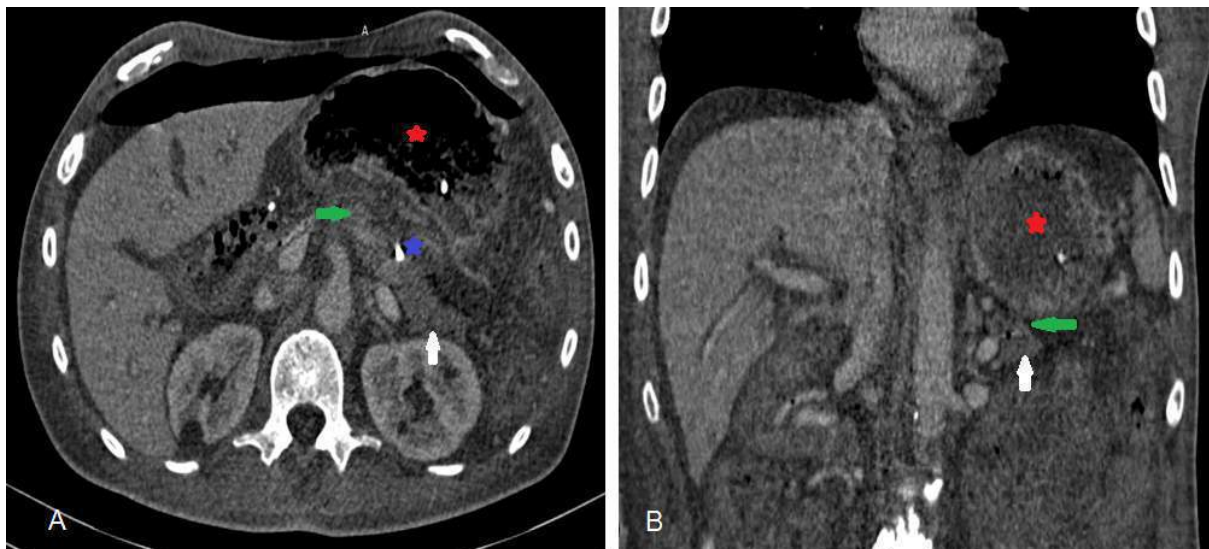


Figure 3: Non-injected abdominal and pelvic CT in axial (A) and coronal (B) sections showing the pancreatic-gastric anastomosis (green arrow) between the stomach (red star) and the residual pancreas (white arrow). Note the presence of external pancreatic stent (blue star)

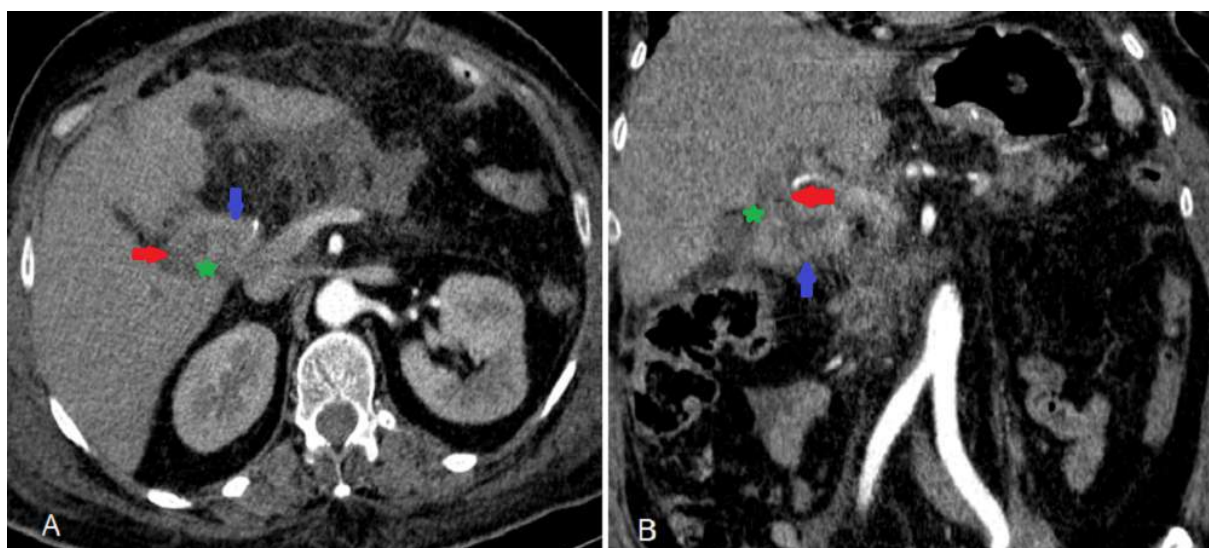


Figure 4: Abdominal and pelvic CT injected at an arterial phase in axial (A) and coronal (B) sections showing the biliary digestive anastomosis (green star) between the jejunum (blue arrow) and the residual bile duct (red arrow)

IV. POSTOPERATIVE PANCREATIC FISTULA (POPF)

4.1 Diagnosis and CT scan findings

The amylase level in fluid and/or drain is recognized as the undisputed biochemical definition of POPF, but amylase activity can range from 100 to 1000 International Units depending on glandular activity. A clinically relevant POPF is defined as a drain output of any measurable volume of fluid with amylase level greater than 3 times the upper Institutional normal serum amylase level, associated with a clinically relevant development/condition related directly to the PF [11]. The CT scan shows, the presence of air bubbles and a collection opposite the pancreatico-jejunal or pancreaticogastric anastomosis (figure 5) [13]. In a severe complications and in all patients with an aerated

peripancreatic collection on the 5th aerated peripancreatic collection had a sensitivity and a sensitivity of 25% in the detection of study by E. Cuellar et al, the presence of an of 87% postoperative day on CT, the diagnosis of POPF was confirmed [14]. Clinically, POPF should be suspected early (on postoperative day 3) based on the quality of the drainage fluid. The drain plays an important role in the diagnosis [14]. However, it must be confirmed by observation over a period of time, as postoperatively there is inflammatory serositis not related to an anastomotic leak. Indeed, it is only after clinical recovery is complete that it is possible to distinguish and classify the POPF into grades A, B, and C according to the clinical impact. The volume of fluid output over a day is relative, as demonstrated by the wide range reported in the literature [15].

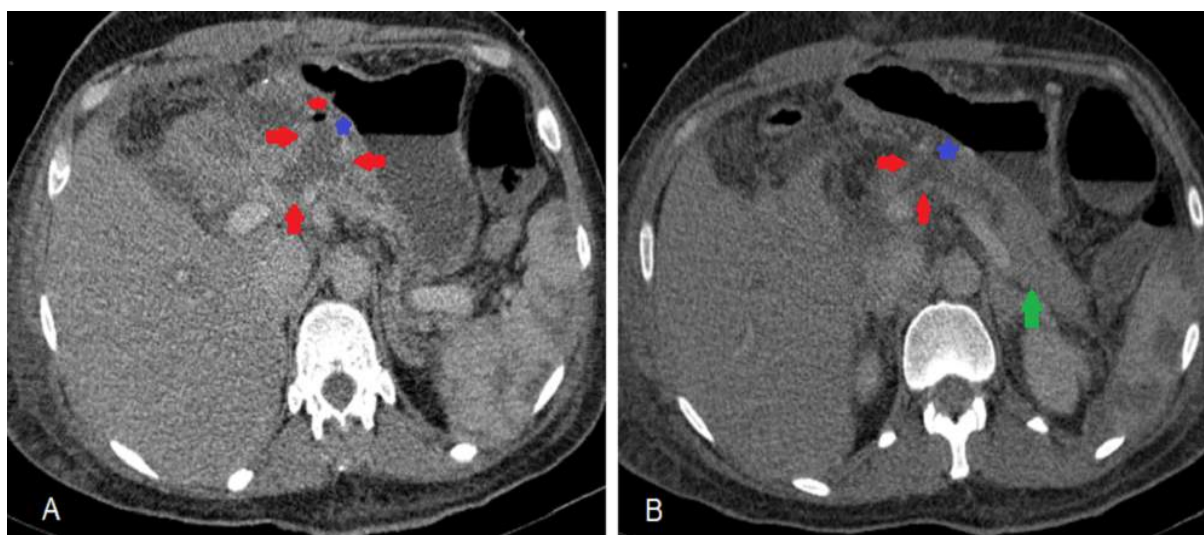


Figure 5: Abdominal and pelvic CT injected at portal phase in axial section (A and B) showing a collection (red arrow) with an air bubble (red star) opposite the pancreatic-gastric anastomosis (blue star) and the residual pancreas (green arrow) on the 5th postoperative day with a high amylase level in the drains

There are three grades of severity for pancreatic fistulas, according to The ISGPS 2016 update based on clinical, radiological, and therapeutic criteria and outcomes. (Figure 6) [11]:

- Grade A: BL (biochemical leak): Formerly grade of POPF ; a “biochemical fistula” in the literature, the BL has by definition no clinical impact. In particular, a BL implies no deviation in the normal postoperative pathway and therefore, does

not affect the normal postoperative duration of stay

- Grade B: This grade refers to a properly defined fistula involving increased amylase activity in the fluid from any drain in association with a clinically relevant condition. A grade B POPF requires a change in the management of the expected postoperative pathway.

- Grade C: Whenever a grade B POPF leads to organ failure or to clinical instability such that reoperation is needed, the POPF becomes a grade C. Often, stay in an ICU is necessary, and the hospital stay becomes excessively prolonged secondary to the POPE-related problems. For the purpose of POPF classification, postoperative organ failure is defined as the need for reintubation.

Its incidence is approximately 8-25% in patients after PD following pancreatic anastomotic release or fistula. The correlation of the diagnosis of POPF with CT data is important and the diagnosis is based mainly on clinical and biological data [16]. The experiences of Lahey and Mayo Clinics found an incidence of 8% in 403 post-PD patients with direct mortality of approximately 26% [18,19].

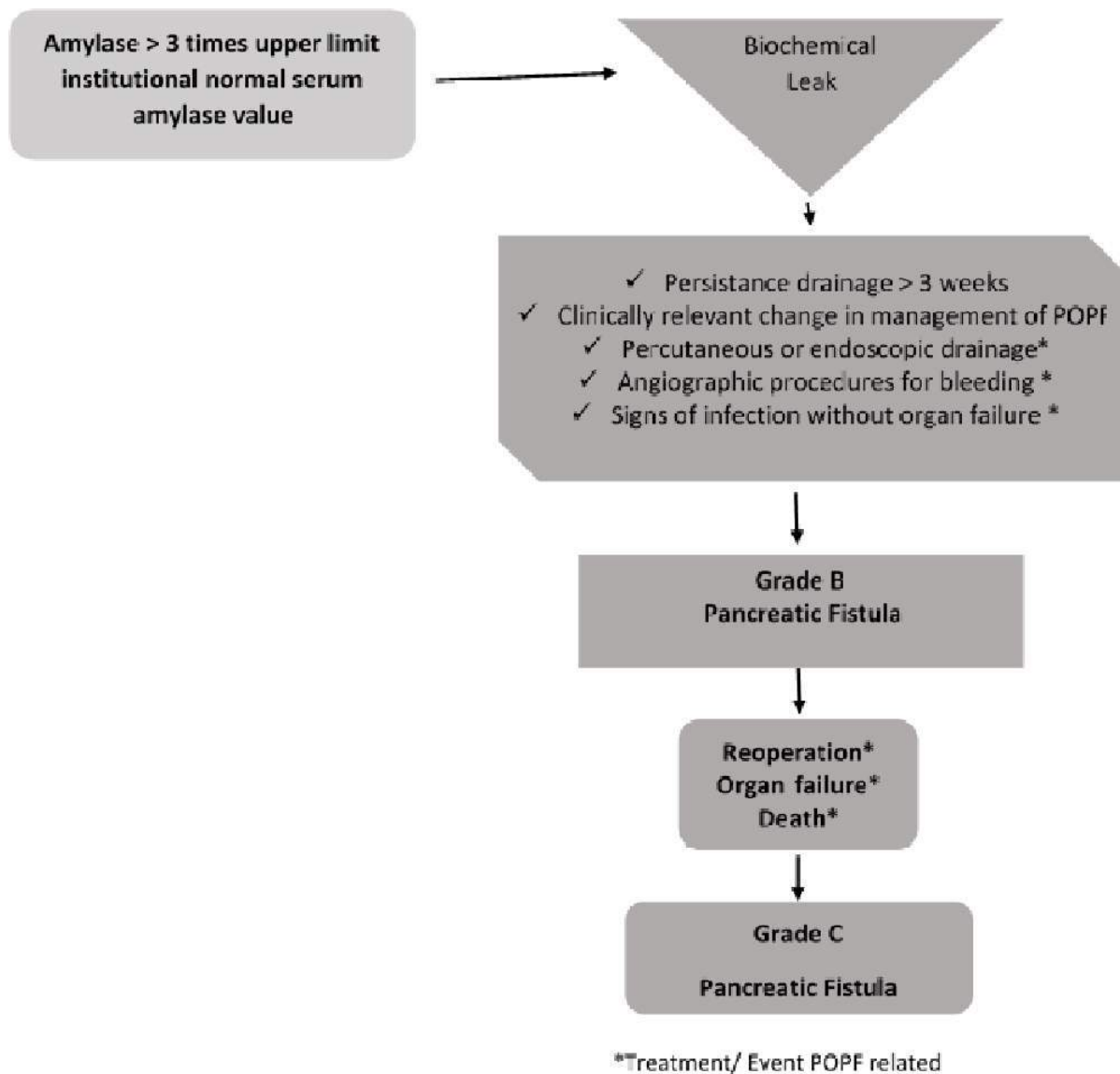


Figure 6: Algorithm for biochemically leak and Postoperative pancreatic Fistula definition. The 2016 update of the International Study Group (ISGPS)

4.2 Risk Factors For Pancreatic Fistula

Many risk factors have been identified for the occurrence of POPF. For F-H Liu, the size of the main pancreatic duct is a predictive factor for the occurrence of pancreatic fistula [20]. Other autho-

rs recognize the important role of the preoperative CT scan in predicting the occurrence of POPF, notably by measuring the density of the pancreatic parenchyma, the smaller diameter < 3mm of the duct of Wirsung, which has a good prognosis

[21,22]. Fibrosis leads to hardening of the pancreas and rigidity of the pancreatic duct, which reduces the risk of postoperative POPF [23].

Some authors blame the decrease in serum albumin postoperatively as a factor in the occurrence of POPF. Fujiwara et al, suggests that the decrease in albumin in the postoperative period is at the origin of a decrease in the systemic anti-inflammatory response, which leads to an immunonutritional disorder, thus increasing the risk of the occurrence of POPF [24]. For Utsumi et al, the improved nutritional state of the patient allows him/her to better cope with the risk of postoperative POPF [25].

Management of the fistula depends on the degree of severity. Nutritional measures, empirical antibiotic therapy, percutaneous drainage, and octreotide treatment are discussed. Surgical revision is only performed in cases of severe loosening or dehiscence of the anastomosis [13,26]. In a study by C.J. Yeo, approximately 15% of patients received percutaneous drainage, 80% conservative measures, and 5% revision surgery [17]. Bassi C et al found a similar rate of revision surgery in POPF of 3% [27]. For Busquets J et al, in one study POPF was not a risk factor for death post PD surgery [4]. A meta-analysis of English reviews by Pedrazzoli S. of 60,739 patients who underwent PD from 1990-2015 on the relationship between POPF mortality found only 1% mortality due to PD [28]. In a study by Shukla et al, In a two-year multicenter study of 718 cases of PD, POPF accounted for 17% of complications (77% grade A and B), there was clearly no significant association between postoperative mortality and POPF [29]. The use of three drains at the operative site in PD would also play an essential role in reducing complications, particularly POPF. This number varies according to the surgeon's habits and technique but on average between 2 and 3 drains are used in the study by Shukla et al. in the different centers [29]. Colon K et al, in a randomized study on the efficacy of aspiration drainage (external suction system via central suction or electric pump) in the occurrence of postoperative complications and mortality, didn't show the impact of aspiration drainage in

reducing POPF or post-operative mortality. As a result, aspiration drainage is not recommended in PD and its place remains to be determined [30].

Other authors have attempted to demonstrate the occurrence of POPF according to the type of pancreatico-jejunal or pancreatico-gastric anastomosis. Shukla et al, in their study of 718 patients who underwent PD, a majority of pancreatico-jejunal anastomosis in 491 patients (68.3%) versus 227 (31%) pancreatico-gastric anastomosis showed no statistically significant benefit in preventing PF [29]. Randomized studies have also failed to show any statistical difference in the prevention of POPF by the different anastomoses [12,27].

4.3 *The place of somatostatins and derivatives*

The use of octreotide remains controversial. Its inhibitory property on pancreatic hormone secretion has been proposed in order to limit the occurrence of fistula. In the various comparative studies, its effectiveness has not been proven. Its routine use should be limited to centers where the fistula rate is >10%, a residual pancreas remains friable or a Wirsung duct >3mm [3, 31, 32]. C.J. Yeo's experience with the use of octreotide has been inconclusive [17]. Randomized controlled trials in Europe and the United States have shown no benefit from the use of octreotide in the prevention of POPF [33,34]. The same is true in Predrazzoli's meta-analysis of 60,739 patients, which also failed to find a proven beneficial effect of somatostatin and its various analogs (Octreotide, Vapreotide.....), with no statistical difference in the impact on the incidence and mortality of POPF [28].

4.4 *Intubation of the pancreatic duct (Figure 7)*

Other authors have studied the impact of stenting during PD. Roder J et al, in a study of 41 patients, reported that the rate of occurrence of POPF in the group of patients without pancreatic duct stenting was 6.8% compared to 29.3% in patients with pancreatic duct intubation, suggesting an increased risk of fistula in patients with pancreatic duct intubation, which calls into question this method [35].

In the meta-analysis by Pedrazzoli S, there was no significant difference between non-stented (pancreatic duct), external stent, and internal pancreatic duct stent patients with respect to POPF mortality and overall PD mortality. No conclusion could be drawn from this analysis regarding the impact of stenting on PD [28]. A meta-analysis by Dong Z et al, on 1018 patients, notes that external

stenting may have a beneficial effect in preventing POPF and reducing the length of hospital stay for patients, but due to low statistical evidence, the benefit between no stenting, and external or internal stenting remains uncertain. Therefore, a rigorous randomized trial is needed to reach a reliable conclusion [36].

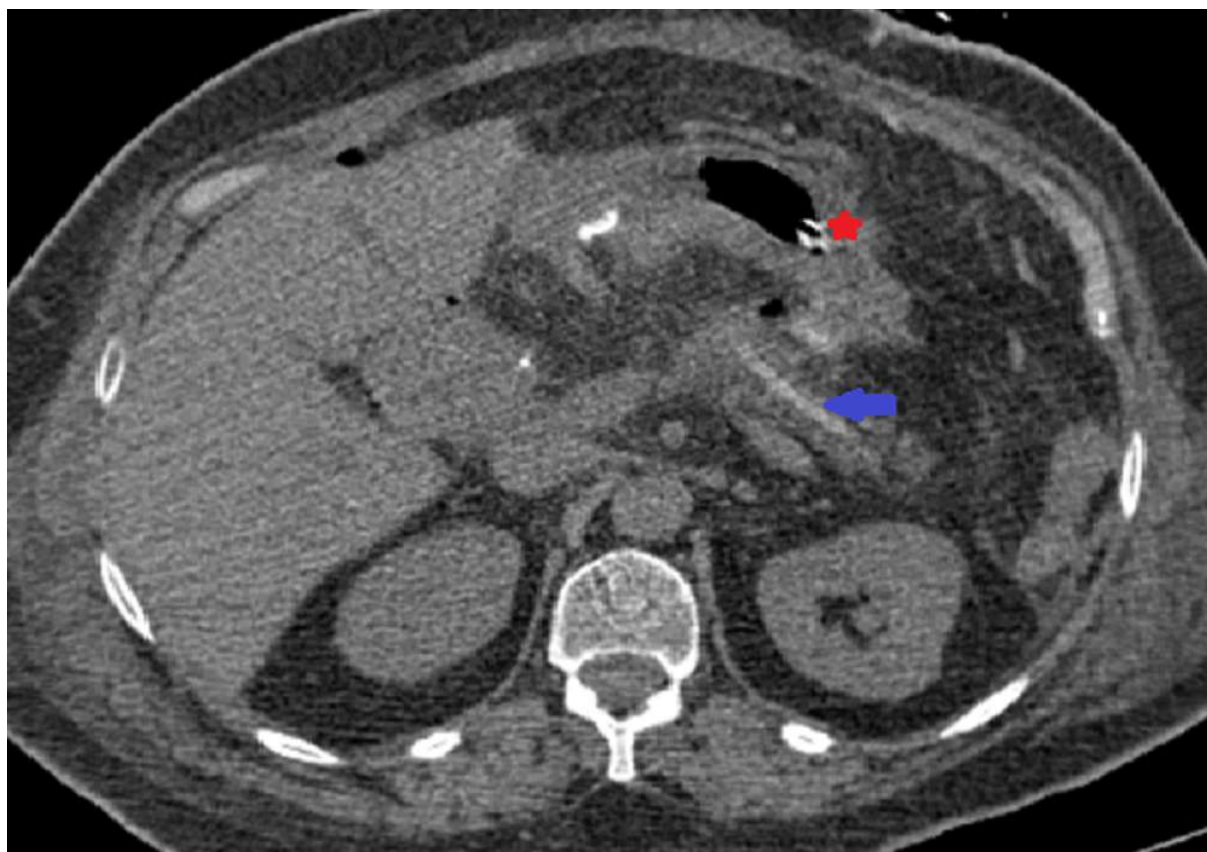


Figure 7: Non-injected abdominal and pelvic CT showing an internal stent (blue arrow) of the residual pancreas postoperatively. Note the presence of a nasogastric tube (red star)

V. POSTOPERATIVE HEMORRHAGE

Postoperative hemorrhage is defined as intra- or extraluminal bleeding, early if it occurs within 24 hours of surgery or late otherwise [10]. The severity of bleeding is classified into three groups according to the ISGPS: moderate severity bleeding (group A) if medical treatment alone is sufficient, severity bleeding if intervention is required (group B) or if the patient is in shock (group C)(Table 1). Sentinel hemorrhage is defined as the presence of a small amount of blood in the drains or in the nasogastric tube (NGT) [15, 37, 38]. It remains a rare complication of PD, but with a high

mortality rate. Shukla P et al. found an incidence of 6% in the postoperative complications of PD [29]. Jacquemin found in his study of 194 postoperative PD patients over a period of three years, an incidence of 17.5% (34/194) with a high 90-day mortality rate of 17.6% (6/34) [37]. Raman et al. in their study reported an incidence of 4% with a high mortality rate of 38% [39,40].

These hemorrhages can be subdivided into two groups: early hemorrhages in the first 24 hours most often related to bleeding from the stump of the gastroduodenal artery (Figure 8) due to a ligation defect. Late hemorrhage generally occurs

on the 5th postoperative day in relation to a vascular anomaly involving the mesenteric vessels, or an erosion of the hepatic artery, the celiac trunk, the splenic artery, but also a pseudoaneurysm of the stump of the gastroduodenal artery [13, 39, 40]. This hemorrhage can be externalized by the intraluminal digestive route in the form of hematemesis or melena or extraluminal via the drains. Jacquemin M. found that in 65% (n=22/34) of cases, the bleeding was externalized by the

drains, 38% (n=13/34) by the digestive tract, 18% by hematemesis or by the presence of blood in the NGT (n=6/34) and 21% by melena. Bleeding was externalized through the drains in 63.2% (n=12/19) of cases and through the gastrointestinal tract in 42.1% (n=8/19). In total, 55% (n=19) of the patients presented a sentinel hemorrhage. It preceded 37.5% (n=6/16) of arterial bleeds, 100% (n=4/4) of venous bleeds and 43% (n=6/14) of anastomotic bleeds [37].

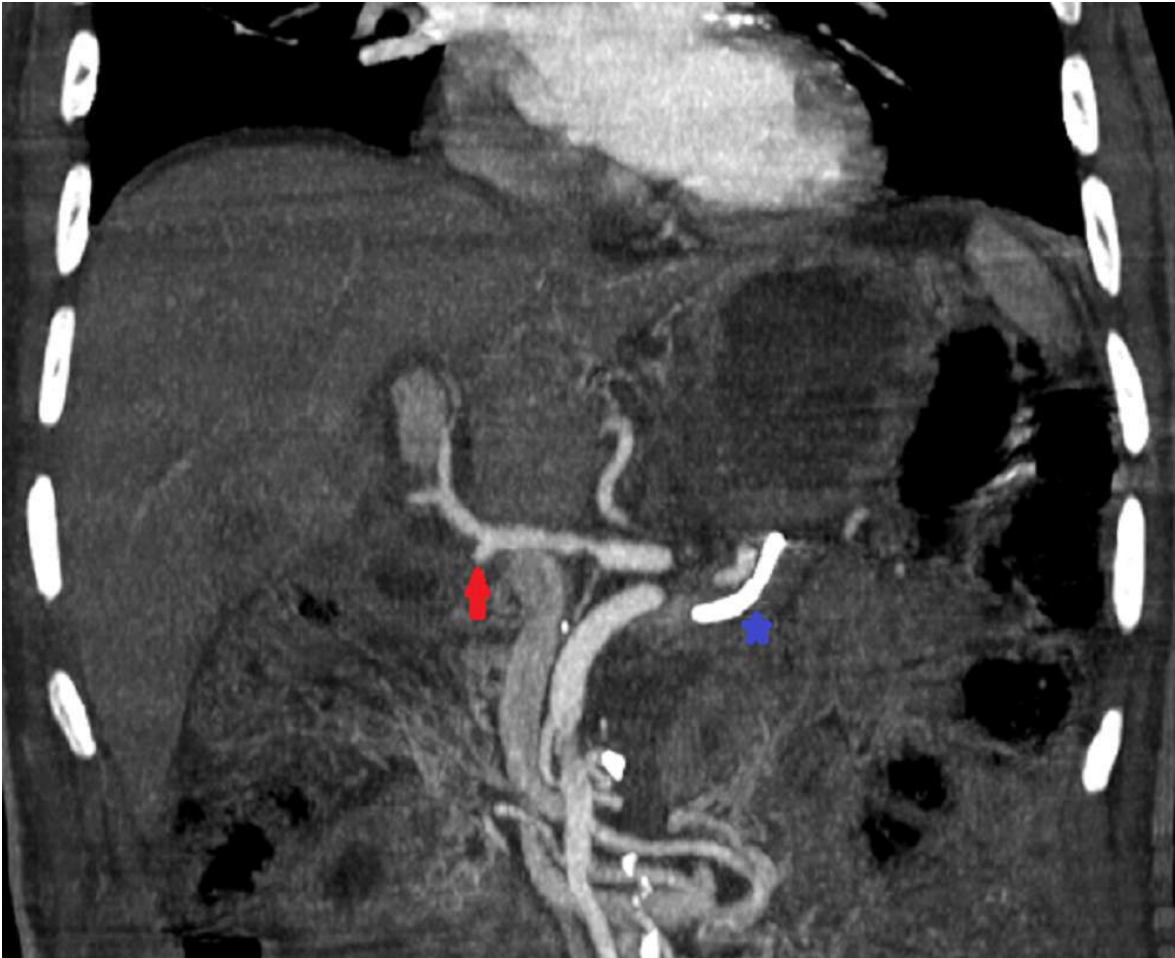

Figure 8: Abdominal and pelvic CT scan injected at the arterial phase showing the stump of the gastroduodenal artery without any anomaly (red arrow) postoperatively. Note the presence of a clip (blue star)

5.1 Imagery

The CT scan remains a means of diagnosis, especially at the arterial stage, except in cases of hemodynamic instability of patients. It highlights spontaneous hyperdensity in relation to the vessels or the surgical site or extravasation of contrast product; a pseudoaneurysm or a vascular

anomaly may be detected at a later stage and will guide the angiography for good identification of the surgical site [40].

In a study by Wolk on the management of post-PD bleeding, a CT scan was performed in 83% of cases before endovascular treatment, the bleeding

sites involved in most cases were the hepatic artery 19,2% (10 cases), the stump of the gastroduodenal artery 36.5% (19 cases), followed by the splenic artery 15.4% (7 cases), the celiac trunk 11.5% (6 cases), the dorsal pancreatic artery 1.9% (1 case), and the inferior pancreaticoduodenal artery 1.9% (1 case) [41].

5.2 Risk factors

Certain factors would be linked to the occurrence of early or late postoperative hemorrhage, namely, POPF, followed by abdominal infections [37, 42]. The explanation would be the erosion of the vascular walls, weakening of the anastomoses by abdominal infection, by lytic pancreatic juice; it should be noted that aneurysm formation would also play a large role in the occurrence of these hemorrhages [37,42].

5.3 Treatment

Management depends on the hemodynamic status and the cause of the hemorrhage. In the case of hemodynamic stability and arterial hemorrhage, the first-line treatment is angiography. The artery involved may be embolised or a stent placed [43]. Yekebas EF et al, in a series of 1669 pancreatic resections, recommended angiography for sentinel hemorrhage because of its association with the arterial origin [44]. If these procedures fail, a second attempt to avoid repeat surgery may be considered with a high excess mortality rate due to surgical site inflammation, adhesions, and tissue friability [45]. For intraluminal hemorrhage, digestive endoscopy is of great interest. In the case of pseudoaneurysms, angiography shows better efficacy and good prevention of aneurysmal rupture [46]. The current treatment of pseudoaneurysms is based on radiological embolization using coils. Surgical revision is technically difficult, exposes a high risk of bleeding, and may result in the completion of pancreatectomy with the consequence of diabetes that is difficult to control. Radiological embolization is less burdensome for the patient and its effectiveness is between 63% and 100% [46-49].

VI. DELAYED GASTRIC EMPTYING

Delayed Gastric Emptying (DGE) is defined as failure to resume normal feeding by the end of the first postoperative week, with prolonged maintenance of a nasogastric tube aspiration or its reintroduction. It accounted for approximately 19-57% of the patients operated on [5]. It remains the most frequent complication of PD with an incidence varying between 14-36% for Sastre B. et al [3]. Sakamoto et al, in a study of 387 postoperative patients with PD, found a similar rate of 38% [50]. Its mechanism is multifactorial and remains poorly understood. It is thought to be secondary to a disturbance of gastric innervation secondary to surgery. For Kunstman JW et al, the occurrence of other complications at the surgical site could also explain this DGE, notably POPF, abscesses, and severe blood loss during the operation [51]. Another factor is gastric atony on the one hand in response to the reduction of motilin levels in circulation and on the other hand the resection of the duodenal stimulator and the disturbance of gastroduodenal innervation [52, 53].

The CT scan remains an excellent diagnostic tool for the visualization of gastric distension with stasis [14] (Figure 9).

The ISGPS proposes a classification based on the inability to resume feeding a standard diet (IRF) on the 7th postoperative day and the prolonged need for a nasogastric tube. It recognizes three levels of severity A, B, and C (Table 1).

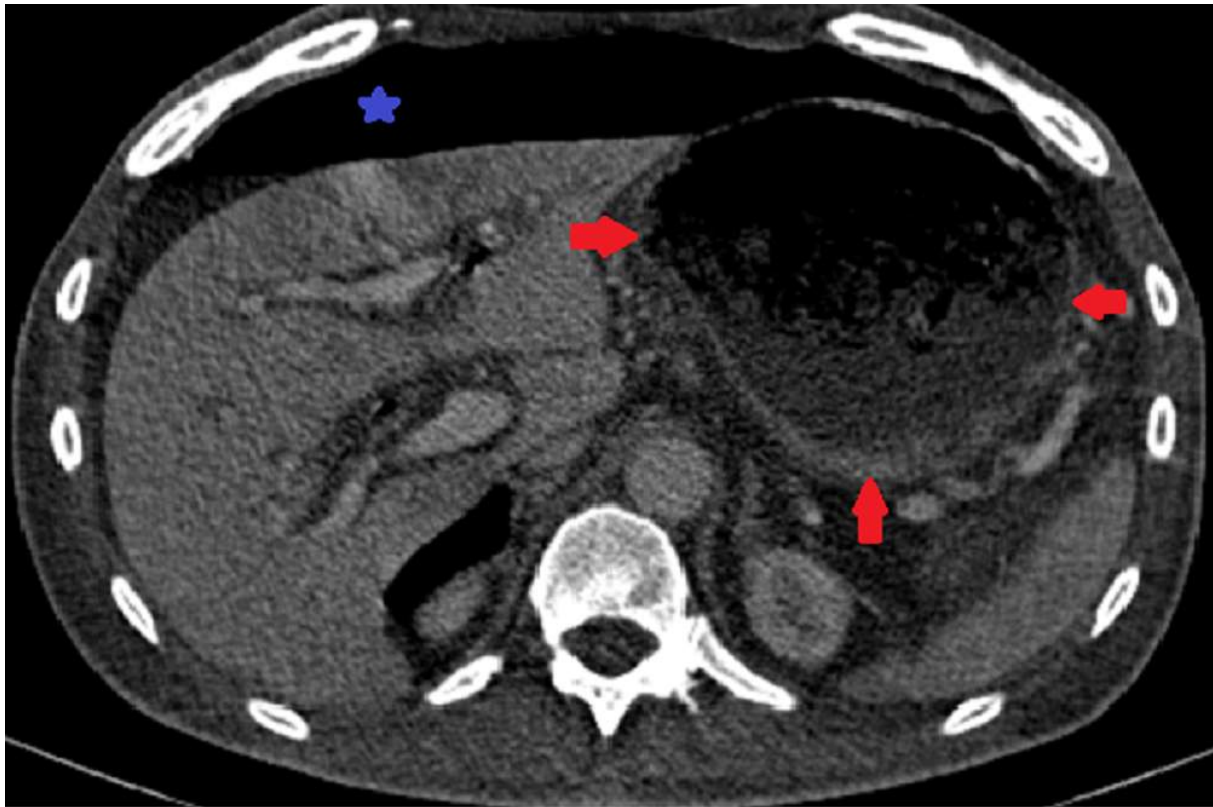


Figure 9: Abdominal and pelvic CT injected at the portal phase in axial section showing a stasis stomach (red arrow) in a patient on the 7th postoperative day who presented with intermittent vomiting. Note a postoperative pneumoperitoneum (blue star)

VII. THE PLACE OF ERYTHROMYCIN

Erythromycin is thought to play a role in the early resumption of feeding postoperatively, thus reducing the rate of DGE. Yeo et al, in a study of 118 patients divided into two groups: group 1 receiving erythromycin and the other saline: the results show an early resumption of feeding in group 1 and a reduction in the occurrence of DGE to 19% in group 1 and 30% in group 2. Therefore, He concluded that erythromycin accelerated gastric emptying and reduced the rate of postoperative gastroparesis [54]. Ohwadda et al. found similar results for the use of erythromycin postoperatively in the early resumption of gastric emptying and reduction of DGE rates [55].

VIII. CONCLUSION

Pancreaticoduodenectomy remains an operative technique in the management of tumors of the bilio-pancreatic crossroads. It remains fraught with complications, the most prominent of which are hemorrhage with a high mortality rate, very

frequent delayed gastric emptying, and pancreatic fistula which remains a dreaded complication. Other complications are also observed, notably infections/abscesses, vascular complications, anastomosis loosening and later recurrence, and others.

The CT scan remains an excellent imaging tool for post-operative follow-up and for detecting various complications. These data must be associated with the patient's clinical condition and the biological assessment.

Several factors have been identified in the occurrence of these major complications including pancreatic fistula. These factors require further study to provide statistically proven results for a reduction in postoperative mortality and morbidity.

IX. DISCLOSURES

Data Availability: The data used to support the findings of this study are included within the article.

Conflicts of interest: In compliance with the ICMJE uniform disclosure form, all authors declare the following: **Payment/services info:** All authors have declared that no financial support was received from any organization for the submitted work.

Funding statement: All authors have declared that they have no financial relationships at present or within the previous three years with any organizations that might have an interest in the submitted work.

Other relationships: All authors have declared that there are no other relationships or activities that could appear to have influenced the submitted work.

RÉFÉRENCES

- Whipple A. Treatment of carcinoma of ampulla of Vater. *Ann Surg* 1935;102:763–79. DOI: 10.1097/00000658-193510000-00023
- Baumel H, Hugiuer M, Manderscheid J, Fabre J, Houry S, Fagot H. Results of resection for cancer of exocrine pancreas : a study from the French Association of Surgery. *Br J Surg* 1994; 81:102–7. 10.1002/bjs.1800810138
- Sastre B, Ouassi M, Pirro N, Cosentino B, Sielezneff I et al. La duodéno pancréatectomie céphalique à l'ère de la médecine factuelle. *Annales de chirurgie* 130 (2005) 295–302. 10.1016/j.anchir.2004.12.005.
- Juli Busquets, Juan Fabregata, Rosa Jorbaa, Nuria Pelaez, Francisco Garcia-Borobias et al. *CIR. ESP.* 2010;88(5) :299–307. 10.1016/j.cir-esp.2010.05.006
- Petermann D, Ksontini R, Halkic N, Demartines N. Duodéno pancréatectomie céphalique : indications, résultats et prise en charge des complications *Rev Med Suisse* 2008 ; 4 : 1563-6.
- Yeo CJ, Cameron JL, Lillemoe KD, et al. Six hundred fifty consecutive pancreaticoduodenectomies in the 1990s. Pathology, complication, and outcomes. *Ann Surg* 1997;226: 248-60.10.1097/00000658-199709000-00004.
- Yeo CJ, Cameron JL, Lillemoe KD, et al. Pancreaticoduodenectomy with or without distal gastrectomy and extended retroperitoneal lymphadenectomy for periampullary adenocarcinoma, part 2: Randomized controlled trial evaluating survival, morbidity, and mortality. *Ann Surg* 2002;236:355-68. 10.1097/00000658-200209000-00012.
- Mehta VV, Fisher SB, Maithel SK, et al. Is it time to abandon routine operative drain use? A single institution assessment of 709 consecutive pancreaticoduodenectomies. *J Am Coll Surg* 2013;216(4):635-42.10.1016/j.jamcollsurg.2012.12.040.
- Büchler MW, Wagner M, Schmied BM, et al. Changes in morbidity after pancreatic resection. Toward the end of completion pancreatectomy. *Arch Surg* 2003; 138:1310-4. 10.1001/archsurg.138.12.1310.
- Wente MN, Bassi C, Dervenis C, et al. Delayed gastric emptying (DGE) after pancreatic surgery : A suggested definition by the International group of pancreatic surgery (ISGPS). *Surgery* 2007;142:761-8. 10.1016/j.surg.2007.05.005.
- Bassi C, Marchegiani G, Dervenis C, Sarr M, Abu Hilal M, Adham M, et al, International Study Group on Pancreatic Surgery (ISGPS). The 2016 update of the International Study Group (ISGPS) definition and grading of postoperative pancreatic fistula: 11 Years After. *Surgery.* 2017 Mar;161 (3): 584-591.10.1016/j.surg.2016.11.014.
- Wente MN, Veit JA, Bassi C, et al. Postpancreatectomy hemorrhage (PPH) – an international group of pancreatic surgery (ISGPS) definition. *Surgery* 2007: 142:20-5. 10.1016/j.surg.2007.02.001.
- Raman S P, Horton K M, Cameron J L, Fishman E K. CT After Pancreaticoduodenectomy: Spectrum of Normal Findings and Complications. *AJR* 2013; 201:2–13. 10.2214/AJR.12.9647.
- Cuellara E, Muscaria F, Tuyerasa G, Maulata C, Charrière B, Duffasa J.-P, et al. Use of routine CT-Scans to detect severe postoperative complications after pancreato-duode-

- nectomy, *Journal of Visceral Surgery*, 2018 ; 155 (5) 375-382. 10.1016/j.jviscsurg.2017.12.007.
15. Sato N, Yamaguchi K, Chijiwa K, Tanaka M. Risk analysis of pancreatic fistula after pancreatic head resection. *Arch Surg* 1998;33: 1094-8. 10.1001/archsurg.133.10.1094.
 16. Kim WS, Choi DW, Choi SH, et al. Clinical validation of the ISGPF classification and the risk factors of pancreatic fistula formation following duct-to-mucosa pancreatico-jejuno stomy by one surgeon at a single center. *J Gastrointest Surg*, 2011;15:2187-92. 10.1007/s11605-011-1726-0.
 17. Charles J. Yeo, Management of complications following pancreaticoduodenectomy. *Surgical clinics of north america* 1995 : 75 (5) 912-923. 10.1016/s0039-6109(16)46736-8
 18. Braasch JW, Gray BN: Considerations that lower pancreaticoduodenectomy mortality. *Am J Surg* 133:480-484, 1977. 10.1016/0002-9610(77)90135-0.
 19. Edis AI, Kiernan PD, Taylor WF: Attempted curative resection of ductal carcinoma of the pancreas. Review of Mayo Clinic experiences, 1951-1975. *Mayo Clin Proc* 55:531-536, 1980
 20. Liu F.-H, Xiao-Zhong Jiang, Bin Huang, Yu Yu. Predictor of biochemical leak to grade B postoperative pancreatic fistula. *Med Sci Monit*, 2021; 27: e928489. 10.12659/MSM.928489.
 21. Roberts KJ, Storey R, Hodson J, et al. Pre-operative prediction of pancreatic fistula: Is it possible? *Pancreatology*, 2013;13:423-28. 10.1016/j.pan.2013.04.322.
 22. Frozanpor F, Loizou L, Ansorge C, et al. Correlation between preoperative imaging and intraoperative risk assessment in the prediction of postoperative pancreatic fistula following pancreatoduodenectomy. *World J Surg*, 2014;38:2422-29. 10.1007/s00268-014-2556-5
 23. Hong TH, Choi JI, Park MY, et al. Pancreatic hardness: Correlation of surgeon's palpation, durometer measurement and preoperative magnetic resonance imaging features. *World J Gastroenterol*, 2017;23:2044-51. 10.3748/wjg.v23.i11.2044.
 24. Fujiwara Y, Shiba H, Shirai Y, et al. Perioperative serum albumin correlates with postoperative pancreatic fistula after pancreaticoduodenectomy. *Anticancer Res*, 2015;35: 499-503.
 25. Utsumi M, Aoki H, Nagahisa S, et al. Preoperative predictive factors of pancreatic fistula after pancreaticoduodenectomy: Usefulness of the CONUT score. *Ann Surg Treat Res*, 2020;99(1):18-25. 10.4174/astr.2020.99.1.18.
 26. Oneil Machado N. Pancreatic fistula after pancreatectomy: definitions, risk factors, preventive measures, and management—review. *Int J Surg Oncol* 2012; 2012:602478. 10.1155/2012/602478.
 27. Bassi C, Falconi M et al. Management of Complications after Pancreaticoduodenectomy in a High Volume Centre: Results on 150 Consecutive Patients. *Dig Surg* 2001;18: 453–458. 10.1159/000050193.
 28. Pedrazzoli S, Pancreatoduodenectomy (PD) and postoperative pancreatic fistula (POPF) A systematic review and analysis of the POPF-related mortality rate in 60,739 patients retrieved from the English literature published between 1990 and 2015. *Pedrazzoli Medicine* (2017) 96:19.10.1097/MD.0000000000006858.
 29. Shukla P.J., Barreto S.G. et al. Peri - operative outcomes for pancreatoduodenectomy in India: a multi - centric study. *International Hepato-Pancreato-Biliary Association (HPB)* 2009 : 11, 638–644. 10.1111/j.1477-25742009.00105.x.
 30. Conlon K, Labow D, Leung D, Smith A, Jarnagin W, Coit D, et al. Prospective randomized clinical trial of value of intraperitoneal drainage after pancreatic resection. *Ann Surg* 2001;234:487–94. 10.1097/00000658-200110000-0000.
 31. Friess HSBH, Sulkowski U, Becker H, Hofbauer B, Dennler HJ, Buchler MW, et al. Randomized controlled multicentre study of the prevention of complications by octreotide in patients undergoing surgery for chronic pancreatitis. *Br J Surg* 1995;82:1270–3.10.1002/bjs.1800820938.

32. Stojadinovic A, Brooks A, Hoos A, Jacques D, Colon K, Brennan M. An evidence-based approach to the surgical management of resectable pancreatic adenocarcinoma. *J Am Coll Surg* 2003;196:954–64.10.1016/S1072-7515(03)00010-3.
33. Suc B, Msika S, Piccinini M, Fourtanier G, Hay JM, Flamant Y et al. Octreotide in the prevention of intra-abdominal complications following elective pancreatic resection: a prospective, multicenter randomized controlled trial. *Arch Surg* 2004 ; 139:288–294. 10.1001/archsurg.139.3.288.
34. Yeo CJ, Cameron JL, Lillemoe KD, Sauter PK, Coleman J, Sohn TA et al. Does prophylactic octreotide decrease the rates of pancreatic-fistula and other complications after pancreaticoduodenectomy? Results of a prospective randomized placebo-controlled trial. *Ann Surg* 2000 ; 232:419–429. 10.1097/00000658-200009000-00014.
35. Roder J, Stein H, Böttcher K, Busch R, Heidecke CD, Siewert JR. Stented vs nonstented pancreaticojejunostomy. A prospective study. *Ann Surg* 1999;229:41–8. 10.1097/0000658-199901000-00005.
36. Dong Z, Xu J, Wang Z, Petrov MS. Stents for the prevention of pancreatic fistula following pancreaticoduodenectomy. *Cochrane Database of Systematic Reviews* 2016, Issue 5. Art. No.: CD008914.10.1002/14651858.CD008914.pub3.
37. Mathieu Jacquemin. Duodéno pancréatectomie céphalique: incidence, facteurs de risque et prise en charge de complications hémorragiques. *Sciences du Vivant [q-bio]*.2021. Dumas-03190630
38. Brodsky JT, Turnbull AD. Arterial hemorrhage after pancreatoduodenectomy. The « sentinel bleed ». *Arch Surg Chic Ill* 1960. août 1991;126(8):1037-40.10.1001/archsurg.1991.01410320127019
39. Limongelli P, Khorsandi SE, Pai M, et al. Management of delayed postoperative hemorrhage after pancreaticoduodenectomy: a meta-analysis. *Arch Surg* 2008; 143:1001–1007.10.1001/archsurg.143.10.1001.
40. Puppala S, Patel J, McPherson S, Nicholson A, Kessel D. Hemorrhagic complications after Whipple surgery. *AJR* 2011; 196:192–197. 10.2214/AJR.10.4727
41. Wolk S., Radosa C.G. et al.: Risk Factors for In-hospital Mortality After Transarterial Intervention After Postpancreatectomy Hemorrhage. *Cardiovasc Intervent Radiol* (2020) 43:1342–1352. 10.1007/s00270-020-02509-2
42. Feng F, Cao X, Liu X, Qin J, Xing Z, Duan J, et al. Two forms of one complication: Late erosive and nonerosive postpancreatectomy hemorrhage following laparoscopic pancreaticoduodenectomy. *Medicine (Baltimore)*. juill 2019;98(30):e16394. 10.1097/MD.00000000000016394.
43. Linke GR, Mieth M, Hofer S, Trierweiler-Hauke B, Weitz J, Martin E, et al. Surgical intensive care unit - essential for good outcome in major abdominal surgery? *Langenbecks Arch Surg*. avr 2011;396(4):417-28. 10.1007/s00423-011-0758-y.
44. Yekebas EF, Wolfram L, Cataldegirmen G, Habermann CR, Bogoevski D, Koenig AM, et al. Postpancreatectomy hemorrhage: diagnosis and treatment: an analysis in 1669 consecutive pancreatic resections. *Ann Surg*. août 2007;246(2):269-80.10.1097/01.sla.0000262953.77735.db.
45. Ding X, Zhu J, Zhu M, Li C, Jian W, Jiang J, et al. Therapeutic management of hemorrhage from visceral artery pseudoaneurysms after pancreatic surgery. *J Gastrointest Surg Off J Soc Surg Aliment Tract*. août 2011;15 (8):1417-25. 10.1007/s11605-011-1561-3.
46. Vibert E. et al. Rupture of a jejunal artery pseudo-aneurysm after Whipple procedure. *Annales de chirurgie* 128 (2003) 626–629. 10.1016/j.anchir.2003.09.008.
47. Otah E, Cushin BJ, Rozenblit GN, Neff R, Otah KE, Cooperman AM. Visceral artery pseudoaneurysms following pancreatoduodenectomy. *Arch Surg* 2002 Jan;137:55–9. 10.1001/archsurg.137.1.55.
48. Beattie GC, Hardman JG, Redhead D, Siriwardena AK. Evidence for a central role for selective mesenteric angiography in the management of the major vascular complications of pancreatitis. *Am J Surg* 2003 Feb;185:96–102. 10.1016/s0002-9610(02)01199-6.

49. Shibata T, Sagoh T, Ametani F, Maetani Y, Itoh K, Konishi J. Transcatheter microcoil embolotherapy for ruptured pseudoaneurysm following pancreatic and biliary surgery. *Cardiovasc Intervent Radiol* 2002;25:180–5. 10.1007/s00270-001-0106-7.
50. Sakamoto Y, Yamamoto Y, Hata S, et al. Analysis of risk factors for delayed gastric emptying (DGE) after 387 pancreaticoduodenectomies with usage of 70 stapled reconstructions. *J Gastrointest Surg* 2011; 15:1789–1797. 10.1007/s11605-011-1498-6.
51. Kunstman JW, Fonseca AL, Ciarleglio MM, Cong X, Hochberg A, Salem RR. Comprehensive analysis of variables affecting delayed gastric emptying following pancreaticoduodenectomy. *J Gastrointest Surg* 2012; 16:1354–1361. 10.1007/s11605-012-1873-y.
52. Tanaka M, Sarr MG: Role of the duodenum in the control of canine gastrointestinal motility. *Gastroenterology* 94:622-629, 1988. 10.1016/0016-5085(88)90232-6.
53. Tanaka M, Sarr MG: Total duodenectomy: Effect on canine gastrointestinal motility. *J Surg Res* 42:483-493, 1987. 10.1016/0022-4804(87)90022-9.
54. Yeo CJ, Barry MK, Sauter PK, et al: Erythromycin accelerates gastric emptying after pancreaticoduodenectomy. A prospective, randomized placebo-controlled trial. *Ann Surg* 218:229-238, 1993.10.1097/0000658-199309000-00002.
55. Ohwada S, Satoh Y, Kawate S, Yamada T, Kawamura O, Koyama T, et al. Low-dose erythromycin reduces delayed gastric emptying and improves gastric motility after Billroth I pylorus-preserving pancreaticoduodenectomy. *Ann Surg* 2001;234:668–74. 10.1097/0000658-200111000-00013.

This page is intentionally left blank



Scan to know paper details and
author's profile

Total Laparoscopy Hysterectomy: Our Experience at Rural Centre Over Two Years

Dr. Nidhi Jain, Dr. Jyotsna Kamra

ABSTRACT

Introduction: Hysterectomy is one of the most common surgeries performed in female of perimenopausal age group. Nowadays, Laparoscopic hysterectomies are on the rising trend, since it is associated with less post operative pain, faster recovery and early return to normal activities. Hence, authors are sharing their experience about total laparoscopic hysterectomy (TLH).

Material and Methods: A retrospective observational study was done over 2 years in a tertiary care hospital in rural area. A total of 108 women were included who underwent TLH by same operating surgeon. The complaints were abnormal uterine bleeding followed by abdominal lump/ abdominal pain. Thorough history and examination was done. Ultrasound pelvis was performed. Surgery was done after informed consent.

Keywords: hysterectomy, laparoscopy, leiomyoma, total laparoscopic hysterectomy.

Classification: NLMC CODE: WI 100

Language: English



LJP Copyright ID: 392812

London Journal of Medical and Health Research

Volume 21 | Issue 4 | Compilation 1.0



© 2021. Dr. Nidhi Jain, Dr. Jyotsna Kamra. This is a research/review paper, distributed under the terms of the Creative Commons Attribution-Noncommercial 4.0 Unported License (<http://creativecommons.org/licenses/by-nc/4.0/>), permitting all noncommercial use, distribution, and reproduction in any medium, provided the original work is properly cited.

Total Laparoscopy Hysterectomy: Our Experience at Rural Centre Over Two Years

Dr. Nidhi Jain^α, Dr. Jyotsna Kamra^σ

ABSTRACT

Introduction: Hysterectomy is one of the most common surgeries performed in female of perimenopausal age group. Nowadays, Laparoscopic hysterectomies are on the rising trend, since it is associated with less post-operative pain, faster recovery and early return to normal activities. Hence, authors are sharing their experience about total laparoscopic hysterectomy (TLH).

Material and Methods: A retrospective observational study was done over 2 years in a tertiary care hospital in rural area. A total of 108 women were included who underwent TLH by same operating surgeon. The complaints were abnormal uterine bleeding followed by abdominal lump/ abdominal pain. Thorough history and examination was done. Ultrasound pelvis was performed. Surgery was done after informed consent.

Results: The mean age of female who underwent TLH was 45.76 ± 6.8 years. All females were multiparous ($P \geq 2$) with mean parity of 2.55 ± 1.5 . The mean BMI was 27.4 ± 5.5 Kg/m². History of previous surgery was found in 38.8% of female. The most common indication of surgery was leiomyoma (55.6%). Mean duration of Hospital stay was 3.77 ± 1.4 days. Among intra-operative complications, 3 cases of bladder injury and 1 ureteric injury was seen. All cases were completed laparoscopically. Among post-operative complications, no major complication was observed.

Conclusion: It was concluded that TLH is an upcoming technique in developing countries like India. It is a safe procedure and associated with less intraoperative and post-operative complications.

Keywords: hysterectomy, laparoscopy, leiomyoma, total laparoscopic hysterectomy.

Author α: Assistant professor, Deptt of OBG, Maharaja Agarsein medical college, Agroha, Hisar, Associate professor.

σ: Deptt of OBG, Maharaja Agarsein medical college, Agroha, Hisar.

I. INTRODUCTION

Hysterectomy is one of the most common surgeries performed in female of perimenopausal age group. It can be done by either vaginal/abdominal or laparoscopic route. Laparoscopic hysterectomies are on the rising trend and being preferred by both patients and surgeons, since it is associated with less post-operative pain, faster recovery, better wound healing and early return to normal activities. Hence, authors are hereby sharing their experience about total laparoscopic hysterectomy (TLH) over a period of two years.

II. MATERIALS AND METHODS

A retrospective observational study was being conducted over a period of 2 years (January 2018 to January 2020) in a tertiary care hospital in rural area after clearance from institutional ethics committee. A total of 108 women were included in the study that underwent TLH by same operating surgeon. Most of these women presented to gynaecological outpatient department with chief complaints of abnormal uterine bleeding. Few of them presented with abdominal lump/pain in abdomen. Thorough history and examination was done. Routine blood investigations were done. Ultrasound of abdomen and pelvis was performed. The patient was taken for surgery after taking informed consent.

III. SURGICAL TECHNIQUE

Patient for surgery was admitted a day before the surgery. Bowel preparation was done by Tablet Charcoal (2 tablets) and Tablet Dulcolax (2 tablets)

at night time before surgery. Informed consent was taken. Preoperative antibiotic (injection Monocel) was given in morning on the day of surgery.

Surgery was done under general anaesthesia with endotracheal intubation. The patient was placed in dorsal lithotomy position. Per vaginal examination was done, Foley's catheterisation was done. Uterine manipulator (Marvah's) was placed.

One 10 mm trocar was placed at the supraumbilical position by direct insertion technique. Carbon dioxide Insufflation was done to create pneumoperitoneum. Two secondary ports of 5 mm each were inserted under direct vision on left side, as shown in figure 1. Another 5 mm trocar was placed on right side in case of large uterus for uterine manipulation by myoma screw. Trendelenberg position was obtained. Intra abdominal pressure was kept in the range of 12-14 mm of Hg and flow rate at the rate of 3 L/min during surgery.

First of all, the fundal structures (round ligament, tubo-ovarian ligament) were cauterised with bipolar cautery and cut with Enseal /scissors/harmonic blade on one side followed by the other side.

After cutting the fundal structures, vesicouterine fold of the peritoneum was opened by harmonic blade/Enseal/scissors, beginning from central part of lower uterine segment and continued on both sides laterally. During this step, cup of uterine manipulator was pushed inward to delineate vesico-uterine plane. Bladder was pushed downwards.

After bladder dissection, skeletonization of uterine artery was done on both sides. Uterine artery was cauterised with bipolar cautery on both sides and then cut with scissors/harmonic blade.

The uterosacral ligaments were then cauterised using bipolar cautery and cut on either side using Enseal/ harmonic blade.

The circular colpotomy was done over the cup of uterine manipulator by using monopolar hook [figure 2]. Vaginally, uterine manipulator was removed and uterus specimen was removed outwards half way to prevent emission of gas. Bilateral salpingectomy was done in all cases.

In cases where age was more than 50 years or ovaries were unhealthy or had complex ovarian cysts, oophorectomy was also done.

Specimen was removed. Vault closure was done vaginally with Vicryl number 1 in initial cases (approximately 40 cases). However, with time and surgical expertise, we have started doing endosuturing. Now in all cases, vault was closed laparoscopically by endosuturing using Vicryl number 1. Haemostasis was checked. Ports were removed and patient was shifted to post-operative room.

IV. RESULTS

The demographic profile is shown in table 1. The mean age of female who underwent TLH was found to be 45.76 ± 6.8 years. Among parity, it was found that all females were multiparous ($P \geq 2$) and none of them were nulliparous with mean parity of 2.55 ± 1.5 .

Weight was not criteria to decide mode of hysterectomy, rather, in obese female's TLH was preferred over abdominal hysterectomy. The mean BMI of patients who underwent total laparoscopic hysterectomy were 27.4 ± 5.5 Kg/m².

History of previous surgery was found in 42 (38.8%) of female, of which most common procedure was tubal ligation (52.4%), followed by caesarean section (30.95%). In two cases, females had history of previous 2 LSCS while in one case there was a history of previous 3 LSCS.

Table 1: Demographic profile of women who underwent TLH

Sr No	Parameters	Values (mean ± SD)
1	Age	45.76 ± 6.8 years
2	Parity	2.55 ± 1.5
3	BMI	27.4 ± 5.5 Kg/m ²
4	History of previous surgeries:	42 (38.8 %)
	a Tubal ligation	22 (52.4 %)
	b LSCS	13 (30.9 %)
	c Myomectomy	2 (4.8 %)
	d Cystectomy	5 (11.9 %)
	Total	42 (100%)

Indications of surgery are shown in table 2. The most common indication for performing surgery was uterine leiomyoma (60 cases, 55.6 %), follow-

ed by dysfunctional uterine bleeding (35.3%). There were 6 cases of ovarian cyst (5.6%) and 3 cases (2.8%) of adenomyosis.

Table 2: Indication of surgery in females who underwent TLH

Sr No.	Indication of surgery	Number of cases (%)
1	Leiomyoma	60 (55.6 %)
2	DUB	38 (35.3 %)
3	Ovarian cyst	6 (5.6 %)
4	Chronic pelvic inflammatory disease	1 (0.9 %)
5	Adenomyosis	3 (2.8 %)
6	Postmenopausal bleeding	1 (0.9 %)
7	Endometrial hyperplasia	1 (0.9 %)

The uterine size was not the criteria to decide the mode of surgery. We have done total laparoscopic hysterectomy even in the female of uterine size 18-20 weeks. Most common uterine size was 6-12

weeks. Mean uterine size for which total laparoscopic hysterectomy was done was 11.5 ± 1.9 gestational weeks [table 3].

Table 3: Size of uterus in females who underwent TLH

Sr No.	Size of uterus (weeks)	Number of cases (%)
1	6-12	74 (68.5 %)
2	>12-16	31 (28.7 %)
3	>16-20	3 (2.8 %)
	Total	108 (100%)
	Mean size	11.5 ± 1.9 weeks

Intraoperative and post-operative complications are shown in table 4. The patient who underwent TLH were usually admitted a day before surgery and were discharged within 4 days after removal

of Foley's catheter and under satisfactory condition. Mean duration of Hospital stay was 3.77 ± 1.4 days.

Table 4: Intra and post operative complication in women who underwent TLH

Sr no	Complications	Number of cases (%)
	Duration of hospital stay	3.77 ± 1.4 days
Intra-operative complications		
1	Bladder injury	3 (2.8%)
2	Ureter injury	1 (0.9 %)
3	Bowel injury	0 (0 %)
4	Vascular injury	0 (0 %)
5	Conversion to laparotomy	0 (0 %)
Post operative complications		
1	Need of blood transfusion	20 (0.9%)
2	Fever	8 (7.4%)
3	Abdominal distension	5 (11.9 %)
4	Prolonged catheterization	10 (9.3 %)
5	Wound sepsis	0 (0%)
6	Subcutaneous emphysema	1 (0.9%)
7	Vaginal bleeding	1 (0.9%)

Among intraoperative complications, visceral injuries were seen in four cases (3.7%). 3 cases were of bladder injury (2.8%) and one case was of ureteric injury (0.9%).

Among these 3 cases of bladder injury, all cases were diagnosed during the surgery and simultaneous repair was done with the Vicryl number 2-0 in two layers. Bladder integrity was checked followed by which TLH was done in the same sitting. Post-operative catheter was placed for 21 days. After 21 days, catheter was removed and

patients had no complaint in micturition. All of these 3 cases had history of previous surgeries of which one had history of previous 2 LSCS, another case had history of previous 3 LSCS and last one was with previous history of LSCS and tubal ligation.

One case had ureteric injury which was diagnosed post operatively on day 7. Patient came with complaints of urinary incontinence for which she was readmitted and evaluated. CT urography was done and diagnosis of right uretero-vaginal fistula

(small, in lower one third of the ureter) was made. High risk factor seen in this case was obesity (BMI 29.3 Kg/m²). Patient was referred to urosurgeon and DJ stent was placed but patient did not improve. So, decision of surgery was taken. Patient underwent laparotomy with neoureterostomy (via urinary bladder flap). Post operatively, Foley's catheter was placed for 3 weeks. After 3 weeks, Foley's catheter was removed and patient passed urine normally. Till date, patient is comfortable and asymptomatic.

No case of bowel injury or vascular injury was seen. All cases were completed laparoscopically and in none of the cases, laparotomy conversion was required.

Among post-operative complications, no major complication was observed. Blood transfusion was done in 20 cases (18.5%). This high number of transfusions could be explained on the basis that we are doing surgeries at the rural level where patient has poor nutritional status and most of them suffer from anaemia. 8 patients (7.4%) had fever which were managed symptomatically. 5 patients (11.9%) had complains of abdominal distension post-operatively. All of these cases were managed conservatively.

Prolonged catheterisation (≥ 48 hours) was done in 10 cases (9.3%). Out of these 10 cases, 3 cases were of per-operative bladder injury and 1 case was of ureteric injury. In rest of the 6 cases, the bladder was adherent, separated by sharp and blunt dissection and hence prophylactically prolonged catheterisation was done.

One patient had subcutaneous emphysema which was managed conservatively.

One patient had vaginal bleeding on post-operative day 2. Patient was shifted to operation theatre. Under intravenous anaesthesia, vault was explored vaginally and bleeder was found, suture was taken vaginally and vaginal packing was done for 48 hours. Patient was comfortable thereafter and discharge was done under satisfactory condition on post-operative day 7.

No wound sepsis occurred after laparoscopic procedure showing that wound healing is better after laparoscopic procedure.

V. DISCUSSION

The present study included 108 cases that underwent TLH. All of these cases were done for benign indications, most common of which was uterine leiomyoma (55.6%) followed by dysfunctional uterine bleeding (35.3%).

Among patients demographic profile, mean age and parity was 45.76 ± 6.8 years and 2.55 ± 1.5 respectively. Obesity was not the criteria to defer laparoscopy. Rather, it was preferred by operating surgeon to do TLH in obese patients for better wound healing and easy surgery as compared to open technique. Also, it was observed that most common size of uterus on which we operated was 6-12 weeks (68.5%).

Similar results were seen in study by Bettaiah Ramesh et al^[1] who evaluated association between outcomes of laparoscopic hysterectomy with respect to clinical factors, intra-operative variants and post-operative complications. Their study included 858 females who underwent total laparoscopic hysterectomy. All surgeries were performed by same surgeon by same technique. Average age of female who underwent surgery was 44.9 ± 6.2 years. Most common indication of surgery was leiomyoma (54.4%) followed by dysfunctional uterine bleeding (17.8%). In most of the cases (57.6%) size of uterus operated was 6-12 weeks followed by 12-16 weeks (16.3%). It was concluded that total laparoscopic hysterectomy is associated with less complication rate and early post-operative recovery.

In our study, history of previous abdominopelvic surgery was present in 38.8% cases of which most common procedure was tubal ligation (52.4%) followed by LSCS (30.9%).

Similar results were seen in study by Mereu et al^[2] in which 41.3% females who underwent total laparoscopic hysterectomy had history of previous laparotomy including 24.1% woman who had history of previous one or more LSCS. Thus, it can be seen that we can do TLH in females with history of abdominopelvic surgery safely depending on the surgical expertise.

TLH can be done in obese women. In our study, mean BMI of patient undergoing surgery was 27.4 ± 5.5 kg/m². Results were in concordance with that obtained by Twijnshtra et al ^[3] in 2012. They did one year cohort analysis including 1534 laparoscopic hysterectomy done by 79 surgeons. Mean BMI of patient undergoing surgery was 27.5 ± 5.7 kg/m². It was found that success of surgical outcome was significantly associated with BMI, uterine weight and previous abdominal surgery.

Now days, concept of the day care hysterectomy is on rising trend. In this, patient is being discharged on the same day of surgery (within 24 hours). However, in our study, mean duration of hospital stay was 3.77 ± 1.4 days. Patients were admitted a day before surgery and discharged within 4 days in most of the cases. Longer hospital stay in our study could be because of the fact that this study is done in the rural area where myth is prevalent that patient care is better in the hospital and will have more complications if discharged early. The results were compared to the study done by Jinhwa Lee et al in 2015^[4]. In their study, 50 cases were included in which 25 patients underwent conventional multiport total laparoscopic hysterectomy. The duration of postoperative hospital stay was 4-7 days, average being 3 days.

In our study, among intraoperative complications, bladder injury was seen in 3 cases (2.8%), ureteric injury in 1 case (0.92 %) and no bowel or vascular injury was observed. None of the cases were converted to laparotomy. All urinary bladder injuries were diagnosed and repaired during the procedure. All of these 3 cases had history of previous abdominal surgeries. Ureteric injury was diagnosed post-operatively and managed by urologist via laparotomy with neoureterostomy. The only risk factor in the patient with ureteric injury was obesity.

The results were in accordance seen in the study done by Boosz 2011 et al ^[5]. It was a retrospective analysis done over 7 years including total of 867 cases of which 567 underwent total laparoscopic hysterectomy and remaining 300 underwent laparoscopic assisted Supracervical hysterectomy.

Urinary bladder injury occurred in 4 cases; ureteric injury in 1 case and 1 patient had bowel injury.

Another study was done by Morelli et al in 2007^[6] who reported significantly higher percentage of bladder injuries (3.5%), probably related to the high number of patients with previous LSCS (more than 50%).

Thus, it can be observed that TLH is a safe procedure and associated with less intraoperative complications. Furthermore, the complication rates are decreased with time and surgical expertise. Also, risk is more in females with previous abdominal surgeries and who are obese, however, no statistically significant association was found.

Among post-operative complications, no major complication was found. Blood transfusion was done in 20 females (18.5%). Abdominal distension occurred in 5 cases, all of which were managed conservatively. However, in other studies ^[2,6,7], lesser number of blood transfusions were given post operatively. This discrepancy can be explained on the basis of preoperative nutritional status of the patient included in our study.

Minor vaginal bleeding occurred in 1 case, diagnosed on post-operative day 2 and was managed by applying haemostatic suture vaginally. No blood transfusion was required in this case.

None of the patient had a wound sepsis showing that TLH is associated with better wound healing. No case of vault dehiscence was observed.

VI. CONCLUSION

This study concluded that total laparoscopic hysterectomy is an upcoming technique in developing countries like India. It is a safe procedure and associated with less intraoperative and post-operative complications. The complication rate can be further decreased with surgical expertise. Hence, laparoscopic procedure should be a part of training for all gynaecologists.

REFERENCES

1. Bettaiah R, Reddy CA. Laparoscopic Hysterectomies: Our 10 Years Experience in a Single Laparoscopic Center. *J Obstet Gynaecol India.* 2016; 66(4):274-281.
2. Mereu, L., Carlin, R., Pellegrini, A., Guasina, F., Berlanda, V., & Tateo, S. Total laparoscopic hysterectomy for benign disease: outcomes and literature analysis. *Gynecological Surgery* (2018); 15, 1-7.
3. Twijnstra AR, Blikkendaal MD, van Zwet EW, van Kesteren PJ, de Kroon CD, Jansen FW. Predictors of successful surgical outcome in laparoscopic hysterectomy. *Obstet Gynecol.* 2012; 119(4):700-708.
4. Lee J, Kim S, Nam EJ, Hwang SM, Kim YT, Kim SW. Single-port access versus conventional multi-port access total laparoscopic hysterectomy for very large uterus. *Obstet Gynecol Sci.* 2015; 58(3):239-245.
5. Boosz A, Lermann J, Mehlhorn G, et al. Comparison of re-operation rates and complication rates after total laparoscopic hysterectomy (TLH) and laparoscopy-assisted supracervical hysterectomy (LASH). *Eur J Obstet Gynecol Reprod Biol.* 2011; 158(2):269-273.
6. Morelli M, Caruso M, Noia R, D Chiodo, Cosco C, Lucia E et al: Total laparoscopic hysterectomy versus vaginal hysterectomy: a prospective randomized trial. *Minerva Ginecol.* 2007; 59(2):99-105.
7. Ng CC, Chern BS, Siow AY. Retrospective study of the success rates and complications associated with total laparoscopic hysterectomy. *J Obstet Gynaecol Res.* 2007; 33(4):512-518.

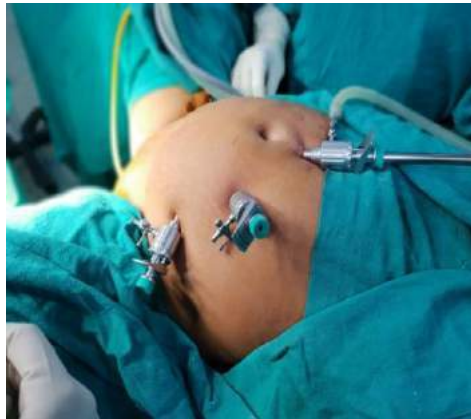

Figure I: Image showing 10 mm supraumbilical port and two 5 mm ancillary ports.

Figure 1: Image showing one supraumbilical port of 10 mm and two ancillary ports of 5 mm each

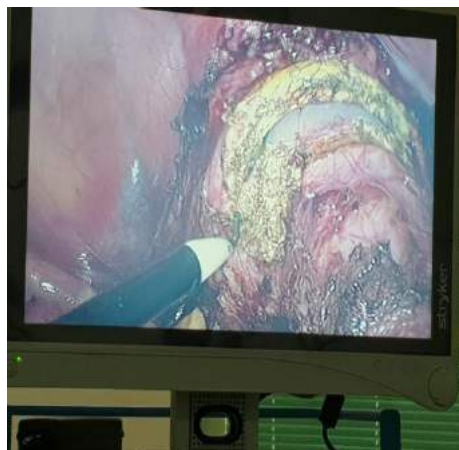

Fig II: Image showing circular colpotomy by monopolar hook.

Figure 2: Image showing circular colpotomy by monopolar hook



Scan to know paper details and author's profile

Comparative Study between Hearing Thresholds as Determined by Pta and Assr in Patients with and without Hearing Loss

Dr. Prashant Hippargekar, MS; Dr. Sudhir Bhise, MS; Dr. Shankar Kothule, MS; & Dr. Saeer Savtale, MS

ABSTRACT

Background: Auditory steady state response provides a frequency specific and automatic assessment of hearing sensitivity and is used in infants and difficult to test population.

Objective: The present study is a prospective interventional study to evaluate correlations between hearing thresholds determined by pure- tone audiometry (PTA) and auditory steady- state response (ASSR) testing among patients with and without hearing loss. **Materials and methods:** The study was conducted on 120 ears— 40 ears with conductive hearing loss, 40 ears with sensorineural hearing loss, and 40 normal- hearing ears.

Results: It was found that mean threshold differences between PTA results and ASSR testing at different frequencies did not exceed 15 dB in any group. Using Pearson correlation coefficient calculations, it was determined that the two responses correlated better in patients with sensorineural hearing loss than in those with conductive hearing loss and best in the normal population.

Conclusion: Measuring ASSRs can be an excellent complement to other diagnostic methods like pure tone audiometry in determining hearing thresholds especially in malingering and other difficult to test adults.

Keywords: pure tone audiometry, auditory steady state response, malingering, medico legal aspects of hearing, audiology.

Classification: NLMC CODE: WV 270

Language: English



LJP Copyright ID: 392813

London Journal of Medical and Health Research

Volume 21 | Issue 4 | Compilation 1.0



© 2021. Dr. Prashant Hippargekar, MS; Dr. Sudhir Bhise, MS; Dr. Shankar Kothule, MS; & Dr. Saeer Savtale, MS. This is a research/review paper, distributed under the terms of the Creative Commons Attribution-Noncommercial 4.0 Unported License <http://creativecommons.org/licenses/by-nc/4.0/>, permitting all non-commercial use, distribution, and reproduction in any medium, provided the original work is properly cited.

Comparative Study between Hearing Thresholds as Determined by Pta and Assr in Patients with and without Hearing Loss

Dr. Prashant Hippargekar, MS;^α Dr. Sudhir Bhise, MS;^σ Dr. Shankar Kothule, MS;^ρ
& Dr. Sae Savtale, MS^ω

ABSTRACT

Background: Auditory steady state response provides a frequency specific and automatic assessment of hearing sensitivity and is used in infants and difficult to test population.

Objective: The present study is a prospective interventional study to evaluate correlations between hearing thresholds determined by pure-tone audiometry (PTA) and auditory steady-state response (ASSR) testing among patients with and without hearing loss. Materials and methods: The study was conducted on 120 ears—40 ears with conductive hearing loss, 40 ears with sensorineural hearing loss, and 40 normal-hearing ears.

Results: It was found that mean threshold differences between PTA results and ASSR testing at different frequencies did not exceed 15 dB in any group. Using Pearson correlation coefficient calculations, it was determined that the two responses correlated better in patients with sensorineural hearing loss than in those with conductive hearing loss and best in the normal population.

Conclusion: Measuring ASSRs can be an excellent complement to other diagnostic methods like pure tone audiometry in determining hearing thresholds especially in malingering and other difficult to test adults.

Keywords: pure tone audiometry, auditory steady state response, malingering, medico legal aspects of hearing, audiology.

Author α: HOD and prof otolaryngology dept SRTR GMC AMBAJOGA.

σ: Asso. prof otolaryngology dept SRTR GMC AMBAJOGAI.

ρ: Asst. professor instead of Asso professor .

ω: Junior resident III otolaryngology dept SRTR GMC AMBAJOGA.

I. INTRODUCTION

An otologist today has at his armamentarium a myriad of tests that can be differently used in different clinical outcomes to correctly diagnose the hearing acuity in an adult. Still a dark and an under-utilised area in this field is measuring hearing loss in the difficult to test population amongst adults(1). These are those who are feigning their hearing abilities for compensatory or monetary gains; Psychologically impaired patients and Patients who are heavily sedated and unable to communicate. The audiology community has a repertoire of procedures available to it to detect malingering , that includes Stenger's test ,Erhard's test, Lombard's test, Hummel double conversation test, Callhan's voice test, Tuning fork tests. While all these tests just give a qualitative analysis, the only test that is widely used for screening adults is the pure tone audiometry. However being a subjective test it may at times be inconclusive, in patients with psychomotor impairment. It is also inaccurate in uncooperative adults and malingerers.

Auditory brainstem response (ABR) testing has been proposed as an objective alternative for acquiring pure-tone audiograms in these kinds of patients(2). ABR testing conducted with click stimuli is associated with a high degree of reproducibility and stability of the waveform (3). However, frequency specificity in ABR testing is poor, and therefore its use in identifying threshold

levels in the lower audiometric range is poor. Another limitation of the use of ABR testing is in the evaluation of severe to profound hearing loss. ABR testing cannot measure thresholds greater than 90 dB HL. This limitation can make hearing losses that exceed the maximum output difficult or impossible to quantify (4).

(5) Auditory steady state response can be thought of as an electrophysiological response to rapid auditory stimuli. It relies on statistical measures to determine if and when a threshold is present. In ASSR pure tone sounds are used as stimuli that can be modulated in both amplitude and frequency domain. The ASSR is a type of auditory evoked potential, elicited with modulated tones that can be used for determining hearing sensitivity for patients of all ages. It is a far-field auditory evoked potential recording(6). The ASSR reflects activity from different portions of the brain, depending on the modulation rate used. Brain's central structures respond to slower rates, while the brainstem and peripheral auditory nerves respond to faster modulation rates. The results are shown as an electrophysiological audiogram, which allows the physician to see the configuration of an individual's hearing.(6)

(7) According to John and Picton and Valdes et al., the method has advantages, such as objective threshold detection as well as the simultaneous evaluation of multiple frequencies and the presentation of high-intense stimuli. Because they are not pure tones, The test stimuli are reasonably frequency specific regardless of the mode of modulation.. These stimuli are continuous too, making the calibration straightforward. ASSR can even differentiate patients of severe SNHL from that of the profound degree of SNHL, because of steady tonal stimuli used permitting higher outputs for analysis. Moreover finally, the most important advantage is that the spectrum of the response is predicted precisely by that of the stimulus spectrum without the need for subjective interpretation of the recorded response. The threshold values found by ASSR are converted into graphs like that of PTA via computer based algorithms. These graphs are read on an objective basis, and do not require manual detection as in ABR.

Hence, ASSR overcomes the common limitation of most clinical tests of auditory evoked potentials.(6)

Modulation of a pure-tone sound stimulus narrows the spectral splatter, resulting in stimulation of a very restricted and narrow area of the basilar membrane. Which means that a more frequency-specific hearing threshold can be elicited by ASSR testing than by ABR testing. If the rate of modulation is higher than 60 Hz, the neural activity is recorded from the brainstem. Different areas of the auditory pathway can be stimulated by altering the rate of modulation. <20Hz – cortical areas, 20-50 Hz- sub cortical areas of the CANS (midbrain and thalamus) and >60Hz – brain stem. Responses from brain stem are not affected by the mental state of the patient. The responses are analyzed by a sophisticated, objective, statistically based mathematical detection algorithm to provide hearing thresholds at four given frequencies. In addition, ASSR testing allows for stimulation at high intensity levels of 120 dB HL, whereas ABR testing cannot differentiate between severe and profound hearing losses. The ability to detect differences in these significant hearing-loss categories is important. (8)

During the past few years, several studies have evaluated the clinical application of ASSR testing as an objective audiometric method. Reports have demonstrated significant correlations between PTA and ASSR test results in various age groups and in patients with different levels of hearing loss.(9) Despite good correlations between PTA and ASSR values, there has been significant variability among study results, as reported differences in PTA and ASSR values have ranged from 4 to 34 dB.To establish its role in testing hearing thresholds in normal population and screen functional hearing loss, a prospective study was conducted at SRTR GMC Ambajogai from March 2019 to September 2019 with following aims-

1.1 Aims and objectives

- To find correlations between hearing thresholds obtained by PTA and ASSR.

- Verify the applications of ASSR for hearing loss estimation.
- Confirm credibility to be used for medico legal purposes and detect malingering.

II. MATERIALS AND METHODS

Study was conducted on 60 participants between ages 18-80 years visiting the ENT OPD at our institute with non otological complaints. They were recruited into three groups of 20 depending on their hearing status as determined by tuning fork tests and PTA; namely Normal patients, patients with Conductive hearing loss, and patients with Sensorineural hearing loss.

Exclusion criteria:

1. A mixed hearing loss
2. Any local skin disease
3. Congenital anomalies of ear
4. Actively discharging ear
5. Unreliable response on PTA or those seeking any handicap certificate or compensation

Written valid informed consent was taken from all patients and both PTA and ASSR were performed in a sound proof quiet room on the same day to avoid attrition. (3) PTA along with tuning fork tests were performed initially to determine the type of hearing loss.

PTA was conducted with an ALPS AD 2000+ audiometer (ALPS; New Delhi). For evaluation and statistical purposes, thresholds were measured at 0.5, 1.0, 2.0, and 4.0 kHz ASSR stimuli.

ASSR measurements were recorded on a Universal Smart Box Junior two-channel device (Intelligent Hearing Systems; Miami) in a sound-attenuated room. Participants were tested while they were awake and in a relaxed supine position. Registration electrodes were placed over both mastoid bones at the hairline and on the low forehead. Air-conducted stimuli were presented via inserted earphones. (10) Test frequencies of 0.5, 1.0, 2.0, and 4.0 kHz were used as ASSR carrier stimuli. The four carrier frequencies were delivered simultaneously to both ears. These frequencies were modulated with respect to

amplitude and frequency. (11) For ASSR, A 100% amplitude modulation was used and 20% frequency modulation was combined with it. Modulation frequency was different for each carrier frequency: 77 Hz for 0.5 kHz, 85 Hz for 1.0 kHz, 93 Hz for 2.0 kHz, and 101 Hz for 4.0 kHz. The ASSR threshold was defined as the lowest intensity at which a significant response could be detected; a non significant response was defined as one that was 10 dB below this level.(12)

III. THEORY AND CALCULATION

Demographic data:

Table 1: Age wise distribution of the study population

Age group in years	percentage %
<50	42.3
51-60	23.1
61-70	26.9
>71	7.7

Table 2: Sex wise distribution of the study population

Gender	frequency	percentage
male	34	56.66
female	26	43.33

Mean thresholds provided by both tests were calculated at 4 frequencies i.e. 500, 1000, 2000 and 4000 Hz. It shows that on both sides when thresholds given by PTA and ASSR were compared, ASSR values were 10 dB higher than that of PTA.

Table 3: Mean PTA and ASSR of both ears at all frequencies and across all 3 groups

FREQUENCY	PTA	ASSR	
500	23.1	33.2	
1000	23.0	33.0	
2000	24.2	34.1	
4000	24.4	34.4	

The patients were stratified further on the basis of the type of hearing loss and mean threshold were plotted on a bar graph

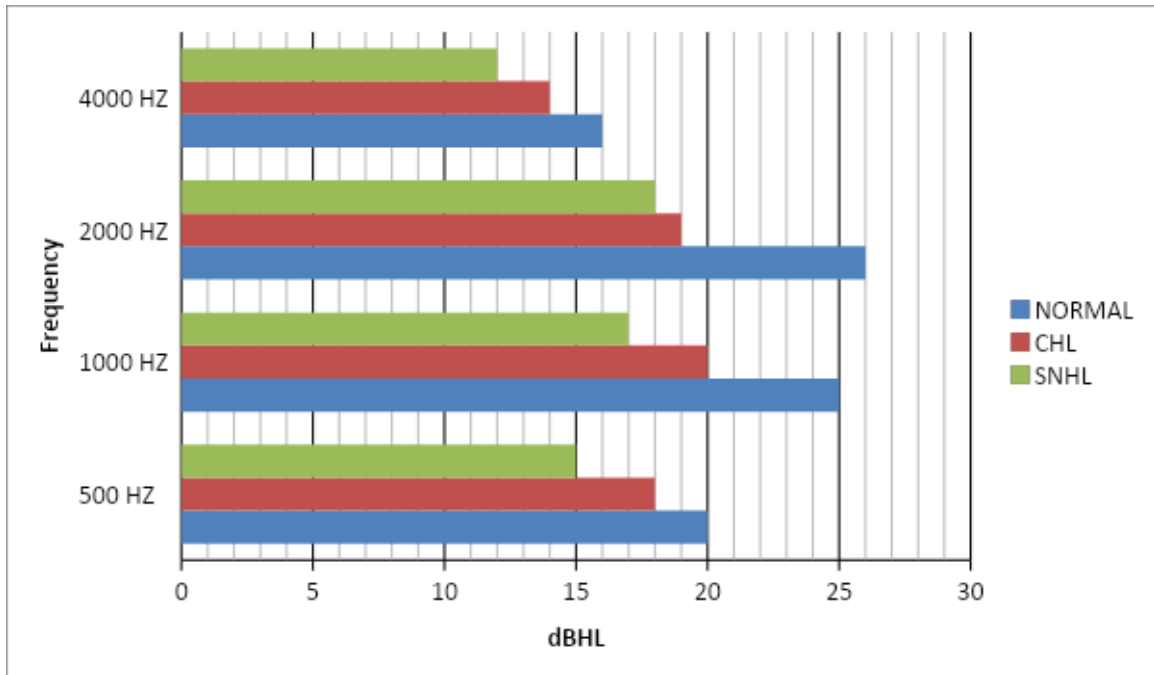


Figure 1: Mean thresholds in 3 groups, as determined by PTA

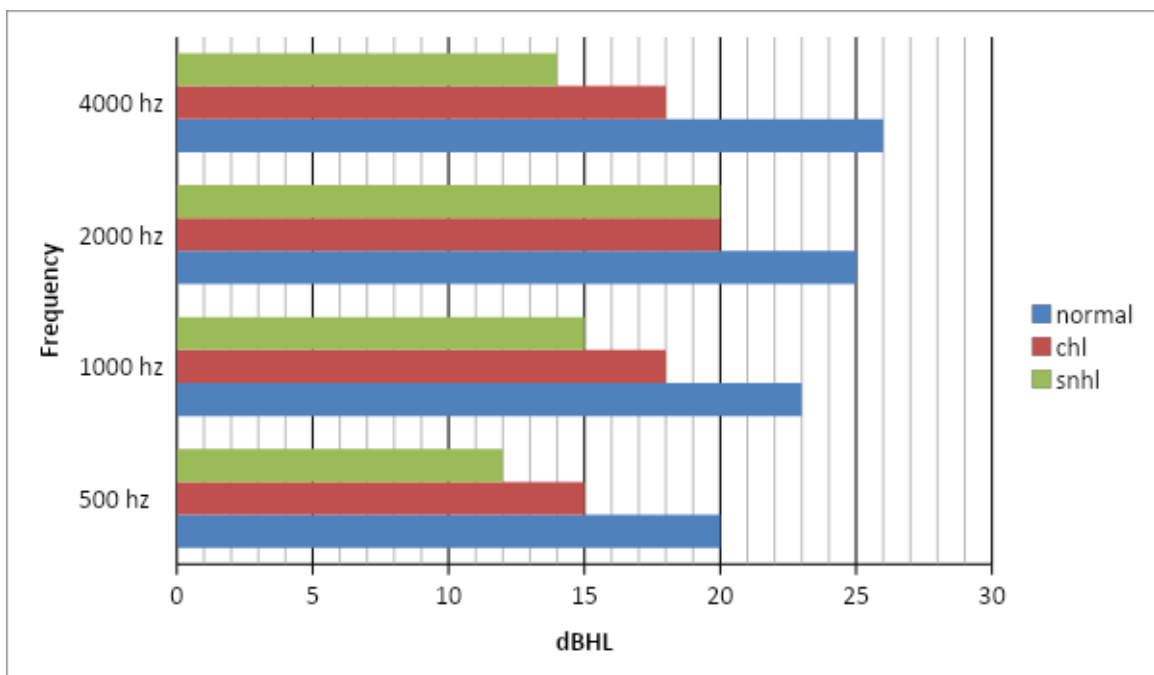


Figure 2: Mean thresholds in 3 groups, as determined by ASSR

Consistent threshold values are seen at all frequencies in normal and patients with SNHL when tested by both PTA and ASSR with minor variations in patients with CHL.

IV. STATISTICAL ANALYSIS

After the PTA and ASSR measurements, statistical analysis was performed with the Statistical

Package for the Social Sciences software (v. 17.0). Continuous variables were presented as a mean with standard deviation, and categorical variables were presented as absolute numbers and percen-

tages. The comparison of normally distributed continuous variables between PTA and ASSR results was performed with the Student t test.

Table 3: Mean standard deviations and p values by both PTA and ASSR among normal patients

HEARING STATUS	500HZ MEAN SD	1000 HZ MEAN SD	2000 HZ MEAN SD	4000 HZ MEAN SD
PTA	18.92 +/- 3.46	20.33+/- 3.89	20.33+/- 3.30	18.83 +/- 3.85
ASSR	20.50 +/- 10.51	22.38+/- 10.09	19.25 +/- 9.72	18.67 +/- 03.42
DIFFERENCE	9 +/- 7	8 +/- 7	9 +/- 06	10 +/- 08
p VALUE	0.271	0.145	0.708	0.908

Table 4: Mean standard deviations and p values by both PTA and ASSR among patients suffering from conductive hearing loss

HEARING STATUS	500HZ MEAN SD	1000 HZ MEAN SD	2000 HZ MEAN SD	4000 HZ MEAN SD
PTA	40.89 +/- 12.02	46.31+/- 13.20	44.62 +/- 13.52	44.56 +/- 12.41
ASSR	49.19 +/- 21.37	52.12 +/- 22.02	49.25 +/- 19.22	45.88 +/- 18.42
DIFFERENCE	15 +/- 12	14 +/- 11	13 +/- 10	12 +/- 10
p VALUE	0.003	0.045	0.081	0.598

Table 5: Mean standard deviations and p values by both PTA and ASSR among patients suffering from sensorineural hearing loss

HEARING STATUS	500HZ MEAN SD	1000 HZ MEAN SD	2000 HZ MEAN SD	4000 HZ MEAN SD
PTA	42.06 +/- 20.45	49.94 +/- 25.14	49.50 +/- 25.24	56.94 +/- 24.97
ASSR	40.08 +/- 20.59	50.52 +/- 23.37	48.52 +/- 25.87	49.24 +/- 21.22
DIFFERENCE	11 +/- 09	12 +/- 08	13 +/- 10	13 +/- 11
p VALUE	0.543	0.880	0.809	0.042

Mean threshold differences were statistically significant at 0.5 and 1.0 kHz in the CHL group and at 4.0 kHz in the SNHL group. In the control group, the mean threshold differences were not statistically significant at any frequency. There was significant difference between the values given by both tests in conductive hearing loss at

lower frequencies and in sensorineural hearing loss at higher frequencies.

Within groups, the Pearson correlation coefficient (r value) was calculated between the PTA and ASSR results measured at 0.5, 1.0, 2.0, and 4.0 kHz.

Table 6: The pearson correlation coefficient values between the PTA and ASSR results at each frequency in the three groups

0.5 Hz	r value
CHL	0.640
SNHL	0.779
Normal	0.856
1Hz	r value
CHL	0.664
SNHL	0.782
Normal	0.814
2Hz	r value
CHL	0.694
SNHL	0.796
Normal	0.830
4Hz	r value
CHL	0.655
SNHL	0.682
Normal	0.822

The values of hearing thresholds given by both tests showed positive correlation in all 3 types of Patients. A stronger correlation was found among patients with no hearing loss ..(13)

V. DISCUSSION

Better correlations of PTA and ASSR were reported on 1kHz and 2kHz .This can be attributed to the presence of natural jitter causing neural asynchrony at lower frequencies and recruitment phenomenon that plays a role at higher frequencies.(3)Lins and Picton suggested that ASSR results should be interpreted with caution at 0.5 kHz because low-frequency–evoked responses are characterized by a greater degree of intrinsic jitter attributable to neural asynchrony. This could make it more difficult to determine threshold levels for low-frequency stimuli than for high-frequency stimuli. Lower levels of correlation at 0.5 kHz might also be attributable to noise floor.(14) Komazec et al reported that correlation coefficients with respect to the level of hearing loss were the lowest in persons with normal hearing ($r = 0.64$) and in patients with only a slight hearing loss ($r = 0.63$).

The differences in the mean thresholds between ASSR and PTA were smaller in SNHL and CHL and negligible in normal patients. The smaller threshold differences found in hearing-impaired patients might reflect an abnormal increment in the response amplitude at above-threshold intensities.(15) In our study, the smallest difference between mean PTA and ASSR thresholds was seen at 1.0 kHz (8 ± 7 dB) in the control group. (1)Ode et al also reported that the difference between mean PTA and ASSR thresholds was smallest in their control group at 1.0 kHz. In their hearing-impaired group, they found that the difference between mean PTA and ASSR thresholds was largest at 4.0 kHz, which is consistent with our findings in our SNHL group. In their study, the difference between mean PTA and ASSR thresholds at each frequency was no more than 15 dB in both their hearing-impaired and control groups. We also found no difference of more than 15 dB at each frequency in all three of our groups. Moreover, (16)Ozdek et al found that the difference between mean PTA and ASSR

thresholds at each frequency was smaller in their hearing-impaired patients than in their controls. However, we found that the difference was smaller in our control group than in our CHL and SNHL groups.

Limitations

As this test is still under research, various aspects like the standardisation of criteria are required. (18) ASSR systems must establish normative air-conduction as well as bone-conduction ASSR thresholds because it is still relatively new, ASSR testing requires further experience and study data on large numbers of patients so to understand all its intricacies. Many factors, including the type of modulation, the number of sweeps acquired during response analysis, electrode montage, and modulation rate, can affect ASSR results, and these factors have not yet been fully elucidated. Improvements in the methodological aspects of ASSR testing should encourage its routine use in clinical practice.To be used as a standard diagnostic clinical instrument, ASSR systems must establish normative air-conduction as well as bone-conduction ASSR thresholds, not only for persons with normal hearing and those with SNHL, but also for patients with CHL and mixed hearing loss.

VI. CONCLUSION

Thus, combating the fallacies of PTA, ASSR can be reliably used as:

- A complementary test to detect hearing acuity.
- Measure hearing threshold for medico legal and therapeutic purposes(17)
- Employed for diagnostic purposes of CANS hearing losses (14)

In summary, it was found that ASSR testing correlated with PTA results better in patients with SNHL than in those with CHL. Although the mean threshold differences were smaller in our control group, ASSR testing correlated poorly with PTA in this group. It can be concluded that ASSR testing can be an excellent complement to other diagnostic methods to serve as a valuable tool in the determination of hearing thresholds in adults for detecting malingering and for difficult to test populations.

ACKNOWLEDGEMENTS

The Authors express their thanks to patients for participation.

Funding

No funding was received to conduct the above study.

REFERENCES

1. Picciotti PM, Giannantonio S, Paludetti G, Conti G. Steady state auditory evoked potentials in normal hearing subjects: Evaluation of threshold and testing time. *ORL*. 2013 Feb; 74(6):310–4.
2. Brookhouser PE, Gorga MP, Kelly WJ. Auditory brainstem response results as predictors of behavioral auditory thresholds in severe and profound hearing impairment. *Laryngoscope*. 1990;100(8):803–10.
3. Duarte JL, Alvarenga K de F, Garcia TM, Filho OAC, Lins OG. Auditory steady-state response in the auditory evaluation: Clinical application. *Pro-Fono*. 2008;20(2):105–10.
4. Eggermont JJ. The Inadequacy of Click-evoked Auditory Brainstem Responses In Audiological Applications. *Ann N Y Acad Sci*. 1982; 388(1):707–9.
5. The auditory steady_KODDYz.
6. Kapil Kumar Singh, Arvind Trivedi, Nikunj Jain, Mohd Irteza. To Study Auditory Functions in Chronic Kidney Disease. *Indian J Otol*. 2018;23(3):261–5.
7. Lins OG, Picton TW. Auditory steady-state responses to multiple simultaneous stimuli. *Electroencephalogr Clin Neurophysiol Evoked Potentials*. 1995;
8. Wadhwa R, Hernot S, Gulati SP, Kalra V. A controlled comparison of auditory steady-state responses and pure-tone audiometry in patients with hearing loss. *Ear, Nose Throat J*. 2017;96(10–11):47–52.
9. Biswas A. *Clinical audio-vestibulometry for otologists and neurologists*. 4th ed. mumbai: bhalani; 1995.
10. Chen Y, Song JS. [The clinical application status and progression of auditory steady-state evoked response]. *Lin chuang er bi yan hou tou jing wai ke za zhi* = *J Clin Otorhinolaryngol head, neck Surg*. 2017 Dec;31(23):1854–7.
11. Prado-Gutierrez P, Martínez-Montes E, Weinstein A, Zañartu M. Estimation of auditory steady-state responses based on the averaging of independent EEG epochs. Malmierca MS, editor. *PLoS One* [Internet]. 2019 Jan 24 [cited 2020 Sep 13];14(1): e0206018. Available from: <https://dx.plos.org/10.1371/journal.pone.0206018>
12. Swami H, Kumar S. Comparison of Frequency Specific Hearing Thresholds between Pure - Tone Audiometry and Auditory Steady - State Response. 2019;59–65.
13. The correlativity between the threshold acquired with ASSR and PTA]. 2020;24 (5):18979911.
14. Komazec Z, Lemajić-Komazec S, Jović R, Nadj C, Jovancević L, Savović S. Comparison between auditory steady-state responses and pure-tone audiometry. *Vojnosanit Pregl*. 2010 Sep;67(9):761–5.
15. Ismaila N, El-Saiid E, El Sebaili A, Fadel H. Reliability of auditory steady-state response to bone conduction stimuli in assessing hearing loss in children. *Egypt J Otolaryngol* [Internet]. 2016 Jul 1;32(3):196–201. Available from: <http://www.ejo.eg.net/article.asp? issn =1012-5574>
16. Ozdek A, Karacay M, Saylam G, Tatar E, Aygener N, Korkmaz MH. Comparison of pure tone audiometry and auditory steady-state responses in subjects with normal hearing and hearing loss. *Eur Arch Oto-Rhino- Laryngology*. 2010 Jan;267 (1): 43–9.
17. Yang X-P, Fan L-H, Zhou X-R. [The correlativity between the threshold acquired with ASSR and PTA]. *Fa Yi Xue Za Zhi* [Internet]. 2008 Oct;24(5):321–324. Available from: <http://europepmc.org/abstract/ME D/18979911>.
18. Jafari Z, Farahani MA. Adults with Auditory Neuropathy : Comparison of. 2009;628:6218.



Scan to know paper details and author's profile

Hypertrophic Intracranial Pachymeningitis of a Tuberculosis Etiology: Case Report and Systematic Review of the Literature

J. Laaguili, Y.C.H. Dokponou, B. El Jebbouri, A.C. El Asri, B. El Mostarchid, M. Gazzaz

Mohamed V University

ABSTRACT

Background: Intracranial pachymeningitis is a rare neurological condition and tuberculosis as its etiology is uncommon. In the literature, little information is known about the epidemiological profile, clinical presentation, diagnosis, management, and outcome of patients with pachymeningitis of tuberculous origin.

Methods: The authors present a case of tuberculosis intracranial pachymeningitis with a systematic review of the literature according to the Preferred Reporting Items for Systematic Reviews and Meta - Analyses guidelines. Relevant studies (up to June 2021) that reported patients with intracranial pachymeningitis of tuberculosis origin, were identified from the Google Scholar, PubMed, and Cochrane Library databases.

Results: This systematic review identified 19 patients of whom 11 were male and 8 were female. The mean value of age was 39.42 (Std. Deviation 14.54) years. Eleven patients had intracranial hypertension and hemiparesis while five presented with headache and blurred vision at admission. Surgery was performed in 18 patients. The presence of mycobacterium tuberculosis was not confirmed in one patient treated successfully with the antituberculosis drugs. Furthermore, 18 out of the 19 patients reported improved outcomes, only 1 patient died due to delay seeking health care, thus, delay management.

Keywords: pachymeningitis, tuberculosis, intracranial hypertension, hypertension, management, case report.

Classification: NLMC CODE: WF 200

Language: English



LJP Copyright ID: 392814

London Journal of Medical and Health Research

Volume 21 | Issue 4 | Compilation 1.0



© 2021, J. Laaguili, Y.C.H. Dokponou, B. El Jebbouri, A.C. El Asri, B. El Mostarchid, M. Gazzaz. This is a research/review paper, distributed under the terms of the Creative Commons Attribution-Noncommercial 4.0 Unported License <http://creativecommons.org/licenses/by-nc/4.0/>, permitting all noncommercial use, distribution, and reproduction in any medium, provided the original work is properly cited.

Hypertrophic Intracranial Pachymeningitis of a Tuberculosis Etiology: Case Report and Systematic Review of the Literature

J. Laaguili^α, Y.C.H. Dokponou^σ, B. El Jebbouri^ρ, A.C. El Asri^ω, B. El Mostarchid[¥], M. Gazzaz[§]

ABSTRACT

Background: Intracranial pachymeningitis is a rare neurological condition and tuberculosis as its etiology is uncommon. In the literature, little information is known about the epidemiological profile, clinical presentation, diagnosis, management, and outcome of patients with pachymeningitis of tuberculous origin.

Methods: The authors present a case of tuberculosis intracranial pachymeningitis with a systematic review of the literature according to the Preferred Reporting Items for Systematic Reviews and Meta - Analyses guidelines. Relevant studies (up to June 2021) that reported patients with intracranial pachymeningitis of tuberculosis origin, were identified from the Google Scholar, PubMed, and Cochrane Library databases.

Results: This systematic review identified 19 patients of whom 11 were male and 8 were female. The mean value of age was 39.42 (Std. Deviation 14.54) years. Eleven patients had intracranial hypertension and hemiparesis while five presented with headache and blurred vision at admission. Surgery was performed in 18 patients. The presence of mycobacterium tuberculosis was not confirmed in one patient treated successfully with the antituberculosis drugs. Furthermore, 18 out of the 19 patients reported improved outcomes, only 1 patient died due to delay seeking health care, thus, delay management.

Conclusion: Tuberculosis as etiology of intracranial pachymeningitis need to be searched in all patient presenting with this condition whether he is coming from a tuberculous endemic region or not.

Keywords: pachymeningitis, tuberculosis, intracranial hypertension, hypertension, management, case report.

Author α σ ρ ω ¥ § χ: Department of Neurosurgery, Mohammed V Military Teaching Hospital Rabat. Mohammed V University, Faculty of Medicine and Pharmacy, Rabat Morocco.

I. INTRODUCTION

Intracranial hypertrophic pachymeningitis was first described by Charcot and Joffroy in 1869. This rare disorder is characterized by inflammation and thickening of dura mater of diverse etiology. Infective cause includes tubercular, syphilis, fungal, cysticercosis, pseudomonas, Lyme disease, and human T- cell lymphotropic virus infection. Although idiopathic variety is seen in most cases it also has been reported with malignancy, after head trauma, intracranial hypotension, autoimmune syndromes like rheumatoid arthritis, Wagner granulomatosis, Sjogren syndrome, sarcoidosis, Takayasu, and temporal arteritis. The main clinical manifestations may include fever, headache, intracranial hypertension syndrome, seizure, blurry vision, motor palsy, or cranial nerve (1–4). These mostly depend on the etiology (whether it is idiopathic or of known cause), the thickness of the abnormally inflamed dura causing compression of anatomic structures, and the topography of the lesion. Nevertheless, rare cases have been reported pointing out tuberculosis as the etiology of this condition.

Idiopathic and Immunoglobulin G4-Related Hypertrophic pachymeningitis confirmed by biopsy sample of the intracranial lesion have been managed with oral steroids and immunomodulators which suppressed the inflammatory markers

and serum biochemistry followed by the reduction in the degree of dural enhancement with clinical improvement in the patient's neurological symptoms. Refractory cases find solutions with rituximab (5–11). Hypertrophic intracranial pachymeningitis can be associated with a variety of medical conditions underlining the complexity of its management.

Some authors have reported cases treated successfully with antituberculosis drugs without any confirmation of mycobacterium tuberculosis isolation (1,12).

In this study, we performed a systematic literature review to evaluate all reported cases with intracranial hypertrophic pachymeningitis of tuberculosis origin and did a meta - analysis of the data. We also reported an illustrative case of a 65-year-old man that was successfully treated with antituberculosis drugs after surgical excision of the lesion.

II. CASE PRESENTATION

A 65-year-old man was admitted to the Neurosurgery Department of Military Teaching Hospital of Rabat with facial palsy. His past medical history was unremarkable. The magnetic resonance imaging (MRI) showed an affected right temporal dural hypertrophied isointense lesion with remarkable contrast enhancement on the T1-weighted and a hypointense lesion with hyperintense edges on the T2 weighted image combined with adjacent cortical thickening (Fig 3) indicating a dense fibrous tissue and inflammatory infiltrates allowing to conclude of a possible intracranial pachymeningitis.

The patient underwent surgery for excision of the right temporal lesion with a dural biopsy sample through craniotomy with a right temporal burr hole. The burr hole was enlarged to expose the maximum diameter of the infiltrated dura matter which was grayish dark in appearance and very tense. We proceed to the coagulation of the dura matter to avoid its bleeding during the procedure. We use a scalpel blade n°11 to open the dura in the crucifix form and milky color material, thick in consistency, pup out and was tightly adherent to the inner surface of the dura matter (Fig 4). The

tissue material was sent to the laboratory for analysis and the direct bacteriological search for an infectious cause was negative. Histopathological examination of the tissue revealed necrotizing granulomatous inflammation (Fig 5), PCR for Mycobacterium tuberculosis DNA was positive on tissue. The patient improved with antituberculosis therapy.

III. METHODOLOGY SYSTEMATIC REVIEW

3.1 Search strategy

We followed the guidelines of the Cochrane Handbook for systematic reviews and metaanalysis of diagnostic test accuracy when conducting this systematic review and meta-analysis. This report was written in accordance with the Preferred Reporting Items for Systematic Review and Meta-Analysis (PRISMA) guidelines (Fig 1), which were adapted for the current review to increase the comprehensiveness and transparency of reporting [13]. We aimed to identify all full-text, peer-reviewed publications pertaining to intracranial pachymeningitis of a tuberculosis etiology. Published studies in English and French pertaining to intracranial pachymeningitis with identification of mycobacterium tuberculosis as the causal agent were found by utilizing a thorough search strategy of the Google Scholar and PubMed databases from inception to June 2021, with no regional restrictions. The following search terms were used: Intracranial pachymeningitis, tuberculosis, facial palsy, management, outcome. We exclude all articles that are not pachymeningitis of intracranial location and those of non - tuberculosis origin.

3.2 Study selection

All the articles resulting from the search were exported into Rayyan (14), where duplicates were identified and deleted. Rayyan is professional research software that is widely used by collaborators for ease of study selection decisions. The study selection process consisted of multiple steps. Firstly, a minimum of two reviewers independently screened the titles and abstracts of the identified articles based on the predefined inclusion and exclusion criteria. Any disagreement bet-

ween the reviewers' decisions prompted further discussion. If a disagreement persisted, a third reviewer resolved the conflicts. The full texts of the remaining articles were also retrieved and screened by a minimum of two reviewers independently.

IV. DATA EXTRACTION

Data extraction was performed in two stages, a pilot stage followed by a proper stage. The pilot stage consisted of having multiple authors, each going through the same 12 selected articles to extract data. This was to ensure that all participant authors were able to extract data accurately to ensure homogeneity in the reporting of the data and to ensure the data collection sheet captured all relevant and important information from the included studies. Studies that met inclusion criteria were read in full, and the following data were extracted, summarized, and tabulated in an Excel proforma sheet: name of the first author, year of publication, age, sex, symptoms, past medical history of tuberculosis, etiology, imaging, the topography of lesion, management, and outcome.

IV. DATA ANALYSIS

Data were manually introduced into the IBM SPSS Statistics Data Editor v.27.0.1 Software and were pooled in the meta-analysis model using “the maximum likelihood ratio” in the Meta Disc software(15). Interregional and intraregional comparisons were made using bivariate tests.

V. RESULTS

The comprehensive search returned 4416 studies and we screened 3538 articles (80.11%) after deduplication. The majority of papers were excluded at the title and abstract screening stage (n= 3247, 91.77%), and the other 255 papers (7.20%) were excluded at full-text screening. Therefore, 12 articles for 19 cases remained for data extraction (0.34%) (Figure 1). The cases were published between 1977 and 2020 with a peak in 1997 (n=7, 36.80%). (Table 1). The patients were 39.42 years old on average (95% CI=32.41-46.43) and most were female 57.9%.

Intracranial hypertension and Hemiparesis were the most common clinical presentation n=11

(57.9%), followed by Headache and blurred vision n=5 (26.3%). Only one case had a past medical history of tuberculosis and mycobacterium tuberculosis was found in almost all of the reported cases n=18 (94.7%). The primary neuroimaging modality was magnetic resonance imaging (MRI) with Hypointense T1 - Hyperintense T2 – weighted in n=9 (47.4%) and Isointense T1 - Hypointense T2 – weighted in n=10 (52.6%). All patients had solitary lesions evenly distributed in occipital n=6 (31.6%), skull base n=5 (26.3%), and frontoparietal n=4 (21.1%). (Table 2) shows the management and outcome distribution of intracranial pachymeningitis of tuberculosis origin, followed by the correlations displays in (Table 3) and (Figure 2).

A Pearson product-moment correlation coefficient was conducted to evaluate the null hypothesis that there is no relationship between the management and outcome of the 19 cases of intracranial pachymeningitis published in the literature (N = 19). Preliminary analysis showed that there were no violations in the assumptions of normality, linearity, or homoscedasticity (see Figure 2 Scatterplot and Table 3). There was significant evidence to reject the null hypothesis and conclude that, there was a strong, positive association between management (M = 0.94, SD = 0.22) and outcome (M = 0.05, SD = 0.22), $r(19) = 0.31, p < 0.01$. The combination of surgical and medical management of intracranial pachymeningitis of tuberculosis origin is associated with the favorable outcome.

VI. DISCUSSION

To our knowledge, this is the first systematic review mapping the intracranial hypertrophic pachymeningitis of tuberculosis origin. We identified and extracted data from 19 cases of 12 studies on the name of the first author, year of publication, age, sex, symptoms, past medical history of tuberculosis, etiology, imaging, the topography of lesion, management, and outcome. There was a female patient predominance in most studies. Most tuberculous intracranial hypertrophic pachymeningitis was diagnosed with a head MRI and

was located in the occipital, skull base, and fronto-parietal region. The preferred treatment modality was a surgical couple with a targeted medical treatment with antituberculosis drugs with a favorable outcome and the patients were discharged after few days of in-hospital care, to continue oral drugs therapy. Only one death was reported due to delay in seeking healthcare. A Bivariate Pearson correlation allowed us to conclude there is a strong correlation between the choice of surgical and medical management of intracranial pachymeningitis of tuberculosis origin and the outcome.

From the 11 cases of hypertrophic cranial pachymeningitis reviewed by *Shobha et al.*, only one was confirmed to be caused by mycobacterium tuberculosis, and it was a female of 34 year old. This female predominance find in our study is also reported in many studies whether of tuberculosis origin or not. Moreover, most of the patients were young adults less than 45 years old (12,16–18). But the MRI findings are very diverse from one study to another. We found isointense T1-weighted and heterogenous T2 weighted lesion while the four previous authors found T1-weighted hyperintense and T2 weighted hypointense lesion. The heterogeneous aspect of our illustrative case can be explained by the presence of calcification inside the lesion significant to understand the chronicity of the lesion. Most authors agreed on the enhancement of the lesion on T1-Gadolinium. The perilesional edema and the bright enhancement with gadolinium contrast can make the imaging confusing with other intracranial tumors like meningioma, mainly when there is obvious dural attachment (12,16,19,20). Nevertheless, the thickening of the dura is usually found in focal and rarely diffuse pachymeningitis. Focal pachymeningitis appears iso signal T1, iso to hyposignal T2, whereas diffuse pachymeningitis is rather hypersignal T2 (17). Our illustrative case is of a category of focal pachymeningitis but we have heterogeneous T2. Likewise in our series, 50% of cases fall in hyperintense T2 while the other 50% showed hypointensity on T2. In magnetization transfer sequences, the visibility of meninges in T1 MT without gadolinium injection is highly suggestive of tuberculous meningitis. There is a signifi-

cant difference in the magnetization transfer ratio (MTR) in the different etiologies. MTR in meningeal thickenings is different in tuberculous origin compared to pyogenic, fungal, or viral etiologies. In T1 MT, the percentage of the difference between the two types of disease was different in signal intensity between meninges and adjacent brain parenchyma (T2 and normal MT) is significantly elevated (>20%) in the tuberculosis group compared to the nontuberculous group and may explain the difference in the visibility of the dura (17,21). The imaging diagnosis of pachymeningeal tuberculosis is important because these patients have been shown to respond well to antitubercular treatment, thus avoiding any surgical intervention (22,23). Many of these lesions share similar imaging characteristics as meningiomas; however, some distinctive imaging findings, specific history, and supportive laboratory findings often assist in reaching an appropriate diagnosis.

Histopathological examination of the tissue revealed necrotizing granulomatous inflammation with central areas of caseous necrosis bordered by granulomas with giant cells and lymphocytes in most cases reported. Only one case was described with status epilepticus as a symptom presented at the admission. There were no specific clinical findings related to intracranial hypertrophic pachymeningeal tuberculosis. The patient was given antitubercular treatment and showed complete resolution of the neurologic findings including the cranial neuropathy. All of the patients improved markedly with antitubercular medication and some authors added steroids for at least six weeks. The medication for tuberculosis was continued from 9 to 12 months with a good response (1,24). In our series, the surgical indication was not only for biopsy to get a sample for laboratory analysis, but the resection of the thickened dura is a way of decompression and reduction of the cortical irritation, thus, participating in the quick relief of the signs and symptoms of the patients. This should explain the tight correlation between the management (surgical and medical) and the good outcome. Moreover, the radiologic evidence of pulmonary tuberculosis was confirmed in only one case in our series; meaning the patient's past

medical history of tuberculosis or contagion is not significant enough to decide whether or not he may develop tuberculous pachymeningitis.

Some authors deal with cases that were managed as tuberculous pachymeningitis just on the basis of strong suspicion since the patient is living in a tuberculous endemic area or based on the clinics and radiological findings. The results are quite acceptable even if it is not an evidence-based practice (8,25–27). This raises the issue of having many more cases of tuberculous pachymeningitis undiagnosed and untreated properly; making our series not exhaustive. Another systematic review could be done to clarify the case of the non-tuberculous pachymeningitis that responded to antitubercular therapy.

Despite a systematic and extensive literature search, the quality of conclusions that can be drawn from this study is limited by the available literature, which was extremely sparse. However, this lack of available literature has served to highlight the underreporting of intracranial hypertrophic pachymeningeal tuberculosis. Moreover, we were only able to include articles published in

English or French. This means literature published in alternative languages such as Spanish and Arabic will have been omitted from our analysis.

Further to the limited number of included articles, only data from Google Scholar and PubMed were captured in this study.

VII. CONCLUSION

There is no specific clinical presentation of intracranial hypertrophic pachymeningitis of tuberculous origin and the iso signal T1 and hyposignal to heterogeneous T2 on the MRI with a thickened dura is a keynote to redirect our diagnosis to intracranial hypertrophic pachymeningeal tuberculosis based on the clinical presentation and to be confirmed by histopathological findings. Surgical excision of the lesion coupled with a 9 to 12 months course of the antitubercular drug is necessary for a better outcome.

Informed Consent: The patient gave his informed consent to publish his case.

Conflicts of Interest: The authors declare that they have no conflicts of interest.

Table 1: Characteristics of intracranial tuberculous pachymeningitis in the literature

Characteristic	Frequency (Percentage)
First Author	
Aggarwal	1 (5.3)
Akhaddar	1 (5.3)
Fonseka	1 (5.3)
Goyal	7 (36.8)
Jacques	1 (5.3)
Kettani	1 (5.3)
ParneyIan	1 (5.3)
Sharma	1 (5.3)
Shobha	1 (5.3)
Tariq	1 (5.3)
Voider	2 (10.5)
Yamashita	1 (5.3)
Publication year	
1977-1997	11 (57.9)
1998-2008	2 (10.5)
2009-2019	5 (26.3)
2020	1 (5.3)
Symptoms	

Facial palsy	1 (5.3)
Headache - blurred vision	5 (26.3)
Fever - Seizure	1 (5.3)
Facial palsy - Seizure	1 (5.3)
Intracranial hypertension - Hemiparesis	11 (57.9)
Imaging findings	
Hypointense T1 - Hyperintense T2 - Enhancement	9 (47.4)
Isointense T1 - Hypointense T2 - Enhancement	10 (52.6)
Location of lesion	
Frontal	
Fronto-parietal	1 (5.3)
Temporal	4 (21.1)
Occipital	1 (5.3)
Skull base	6 (31.6)
Fronto-temporal	5 (26.3)
	2 (10.5)

Table 2: Management and outcome of tuberculosis pachymeningitis in the Literature

Management (Mean = 0.97)		Outcome (Mean=0.05)		Lower limit 95% CI of mean	Upper limit 95% CI of mean
Medical	5.3%			0.83	1.05
Surgical & Medical	94.7%	Favorable	94.7%		
		Non-favorable	5.3%	-0.05	0.16

Table 3: Correlations

		Management	Outcome
Management	Pearson Correlation	1	,056
	Sig. (2-tailed)		,821
	N	19	19
Outcome	Pearson Correlation	,056	1
	Sig. (2-tailed)	,821	
	N	19	19



Fig. 1. Intracranial pachymeningitis of a tuberculosis etiology search strategy using PRISMA flowchart

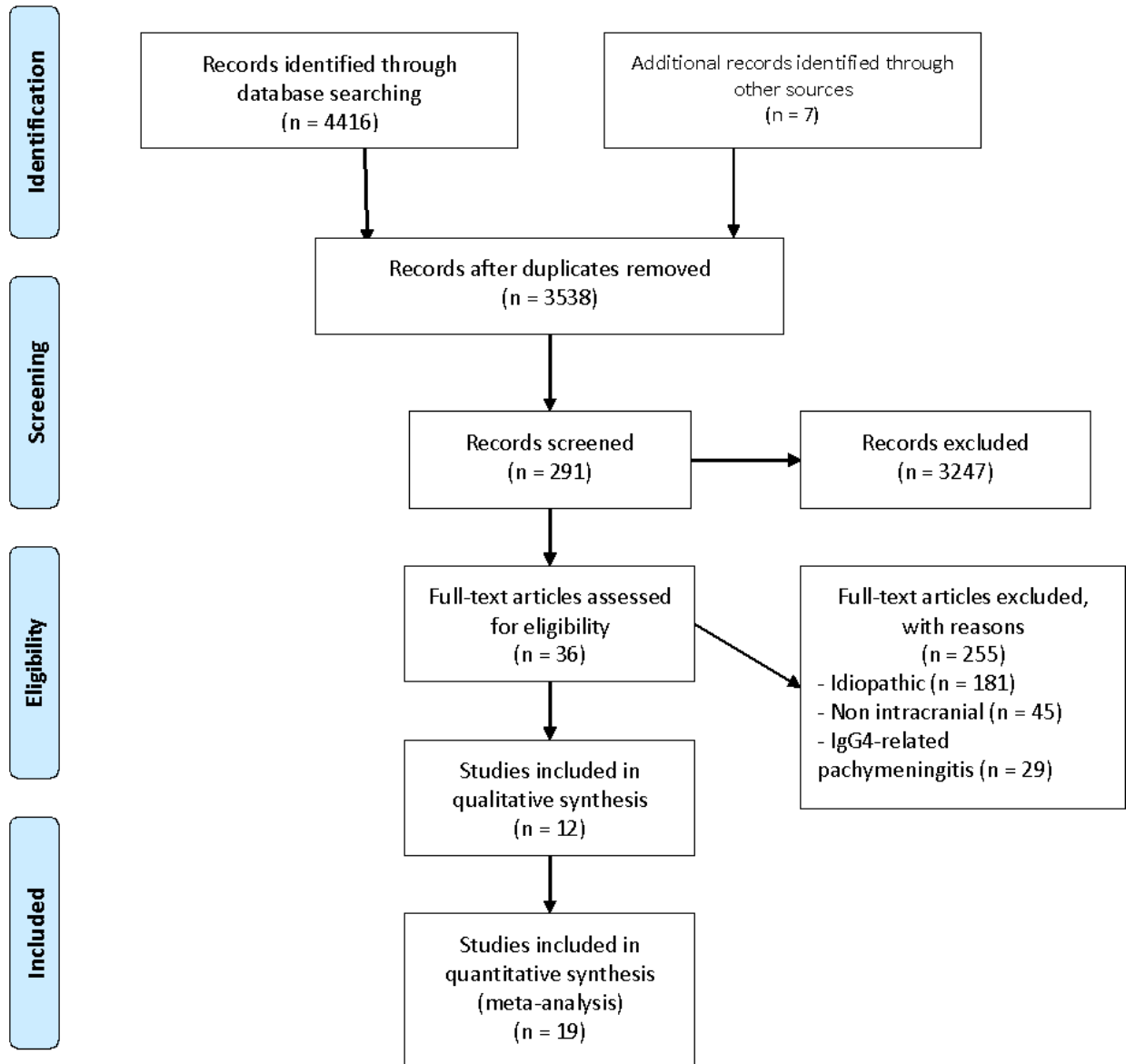


Figure 1: Search Strategy of PRISMA flow chart

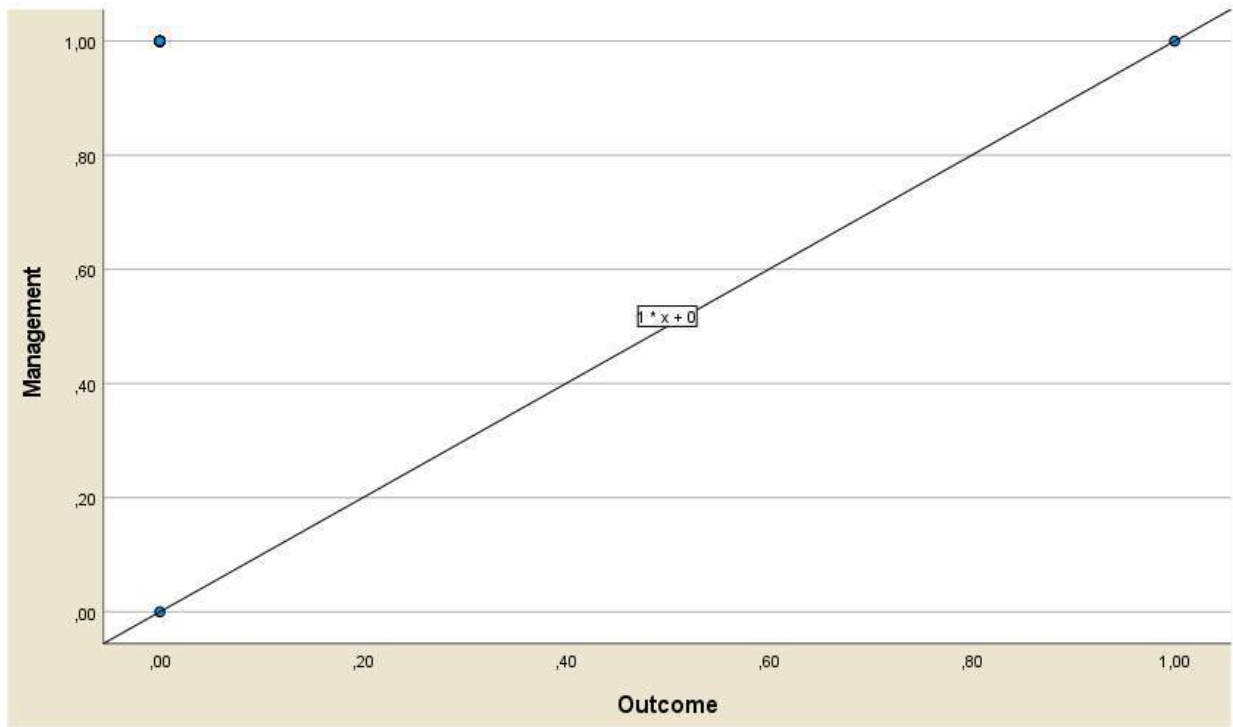
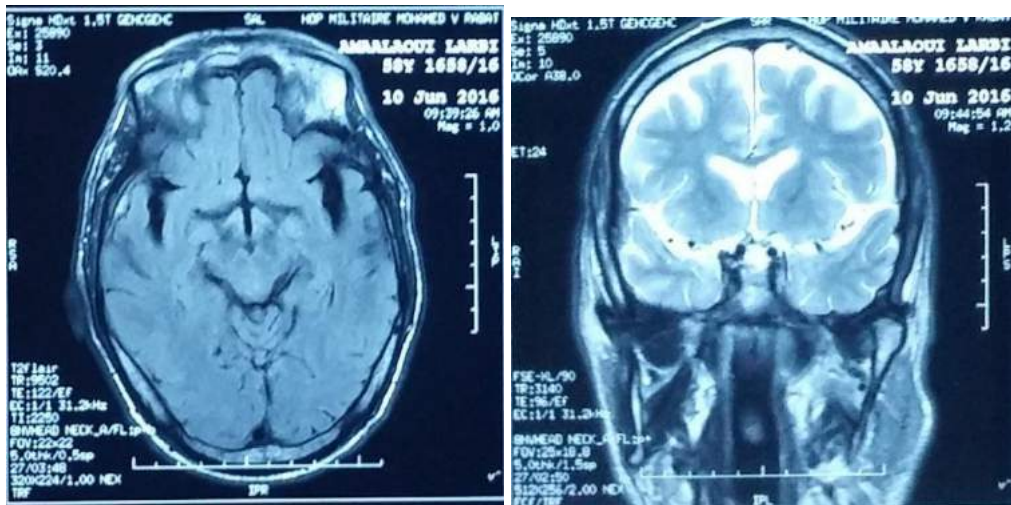
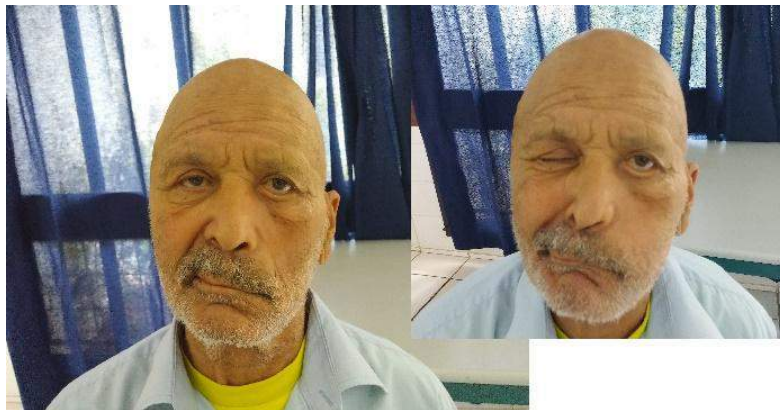

Figure 2: Correlations of management and outcome



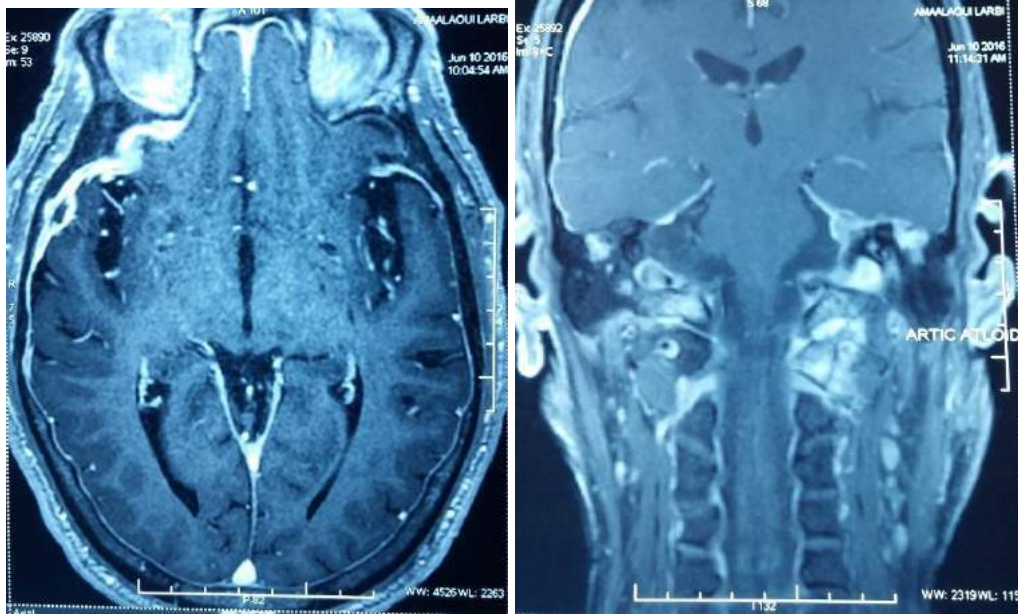


Figure 3: Facial palsy and MRI

A/ Facial palsy; **B-C-D-E/** Brain MRI showing (white arrow) respectively T1-weighted temporal low intensity lesion, T2-weighted heterogenous lesion, T1-Gadolinium highly enhanced lesion, and heterogenous FLAIRE

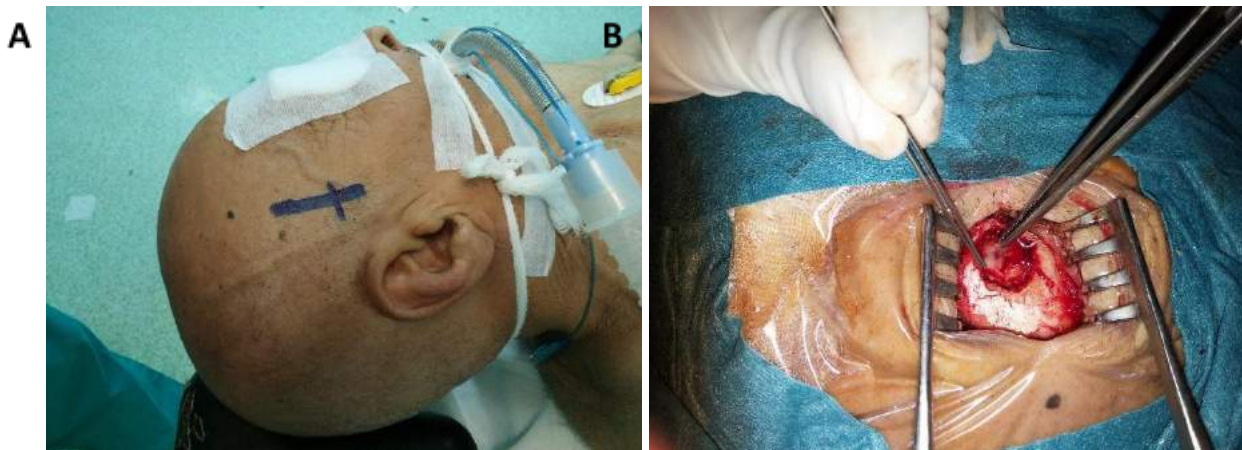

Figure 4: Per-operative excision of the lesion

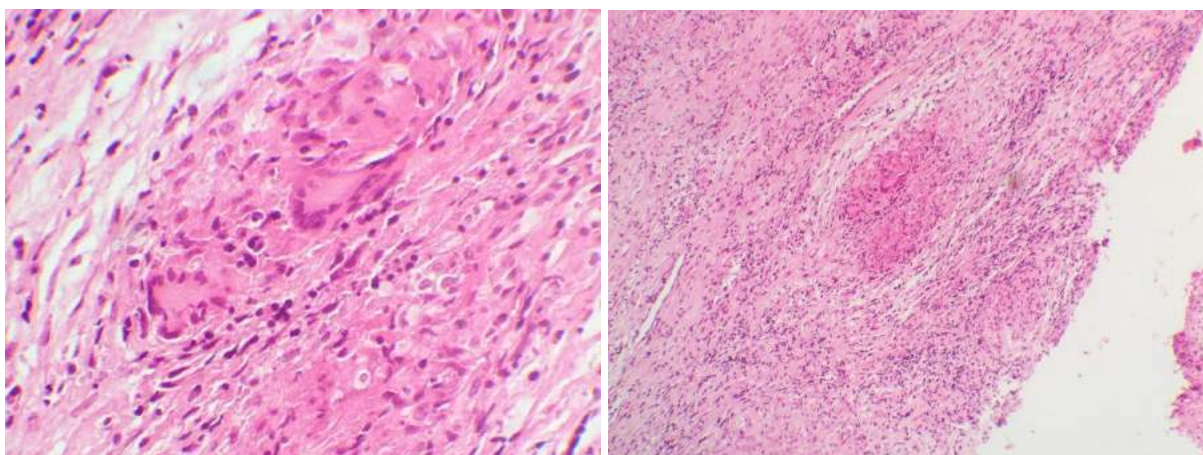


Figure 5: Histopathological result

[Hypertrophic Intracranial Pachymeningitis of a Tuberculosis Etiology: Case Report and Systematic Review of the Literature](#)

A/ (haematoxylin and eosin) X 100: photomicrograph of the surgical specimen showing perivascular and diffuse lymphoplasmacellular infiltrates and vascularised fibrous tissue surrounding meningotheelial proliferates. **B/** Necrotizing granuloma with giant cells in a dense fibrous tissue infiltrated by polymorphs, eosinophils and plasma cells (X 100).

REFERENCES

- Sharma PK, Saikia B, Sharma R, Gagneja V, Khilnani P. Pachymeningitis in a Young Child Responded to Antitubercular Therapy: A Case Report. *J Child Neurol.* 2014 Oct;29(10):NP9 2-5.
- Abouzaid CH, Kissani N, Essaadouni L. Pachyméningite crânienne et syndrome de Gougerot-Sjögren primitif. *Revue Neurologique.* 2011;167(4):348–51.
- Navalpotro-Gómez I, Vivanco-Hidalgo RM, Cuadrado-Godia E, Medrano-Martorell S, Alameda-Quitllet F, Villalba-Martínez G, et al. Focal status epilepticus as a manifestation of idiopathic hypertrophic cranial pachymeningitis. *Journal of the Neurological Sciences.* 2016 Aug;367:232–6.
- El Aoud S, Frikha F, Ben Salah R, Snoussi M, Bahloul Z. Paralysie multiple des nerfs crâniens révélant une pachyméningite à ANCA. *La Revue de Médecine Interne.* 2013 Jun;34:A130.
- Deprez M, Born J, Hauwaert C, Otto B, Reznik M. Idiopathic hypertrophic cranial pachymeningitis mimicking multiple meningiomas: case report and review of the literature:5.
- Bosman T, Simonin C, Launay D, Caron S, Destée A, Defebvre L. Idiopathic hypertrophic cranial pachymeningitis treated by oral methotrexate: a case report and review of literature. *Rheumatol Int.* 2008 May;28(7):713–8.
- Tuncel D, Yücesan C, Erden E, Savaş A, Erden İ, Mutluer N. Idiopathic hypertrophic cranial pachymeningitis with perifocal brain edema. *Clinical Neurology and Neurosurgery.* 2005 Apr;107(3):249–52.
- NAKAZAKI H, TANAKA T, ISOSHIMA A, HIDA T, NAKAJIMA M, ABE T. Idiopathic Hypertrophic Cranial Pachymeningitis with Perifocal Brain Edema—Case Report—. *Neurologia medico-chirurgica.* 2000;40(4):239–43.
- Hatano N, Behari S, Nagatani T, Kimura M, Ooka K, Saito K, et al. Idiopathic Hypertrophic Cranial Pachymeningitis: Clinicoradiological Spectrum and Therapeutic Options. *Neurosurgery.* 1999 Dec;45(6):1336–44.
- Mamelak AN, Kelly WM, Davis RL, Rosenblum ML. Idiopathic hypertrophic cranial pachymeningitis: report of three cases. *Journal of neurosurgery.* 1993;79(2):270–6.
- Kupersmith MJ, Martin V, Heller G, Shah A, Mitnick HJ. Idiopathic hypertrophic pachymeningitis. *Neurology.* 2004;62(5):686–94.
- Shobha N, Mahadevan A, Taly AB, Sinha S, Srikanth SG, Satish S, et al. Hypertrophic cranial pachymeningitis in countries endemic for tuberculosis: Diagnostic and therapeutic dilemmas. *Journal of Clinical Neuroscience.* 2008 Apr;15(4):418–27.
- Leeflang MMG. Systematic reviews and meta-analyses of diagnostic test accuracy. *Clinical Microbiology and Infection.* 2014;20 (2):10513.
- Ouzzani M, Hammady H, Fedorowicz Z, Elmagarmid A. Rayyan—a web and mobile app for systematic reviews. *Systematic reviews.* 2016;5(1):1–10.
- Gray CD, Kinnear PR. *IBM SPSS statistics 19 made simple.* Psychology Press; 2012.
- Parney IF, Johnson ES, Allen PBR. “Idiopathic” Cranial Hypertrophic Pachymeningitis Responsive to Antituberculous Therapy: Case Report. *Neurosurgery.* 1997 Oct 1;41(4):96571.
- Ech-Cherif El Kettani N, Regragui W, Arkha Y, Ait Benhaddou E, Fikri M, Benomar A, et al. Les pachyméningites intracrâniennes : aspects TDM et IRM. *Feuillets de Radiologie.* 2012 Oct; 52(5):263–72.
- Goyal M, Sharma A, Mishra NK, Gaikwad SB, Sharma MC. Imaging appearance of pachymeningeal tuberculosis. *AJR American journal of roentgenology.* 1997;169(5):1421–4.

19. Akhaddar A, Rharrassi I. Hypertrophic cranial pachymeningitis coinfection with tuberculosis and actinomycosis. *Surgical Neurology International*. 2020 Jul 18;11:201.
20. Jung YH, Lee MJ, Lee C, Cha J, Chung C-S. Granulomatosis With Polyangiitis - Associated Hypertrophic Pachymeningitis Mimicking Spontaneous Intracranial Hypotension: A Case Report: Headache. *Headache: The Journal of Head and Face Pain*. 2017 Mar;57(3):488–93.
21. Aggarwal A, Patra DP, Gupta K, Sodhi HB. Dural Tuberculoma Mimicking Meningioma: A Clinicoradiologic Review of Dural En-Plaque Lesions. *World Neurosurgery*. 2016 Apr;88:686.e1-686.e7.
22. Jinkins JR. Computed tomography of intracranial tuberculosis. *Neuroradiology*. 1991;33(2):126–35.
23. Callebaut J, Dormont D, Dubois B, Chiras J, Bories J. Contrast-enhanced MR imaging of tuberculous pachymeningitis cranialis hypertrophica: case report. *American Journal of Neuroradiology*. 1990;11(4):821–2.
24. Fonseka CL, Kanakkahewa TE, Singhapura SD AL, Hewavithana JS, Kolambage LP, Herath HMM, et al. Tuberculous Pachymeningitis Presenting as a Diffused Dural Thickening in a Patient with Chronic Headache and Recurrent Neurological Abnormalities for More than a Decade: A Case Report and a Review of the Literature. *Case Reports in Infectious Diseases*. 2018 Oct 1;2018:1–5.
25. Chen H, Gnepp D, Paul J, Borra S. A mysterious back pain. *Journal of Postgraduate Medicine*. 2014 Jan 1;60(1):61.
26. Senapati SB, Mishra SS, Das S, Parida DK, Satapathy MC. Cranio cervical tuberculous hypertrophic pachymeningitis. *Surg Neurol Int*. 2014 Apr 16;5:52.
27. Thurtell MJ, Keed ABR, Yan M, Gottlieb T, Spies JM, Halmagyi GM. Tuberculous cranial pachymeningitis. *Neurology*. 2007 Jan 23;68(4):298–300.

This page is intentionally left blank



Scan to know paper details and author's profile

Non Traumatic Acute Subdural Hematoma Revealing an Intracranial Arteriovenous Malformations: Case Report and Review of Literature

Zineb Siba, Yao Christian Hugues Dokponou, Abad Cherif EL Asri, Brahim EL Mostarchid & Gazzaz Miloud

Mohamed V University

ABSTRACT

Intracranial arteriovenous malformation (AVM) is an abnormal connection of blood vessels, arteries and veins without capillary bed or neural parenchyma. This condition is commonly revealed by seizures, and also intraparenchymal, subarachnoid, and intraventricular hemorrhage. Subdural haematoma is rarely associated with a dural arteriovenous malformation. We report a case of a 53 - year - old man who was admitted to the emergency department with sudden loss of consciousness and coma. The brain CT Scan and CT angiography show left frontal intraparenchymal hematoma of 35 X 43 X 25 mm associated with left hemispheric subdural hematoma. The patient completely recovered after decompressive craniotomy followed by the embolization of the nidus.

Keywords: arteriovenous malformation, subdural hematoma, endovascular treatment.

Classification: NLMC CODE: WL 340

Language: English



LJP Copyright ID: 392815

London Journal of Medical and Health Research

Volume 21 | Issue 4 | Compilation 1.0



© 2021, Zineb Siba, Yao Christian Hugues Dokponou, Abad Cherif EL Asri, Brahim EL Mostarchid & Gazzaz Miloud. This is a research/review paper, distributed under the terms of the Creative Commons Attribution-Noncommercial 4.0 Unported License (<http://creativecommons.org/licenses/by-nc/4.0/>), permitting all noncommercial use, distribution, and reproduction in any medium, provided the original work is properly cited.

Non Traumatic Acute Subdural Hematoma Revealing an Intracranial Arteriovenous Malformations: Case Report and Review of Literature

Zineb Siba^α, Yao Christian Hugues Dokponou^σ, Abad Cherif EL Asri^ρ, Brahim EL
Mostarchid^ω & GAZZAZ Miloud^{*}

ABSTRACT

Intracranial arteriovenous malformation (AVM) is an abnormal connection of blood vessels, arteries and veins without capillary bed or neural parenchyma. This condition is commonly revealed by seizures, and also intraparenchymal, subarachnoid, and intraventricular hemorrhage. Subdural haematoma is rarely associated with a dural arteriovenous malformation. We report a case of a 53 - year - old man who was admitted to the emergency department with sudden loss of consciousness and coma. The brain CT Scan and CT angiography show left frontal intraparenchymal hematoma of 35 X 43 X 25 mm associated with left hemispheric subdural hematoma. The patient completely recovered after decompressive craniotomy followed by the embolization of the nidus.

Keywords: arteriovenous malformation, subdural hematoma, endovascular treatment.

Author α σ ρ ω *: Department of Neurosurgery, Mohammed V Military Teaching Hospital Rabat. Mohammed V University, Faculty of Medicine and Pharmacy, Rabat Morocco.

I. INTRODUCTION

Subdural hematomas (SDHs) are the most common form of intracranial injuries that occur as a result of head trauma. SDHs result from rupture of the veins traversing the subdural space en route to the venous sinuses of the dura mater. This condition is rarely found to be associated with arteriovenous malformation (AVM). These have been classified angiographically on the basis of their arterial supply into pial, dural, and mixed

pial-dural types. The dural type comprises 10 to 15% of intracranial arteriovenous malformations (1,2). Dural arteriovenous fistulae of the anterior cranial fossa are rare (5.8%) but they have an usually high incidence of sudden massive intracranial hemorrhage (62-91%) (3-5). Its association with the ASDH is uncommon. The clinical presentation in most cases is headache and the treatment of dural AVM with cortical venous drainage is aimed at occlusion of the venous drainage or occlusion of all arterial supply, and can be surgical, endovascular, or a combination of both.

We report an unusual case of dural AVM presenting as acute subdural hematoma (ASDH) and discuss the clinical features and treatment options with the aid of a literature review.

II. CASE PRESENTATION

A 53-year-old man with a past medical history of hypothyroidism treated with levothyrox was admitted to the emergency department with sudden loss of consciousness without seizures. The physical examination found a comatose patient with a Glasgow Coma Scale (GCS) of 7/15, he has a stable respiratory rate as well as hemodynamic, the pupillary are equal in size and reactive. His body temperature was 37.5° C, with normal laboratory blood work up. There was no neurological deficit.

The brain CT Scan showed left frontal spontaneously hyperdense lesion measuring about 46 X 33 X 20 mm being the intracerebral hemorrhage (ICH) associated with acute subdural hematoma

(ASDH) of the left convexity about 12 mm of thickness and having mass effect on the homolateral lateral ventricle with the middle line shift up to 8 mm followed by brain herniation under false cerebri (Fig 1 A/). CT angiography confirms the previous findings and evaluates the ICH volume to be 19 cm³. At the arterial time acquisition there was a central lesion to the intraparenchymal hematoma that was brightly enhanced with some drainage veins toward the superior longitudinal sinus making the suspicion of a possible dural arteriovenous fistula.

The patient was rushed to the operating theater where he underwent surgery for the evacuation of the compressive subdural hematoma and the ICH by the decompressive craniotomy of 14 X 12 cm bone flap. He did well in the post - operative period by regaining consciousness with a GCS of 15/15 without sensitive nor motor palsy (Fig 1 B/).

After dealing successfully with the emergency condition, a brain MRI and cerebral arteriography was done that confirmed the diagnosis of left fronto-insular AVM made of 2.5 cm nidus with the feeding arteries from the frontal branches of the middle cerebral artery and its drainage was mainly through the frontal and cortical veins of the middle cerebral vein into the superior longitudinal sinus (Fig 2). The patient underwent endovascular treatment. The nidus is catheterized with a Marathon microcatheter followed by injection of a total of 1.5 cc of Onyx. A homogeneous and compact filling of the nidus is obtained with the beginning of reflux in the drainage veins. The controls show a total exclusion of the nidus with restoration of venous return (Fig 3). The postoperative period was eventless and the patient was discharged 5 days later. He was doing well at the follow-up appointment of 3 months.

Table 1: Non-traumatic acute subdural hematoma revealing an intracranial arteriovenous malformations

1st author/ year	Age/ Sexe	Clinical presentation	ICH	SDH	AVM	Treatment	Outcome
Ogawa/ 2010 (6)	27/M	Headache	No	Convexity	Convexity	Surgical	Improved
Duffau/ 1999 (7)	64/M	Headache	Frontal	Frontal	ACF	Surgical	Improved
Kitazono/ 2010 (8)	68/M	Headache	Occipital	Occipital	Occipital	Surgical	Improved
Ito/ 1983 (9)	64/M	Unconsciousness	No	Frontal	ACF	Surgical	Improved
Kohyama/ 2009 (10)	60/M	Headache	No	Convexity	Convexity	Endovascular & Surgical	Improved
Kominato/ 2004 (11)	42/F	Unconsciousness & Coma	Temporal	Convexity	Temporal	None	Died
Duffau/ 1999 (7)	64/M	Hemiparesis	Temporal	Temporal	Temporal	Endovascular & Surgery	Died
Halbach/ 1988 (12)	48/F	Headache & Weakness	No	Convexity	Convexity	Endovascular	Improved
Ogawa/2010 (6)	27/M	Headache	Convexity	Convexity	Convexity	Endovascular	Improved
Saito/2014 (13)	56/M	Unconsciousness & Coma	Occipital	Occipital	Occipital	Endovascular & Surgery	Improved
Choi et Cho/2010 (5)	85/M	Unconsciousness	Frontal	Frontal	ACF	Surgical	Improved
Maiuri/ 2001 (4)	59/F	Headache, visual disturbances and loss of memory	No	Parietal	Occipital	Endovascular	Improved
Rengachary/1981 (14)	50/M	Grand mal seizure & Coma	No	Convexity	Temporal	None	Died
Rengachary/1981 (14)	61/M	TBI & Unconsciousness	No	Convexity	ACF	None	Died
Li/2019 (15)	45/M	Headache	No	Convexity	Occipital	Endovascular	Improved
Solis/1977 (16)	48/M	Headache & Severe right facial pain	No	Occipital	Occipital	Surgery	Improved

ACF = anterior cranial fossa, AVM = arteriovenous malformation, SDH = subdural hematoma

III. DISCUSSION

To discuss the clinical features and treatment options, we reviewed 16 cases of nontraumatic acute subdural hematoma revealing intracranial arteriovenous malformations from the previous literature. (table 1). Nine of the 16 cases were presented with headache and 5 with loss of consciousness while only one clinical presentation was seizure. In our present case, the patient never complained of headache but presented with a sudden loss of consciousness and coma. This is obviously secondary to the intracranial hypertension caused by the ICH and the ASDH. Thus, there is no specific clinical presentation for the intracranial AVM in the setting of ASDH. Saito et al. explained the ASDH by the theory of venous ectasias that might have had a fragile venous wall and was suspected of being a rupture point. The hemorrhagic pattern showed that the dominant location was subdural hematoma associated with a small amount of subcortical hematoma. The hemorrhagic point might be the subpial cortical vein draining into the superior sagittal sinus under venous high pressure due to arterial shunt flow. Rupture of the subpial vein might cause both laceration of arachnoid and cortical surfaces. A further hypothesis is that venous high pressure might aggravate cortical reflux and partial venous congestion might cause limited subcortical hemorrhage and simultaneously rupture at the fragile wall of the venous ectasias in the subdural space. Three patients out of the sixteen underwent surgery coupled with endovascular treatment, and six of them benefit from surgery with good outcome, while four had endovascular treatment exactly like the patient of our present case that underwent endovascular treatment with an uneventful postoperative period. Surgical, endovascular, and radiosurgical management of AVMs depends on the size of the nidus and also its location; whether it is located in a functional or not functional brain structure. Our review has shown that a good outcome can be reached by the combination of these therapeutic means.

IV. CONCLUSION

AVMs have various clinical manifestations, including acute subdural hematoma which is a

mode of revelation rarely reported in the literature and for which diagnostic and therapeutic management remains of major interest for the patient's vital prognosis. Concerning our patient, initially admitted in critical neurological condition, he underwent surgical treatment combined with early endovascular treatment with full recovery.

REFERENCES

1. Houser OW, Baker Jr HL, Rhoton Jr AL, Okazaki H. Intracranial dural arteriovenous malformations. *Radiology*.1972;105(1):55–64.
2. Rosenblum B, Oldfield EH, Doppman JL, Di Chiro G. Spinal arteriovenous malformations: a comparison of dural arteriovenous fistulas and intradural AVM's in 81 patients. *Journal of neurosurgery*.1987;67 (6):795–802.
3. Halbach VV, Higashida RT, Hieshima GB, Wilson CB, Barnwell SL, Dowd CF. Dural arteriovenous fistulas supplied by ethmoidal arteries. *Neurosurgery*. 1990;26(5):8 16–23.
4. Maiuri F, Iaconetta G, Sardo L, Briganti F. Dural arteriovenous malformation associated with recurrent subdural haematoma and intracranial hypertension. *British journal of neurosurgery*. 2001;15(3):273– 6.
5. Choi HJ, Cho CW. Anterior cranial fossa dural arteriovenous fistulae presenting as subdural hematoma. *Journal of Korean Neurosurgical Society*. 2010;47(2):155.
6. Ogawa K, Oishi M, Mizutani T, Maejima S, Mori T. Dural arteriovenous fistula on the convexity presenting with pure acute subdural hematoma. *Acta neurologica belgica*. 2010;110(2):190.
7. Duffau H, Lopes M, Janosevic V, Sichez J-P, Faillot T, Capelle L, et al. Early rebleeding from intracranial dural arteriovenous fistulas: report of 20 cases and review of the literature. *Journal of neurosurgery*. 1999;90(1):78–84.
8. Kitazono M, Yamane K, Toyota A, Okita S, Kumano K, Hashimoto N. A case of dural arteriovenous fistula associated with subcortical and subdural hemorrhage. *No shi-nkei geka Neurological surgery*. 2010;38 (8): 757–62.
9. Ito J, Imamura H, Kobayashi K, Tsuchida T, Sato S. Dural arteriovenous malformations of

- the base of the anterior cranial fossa. *Neuroradiology*. 1983;24(3):149–54.
10. Kohyama S, Ishihara S, Yamane F, Kanazawa R, Ishihara H. Dural arteriovenous fistula presenting as an acute subdural hemorrhage that subsequently progressed to a chronic subdural hemorrhage: case report. *Minimally Invasive Neurosurgery*. 2009;52(01):36–8.
 11. Kominato Y, Matsui K, Hata Y, Matsui K, Kuwayama N, Ishizawa S, et al. Acute subdural hematoma due to arteriovenous malformation primarily in dura mater: a case report. *Legal Medicine*. 2004;6(4):256–60.
 12. Halbach VV, Higashida RT, Hieshima GB, Rosenblum M, Cahan L. Treatment of dural arteriovenous malformations involving the superior sagittal sinus. *American journal of neuroradiology*. 1988;9(2):337–43.
 13. Saito A, Kawaguchi T, Sasaki T, Nishijima M. A case of dural arteriovenous fistula presenting as acute subdural hematoma. *Case reports in neurology*. 2014;6(1):122–5.
 14. Rengachary SS, Szymanski DC. Subdural hematomas of arterial origin. *Neurosurgery*. 1981;8(2):166–72.
 15. Li G, Zhang Y, Zhao J, Zhu X, Yu J, Hou K. Isolated subdural hematoma secondary to Dural arteriovenous fistula: a case report and literature review. *BMC neurology*. 2019;19(1):1–6.
 16. Solis OJ, Davis KR, Ellis GT. Dural arteriovenous malformation associated with subdural and intracerebral hematoma : a CT scan and angiographic correlation. *Computerized tomography*. 1977;1(2):145–50.

Disclosure

The authors did not receive any funding for the preparation of this case report.

This article is an original work that is not being considered or reviewed by any other publication, and has not been published elsewhere in the same or a similar form.

All authors of the manuscript have read and agreed to its content and are accountable for all aspects of the accuracy and integrity of the manuscript.

Informed Consent: The patient gave his informed consent to publish his case.

Conflicts of Interest: The authors declare that they have no conflicts of interest.

Ethics and reporting guidelines

Informed consent and verbal permission were obtained from the patient prior to the submission of this article. Also, this article respects both the Consensus based Clinical Case Reporting Guideline and the Recommendations for the Conducting, Reporting, Editing, and Publication of Scholarly Work in Medical Journals.

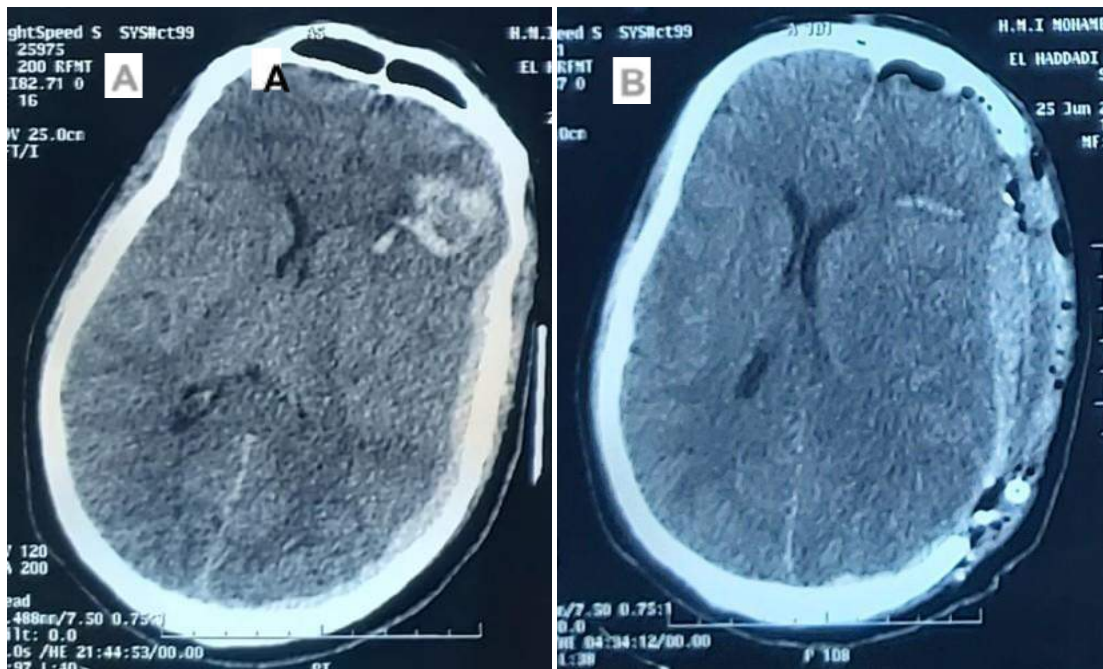


Figure 1: A/ Head CT shows a spontaneous hyperdense ASDH of 12mm thickness on the left hemisphere with 8mm midline shift. Diffuse brain edema. B/ Postoperative axial head CT-Scan after decompressive craniotomy and evacuation of the ASDH and also the ICH

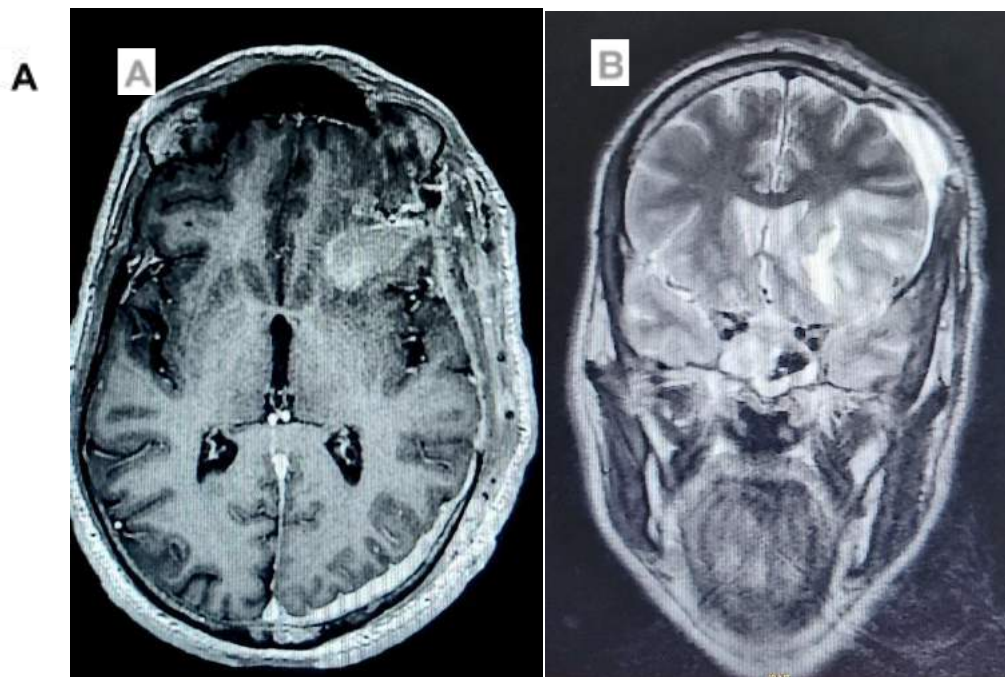


Figure 2: Head magnetic resonance imaging; A/ axial T1-Weighted, B/ coronal T2- Weighted with the left frontal ICH with the and the ASDH

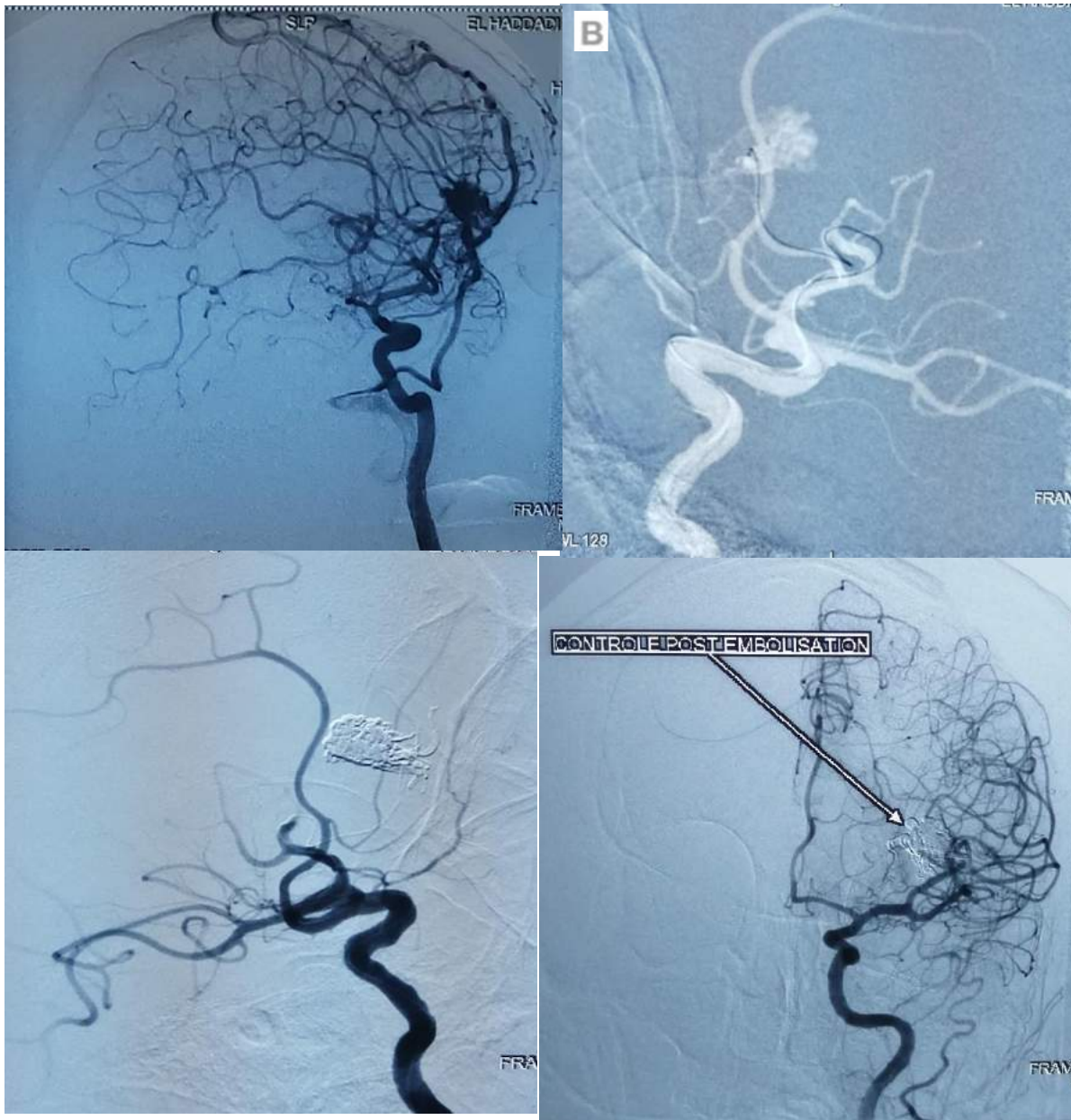


Figure 3: A/ Left internal carotid artery angiography, anteroposterior and lateral view revealing left fronto-insular arteriovenous malformation supplied from the insular branch of the left middle cerebral artery (circle). B/ Injection of embolization material (Onyx) C/ Exclusion of the nidus. D/ **Angiographical** control of the nidus after embolization



Scan to know paper details and
author's profile

Stereotactic Management of a Parafalcine Subdural Empyema: Case Report and Review of the Literature

Yao Christian Hugues Dokponou, Inas El Kacemi, Salami Mohcine, Fernand Nathan Imoumby, Abad Cherif El Asri, Brahim Mostarchid & Miloud Gazzaz

Mohamed V University

ABSTRACT

Background: Parafalcine subdural empyema, a collection of pus in the space between the dura and arachnoid alongside the falx cerebri, is a rare type of intracranial suppuration. The surgical management of subdural empyema has been an evacuation of the pus through a bone flap after a craniectomy, or craniotomy, or its aspiration by a burr hole. Meanwhile, the parafalcine location of the empyema, makes its evacuation tricky and need a simple and more safe surgical procedure.

Observations: We report a case of a 25-year-old man with a past medical history of sinusitis, admitted for parafalcine subdural empyema that was successfully managed by stereotactic aspiration of the pus.

Lessons: The Leksell stereotactic management of a parafalcine subdural empyema is a way forward as an adequate, safe, costless, and replicable surgical procedure allowing a complete evacuation of the pus.

Keywords: arteriovenous malformation, subdural hematoma, endovascular treatment.

Classification: NLMC CODE: WF 745

Language: English



LJP Copyright ID: 392816

London Journal of Medical and Health Research

Volume 21 | Issue 4 | Compilation 1.0



© 2021, Yao Christian Hugues Dokponou, Inas El Kacemi, Salami Mohcine, Fernand Nathan Imoumby, Abad Cherif El Asri, Brahim Mostarchid & Miloud Gazzaz. This is a research/review paper, distributed under the terms of the Creative Commons Attribution-Noncommercial 4.0 Unported License <http://creativecommons.org/licenses/by-nc/4.0/>), permitting all noncommercial use, distribution, and reproduction in any medium, provided the original work is properly cited.

Stereotactic Management of a Parafalcine Subdural Empyema: Case Report and Review of the Literature

Yao Christian Hugues Dokponou^α, Inas El Kacemi^σ, Salami Mohcine^ρ, Fernand Nathan Imoumby^ω, Abad Cherif El Asri[¥], Brahim Mostarchid[§] & Miloud Gazzaz^χ

ABSTRACT

Background: Parafalcine subdural empyema, a collection of pus in the space between the dura and arachnoid alongside the falx cerebri, is a rare type of intracranial suppuration. The surgical management of subdural empyema has been an evacuation of the pus through a bone flap after a craniectomy, or craniotomy, or its aspiration by a burr hole. Meanwhile, the parafalcine location of the empyema, makes its evacuation tricky and need a simple and more safe surgical procedure.

Observations: We report a case of a 25-year-old man with a past medical history of sinusitis, admitted for parafalcine subdural empyema that was successfully managed by stereotactic aspiration of the pus.

Lessons: The Leksell stereotactic management of a parafalcine subdural empyema is a way forward as an adequate, safe, costless, and replicable surgical procedure allowing a complete evacuation of the pus.

Keywords: subdural empyema, parafalcine suppuration, stereotactic aspiration.

Author ^α ^σ ^ρ ^ω [¥] [§] ^χ: Department of Neurosurgery, Mohammed V Military Teaching Hospital Rabat, Morocco.

I. INTRODUCTION

Subdural empyema is defined as a purulent collection between dura mater and arachnoid, occupying the inner surface of the dura mater and the outer surface of the arachnoid layer. It is a rare but potentially life-threatening disease. It is called

parafalcine when the purulent collections accumulate between the falx cerebri and the medial surface of the cerebral hemisphere spreading most time to the brain convexity (1–3). This is a quite rare phenomenon caused most commonly by sinusitis, otitis media, meningitis, operative infection, head trauma, and bacteremic seeding of previous subdural hematoma.

Parafalcine - located subdural empyema can present without presence of clear localizing symptoms or signs like meningeal irritation and increased intracranial pressure (4). There is no specific clinical presentation but the patient's immediate past medical history can help to strongly suspect the disease. The aim of this paper is to report an unusual case of parafalcine subdural empyema and discuss the clinical features and treatment options with the aid of a literature review.

II. CASE PRESENTATION

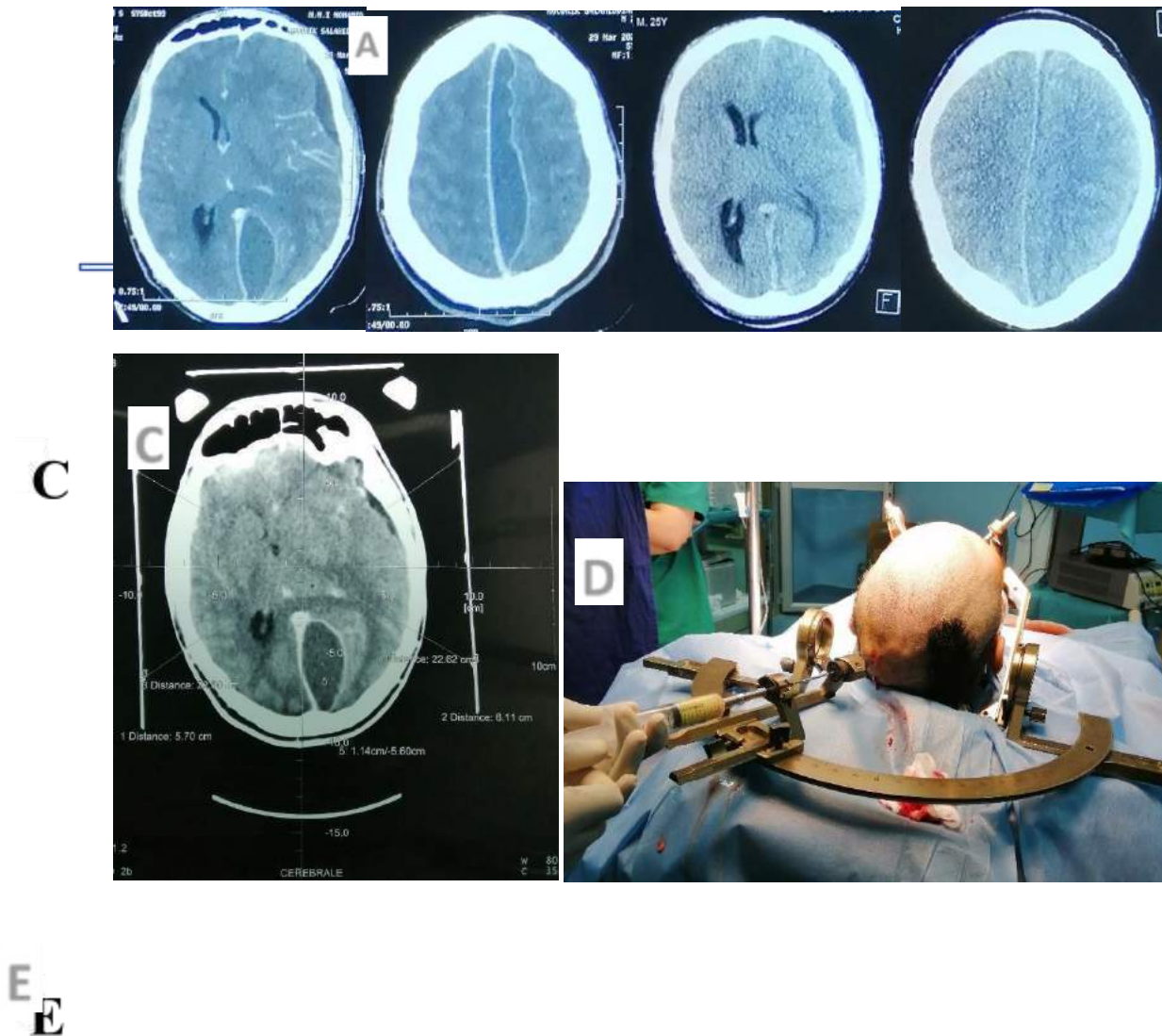
A 25 years old man was admitted for severe headache, diplopia, and vomiting. The patient was treated, three weeks earlier, in the department of ENT for sinusitis. Physical examination revealed hyperthermia (T= 38.6°C), and right sided hemiparesis of 3/5. The blood sample result was WBC 18.000, CRP 200.

Cerebral CT-Scan showed a parafalcine collection extending to the left tentorial cerebelli and measuring 10 mm of maximum thickness exerting a discreet mass effect with the midline shift of 6.6mm (Fig1 A/).

The patient underwent a stereotactic evacuation of the intracranial collection. He was taken to the CT-Scan where we first did the head scan with injection of contrast (Iodine saline), then different

measurement was done in the three-dimensional plan X, Y, Z to stereotactically localized the lesion to be punctured without causing damage to other functional brain structures (Fig1 C/). This draws the passage of the stereotactic percutaneous needle biopsy. The patient is then taken to the operating room for the procedure. The Leksell frame was manually fixe to the patient's head according to the previous coordinates, and the entering point was choosing followed by the adjustment of the dept of the stereotactic needle biopsy. Once the needle got into the lesion, they were a reflux of pus-like material that pup into the siring attached to the other end of the system. Seventy milliliters of a light brown collection were evacuated (Fig1 D - E/). The post - operative CT-Scan shows a complete evacuation of the parafalc-

ine empyema (Fig1 B/). The frontal subdural empyema was evacuated much later through a burr hole, when the patient's signs and symptoms have subsided. The material was sent to the laboratory for analysis and the bacteriological examination and culture isolated a staphylococcus aureus which is resistant to penicillin G only. In the post operative period, the patient was treated with a third generation of cephalosporin (Rocephine[®]) 3g/24H infusion with good outcome. The antibiotic therapy was given for 3 months (five weeks in-hospital infusion followed by height weeks oral amoxicillin + clavulanic acid) with a short-time follow-up imaging and infection parameters in blood. There was no recurrence and the patient resumed his daily duty a month later.



Stereotactic Management of a Parafalcine Subdural Empyema: Case Report and Review of the Literature

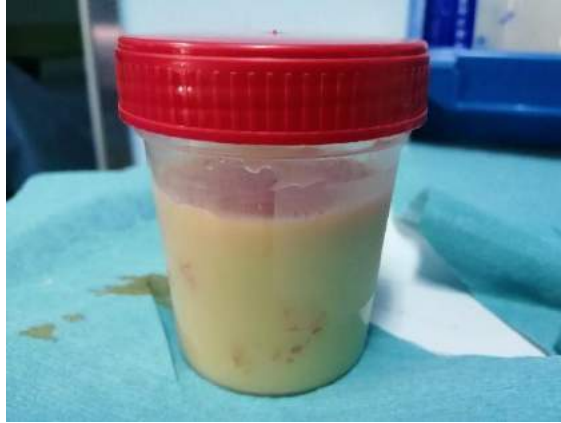

Figure 1: A/ Enhanced computed tomography showing left longitudinal hypodensity area, the parafalcine collection with enhancing rim about 10 mm thickness (white arrow). B/ Complete evacuation of the pus. C/ Stereotactic navigation planning. D/ Stereotactic aspiration of the parafalcine empyema with a very gentle draw-back effort on the syringe. E/ About 70 ml of pus was withdrawn and send to the laboratory.

Table 1: Epidemiological, clinical and management profile of parafalcine subdural empyema in the literature

1st author/ year	Age/ Sexe	Entry route	Clinical presentation	Laboratory finding	Micro- organisms	Treatment	Outcome
Calik et al./2012 [5]	13/M	History of sinusitis	Headache, multiple cervical micro lymphadenopathy	WBC = 15 X 10 ³ /μL, CRP = 76 mg/L	Not identified	Left frontal sinusotomy, Craniotomy and drainage of the empyema/Ceftriaxone, metronidazole	Improved
Bouziri et al./2011 [6]	7/F	History of poor oral hygiene	Fever, vomiting, lethargic with cool, neck stiffness.	Not found	Streptococcus constellatus, Actinomyces Viscosus	Vancomycin, Metronidazole, ampicillin	Died
Shen et al./2018 [3]	13/F	History of sinusitis	Fever, headache and drowsiness	WBC = 12.5 X 10 ³ /μL, CRP = 98.47 mg/L	Not identified	Broad-spectrum antibiotics.Refused surgery	Coma
Arifianto et al./2018 [7]	17/M	History of allergic rhinitis	Decrease in consciousness, difficulties in speech, and paresis of the left side of his body	WBC = 23.5 X 10 ³ /μL, CRP = 286 mg/L	Staphylococcus epidermidis	Craniotomy/ ceftriaxone 2 g b.i.d., metronidazole 500 mg t.i.d., and gentamycin 160 mg q.d.	Improved
Nicoli et al./2016 [8]	12/F	History of sinusitis	Headache, fever, vomiting	CRP = 195 mg/L	Microaerophilic Streptococcus	Craniotomy/ Ceftriaxone, Metronidazole	Improved
Patel et al./2016 [9]	10/F	History of sinusitis	Fever, headache, vomiting, and seizure	ESR = 95 mm/h, CRP = 1,2 mg/dL	Group A β-hemolytic Streptococcus	Craniotomy + bilateral maxillary antrostomy + total ethmoidectomy + sphenoidotomy/ Vancomycin, linezolid, metronidazole	Improved

Bruneret al./2012[10]	16/M	History of sinusitis	Fever, headache, seizure,	WBC = 17,300 cells/mm	Not identified	Ceftriaxone, Vancomycin	Improved
Mueller et Myseros/2017 [11]	10/M	None	Headache	WBC = 12.89 X 10 ³ /μL, CRP = 0.11 mg/dL	No specific pathogens	Craniotomy/ vancomycin, metronidazole, and ceftriaxone	Improved
Handa et al./1975[12]	14/F	History of sinusitis	Headache, nausea and anorexia	WBC count of 9.8 X 10 ³ /μL	No specific pathogens	Craniotomy/ Broad-spectrum antibiotics	Improved
Mauser et al./1985[13]	21/M	History of sinusitis	Fever and headache	WBC count of 16.0 X 10 ³ /μL, ESR = 63 mm/h	No specific pathogens	ampicillin, 2 gm/4 hrs; chloramphenicol, 1 gm/6 hrs; and flucloxacillin, 2 gm/4 hrs	Improved
Niklewski et al./2013[14]	12/M	Headache and sinusitis	Right sided hemiparesis	Not found	Not identified	Craniotomy/ antibiotics	Improved
Niklewski et al./2013[14]	8/F	History of sinusitis	Fever, headache, and seizures	Not found	Streptococcus intermedius	Craniotomy/ antibiotics and levetiracetam	Improved
Sammartino et al./2016[15]	13/M	None	Fever and headache	WBC = 24.770 X 10 ³ /μL, CRP = 33.4 mg/dL	Streptococcus intermedius	Craniotomy + flexible endoscope (KARL STORZ, Tuttlingen, Germany/ meropenem and ampicillin	Improved
Pandey et al./2015 [16]	8/F	History of purulent otitis media	Fever, headache, and seizures	WBC = 27.100 X 10 ³ /μL, CRP = 26 mm/h	Staphylococcus aureus	Craniotomy/ ampicillin-cloxacillin, gentamycin, and metronidazole	Improved
Yüksel et al./2016[4]	17/F	None	Left sided hemiplegia	WBC = 16 X 10 ³ /μL, CRP = 7.8 mg/L	No identified	Craniectomy/ Ceftriaxone (100 mg/kg/day), metronidazole (7.5 mg/kg every 6 hours), and vancomycin (15 mg/kg every 6 hours) were given empirically for 3 weeks	Improved
Prieto et Ortega/2019[2]	21/F	History of endoscopic sinonasal surgery	Fever, headache, seizures, and left-side hemiparesis	WBC = 13.510 X 10 ³ /μL, CRP = 194.80 mg/L	Prevotella oris	Craniotomy/ cefepime, metronidazole, and vancomycin	Improved
Van der Stel et al./2015 [1]	28/M	None	Fever, headache		Streptococcus milleri	Craniotomy/ Benzylpenicillin 12 million entities per 24 hours for 10 weeks intravenously and another 4 weeks orally (amoxicillin)	Improved

WBC = white blood cell count, CRP = C-Reactive Protein

III. DISCUSSION

The 17 cases of parafalcine subdural empyema we review from the literature are all pretty young patient with age range from 7 to 28 years old. Ten had a history of sinusitis. The clinical presentation was nonspecific and made of fever and headache in 6 cases and seizure was found in 5 of them (Table 1). These finding are exactly the past medical history and the clinical presentation of the case we reported. In that same review, most authors do not reveal how they treated the seizures but a broad-spectrum antibiotics have been used to treat the patient once the diagnosis is suspected. This may explain the reason why in 8 cases out of the 17, the antibacterial culture of the pus was sterile. From the 9 other cases from which a pathogen was isolated, six was *Streptococcus* species. Meaning our case is also rare in this aspect of being caused by staphylococcus species, found in only two patients. In most of the cases, the antibacterial therapy was adjusted to the antibiogram result according to the sensitivity of the isolated pathogen. The question about how long do the treatment last to get the patient read of the infection, did not found answers. The duration of antibiotic therapy is very diverse and varied from 6 to 12 weeks.

Most patient recovered after craniotomy (13/17) with evacuation of the pus (Table 1). Nonetheless, the tendency of pus to extend along the length of the falx below the longitudinal sinus and bridging veins makes parafalcine, or interhemispheric, subdural empyema relatively difficult-to-reach collections. The parafalcine empyema surgery is a great challenge and the controversy remains over their treatment strategy (17). We went for the stereotactic-guided drainage of the pus. Our pre-operative planning led to a spectacular result both clinically and imaging with the almost complete evacuation of pus. The patient then underwent a craniotomy with evacuation of the frontoparietal subdural empyema. The patient presented an immediate good outcome and the management continued with the antibiotics adapted to the findings of the bacteriologic analysis. According to surgical strategy, several techniques are available. Prieto et al. (2) reported a case of large parasagittal craniotomy with a good outcome, and Sammartino et al. (15) proposed a burr hole followed

by an endoscopic aspiration. Even if the craniotomy is the surgical strategy more often used to treat parafalcine empyema, we propose according to our experience to consider the option of stereotactic-guided drainage. It is also important, regarding the critical analysis of Salunke et al. (18) and Mauser et al. (13) to consider that a nonsurgical strategy might be considered for patients with a good clinical condition and no major midline shift on neuroradiological studies.

IV. CONCLUSION

Stereotactic management of a parafalcine subdural empyema is doable independently of the neurological status of the patient and it is a precise and focused-to-lesion surgical procedure with a good evacuation of the pus; speeding patient recovery.

Ethics and reporting guidelines

This article respects both the Consensus-based Clinical Case Reporting Guideline and the Recommendations for the Conducting, Reporting, Editing, and Publication of Scholarly Work in Medical Journals.

Disclosure

The authors did not receive any funding for the preparation of this case report.

This article is an original work that is not being considered or reviewed by any other publication, and has not been published elsewhere in the same or a similar form.

All authors of the manuscript have read and agreed to its content and are accountable for all aspects of the accuracy and integrity of the manuscript;

Informed Consent: The patient gave his informed consent to publish his case.

Conflicts of Interest: The authors declare that they have no conflicts of interest.

REFERENCES

1. van der Stel T, Treuniet FEE, Hoffmann C, Koppen H. Parafalcine empyema, a tricky infectious cause of headache: a case report. *The American Journal of Emergency Medicine* [Internet]. 2015 Jul [cited 2021 Aug 16];33

- (7):992.e1-992.e2. Available from: <https://linkinghub.elsevier.com/retrieve/pii/S0735675714009917>.
2. Prieto R, Ortega C. Parafalcine subdural empyema: The unresolved controversy over the need for surgical treatment. *Surgical Neurology International* [Internet]. 2019 Oct 18 [cited 2021 Aug 16];10:203. Available from: <http://surgicalneurologyint.com/surgicalint-article/s/parafalcine-subdural-empyema-the-unresolved-controversy-over-the-need-for-surgical-treatment/>.
 3. Shen Y-Y, Cheng Z-J, Chai J-Y, Dai T-M, Luo Y, Guan Y-Q, et al. Interhemispheric Subdural Empyema Secondary to Sinusitis in an Adolescent Girl. *Chinese Medical Journal* [Internet]. 2018 Dec 20 [cited 2021 Aug 16];131 (24):2989–90. Available from: <https://journals.lww.com/00029330-201812200-00014>
 4. Yüksel M, Gürbüz M, Karaarslan N, Caliskan T. Rapidly progressing interhemispheric subdural empyema showing a three-fold increase in size within 12 hours: Case report. *Surg Neurol Int* [Internet]. 2016 [cited 2021 Aug 16];7(38):872. Available from: http://surgicalneurologyint.com/surgicalint_articles/rapidly-progressing-interhemispheric-subdural-empyema-showing-a-three-fold-increase-in-size-within-12-hours-case-report/.
 5. Calik M, Iscan A, Abuhandan M, Yetkin I, Bozkuş F, Torun MF. Masked subdural empyema secondary to frontal sinusitis. *Am J Emerg Med*. 2012 Oct;30(8):1657.e1-4.
 6. Bouziri A, Khaldi A, Smaoui H, Menif K, Jaballah NB. Fatal subdural empyema caused by *Streptococcus constellatus* and *Actinomyces viscosus* in a child—case report. *Journal of Microbiology, Immunology and Infection*. 2011;44(5):394–6.
 7. Arifianto MR, Ma'rif AZ, Ibrahim A, Bajamal AH. Interhemispheric and Infratentorial Subdural Empyema with Preseptal Cellulitis as Complications of Sinusitis: A Case Report. *Pediatr Neurosurg* [Internet]. 2018 [cited 2021 Aug 16];53(2):128–33. Available from: <https://www.karger.com/Article/FullText/481512>.
 8. Nicoli TK, Oinas M, Niemelä M, Mäkitie AA, Atula T. Intracranial Suppurative Complications of Sinusitis. *Scand J Surg*. 2016 Dec;105(4):254–62.
 9. Patel NA, Garber D, Hu S, Kamat A. Systematic review and case report: Intracranial complications of pediatric sinusitis. *Int J Pediatr Otorhinolaryngol*. 2016 Jul;86:200–12.
 10. Bruner DI, Littlejohn L, Pritchard A. Subdural empyema presenting with seizure, confusion, and focal weakness. *Western Journal of Emergency Medicine*. 2012;13(6):509.
 11. Mueller K, Myseros J. Pediatric Intrafalcine Empyema from a Sinogenic Origin: A Case Report. *Cureus* [Internet]. 2017 May 4 [cited 2021 Aug 16]; Available from: <http://www.cureus.com/articles/7032-pediatric-intrafalcine-empyema-from-a-sinogenic-origin-a-case-report>
 12. Handa J, Hanakita J, Koyama T, Handa H. Interhemispheric subdural empyema with an enlarged tentorial artery and vein. *Neuroradiology* [Internet]. 1975 [cited 2021 Aug 16];9(3):167–70. Available from: <http://link.springer.com/10.1007/BF00332966>.
 13. Mauser HW, Ravijst RAP, Elderson A, van Gijn J, Tulleken CAF. Nonsurgical treatment of subdural empyema: Case report. *Journal of Neurosurgery* [Internet]. 1985 Jul [cited 2021 Aug 16];63(1):128–30. Available from: <https://thejns.org/view/journals/j-neurosurg/63/1/article-p128.xml>.
 14. Niklewski F, Petridis AK, Al Hourani J, Blaeser K, Ntoulis G, Bitter A, et al. Pediatric parafalcine empyemas. *Journal of Surgical Case Reports* [Internet]. 2013 Aug 29 [cited 2021 Aug 16];2013(8):rjto67–rjto67. Available from: <https://academic.oup.com/jscr/article-lookup/doi/10.1093/jscr/rjto67>
 15. Sammartino F, Feletti A, Fiorindi A, Mazzucco GM, Longatti P. Aspiration of parafalcine empyemas with flexible scope. *Childs Nerv Syst* [Internet]. 2016 Jun [cited 2021 Aug 16];32(6):1123–9. Available from: <http://link.springer.com/10.1007/s00381-016-3082-6>
 16. Pandey S, Sharma V, Singh K, Sahu A, Pandey D. Gas-Forming Intracerebral Abscess with Pediatric Parafalcine Subdural Empyema with Review of Literature. *IJNS* [Internet]. 2015 Nov 24 [cited 2021 Aug 16];04 (03):164–72.

Available from:<http://www.thiemeconnect.de/DOI/DOI?10.1055/s-0035-1559804>.

17. Akhaddar A. Atlas of infections in neurosurgery and spinal surgery. Springer; 2017.
18. Salunke PS, Malik V, Kovai P, Mukherjee KK. Falcotentorial subdural empyema: analysis of 10 cases. *Acta Neurochir* [Internet]. 2011 Jan [cited 2021 Aug 16];153(1):164–70. Available from: <http://link.springer.com/10.1007/s00701-010-0695-5>