

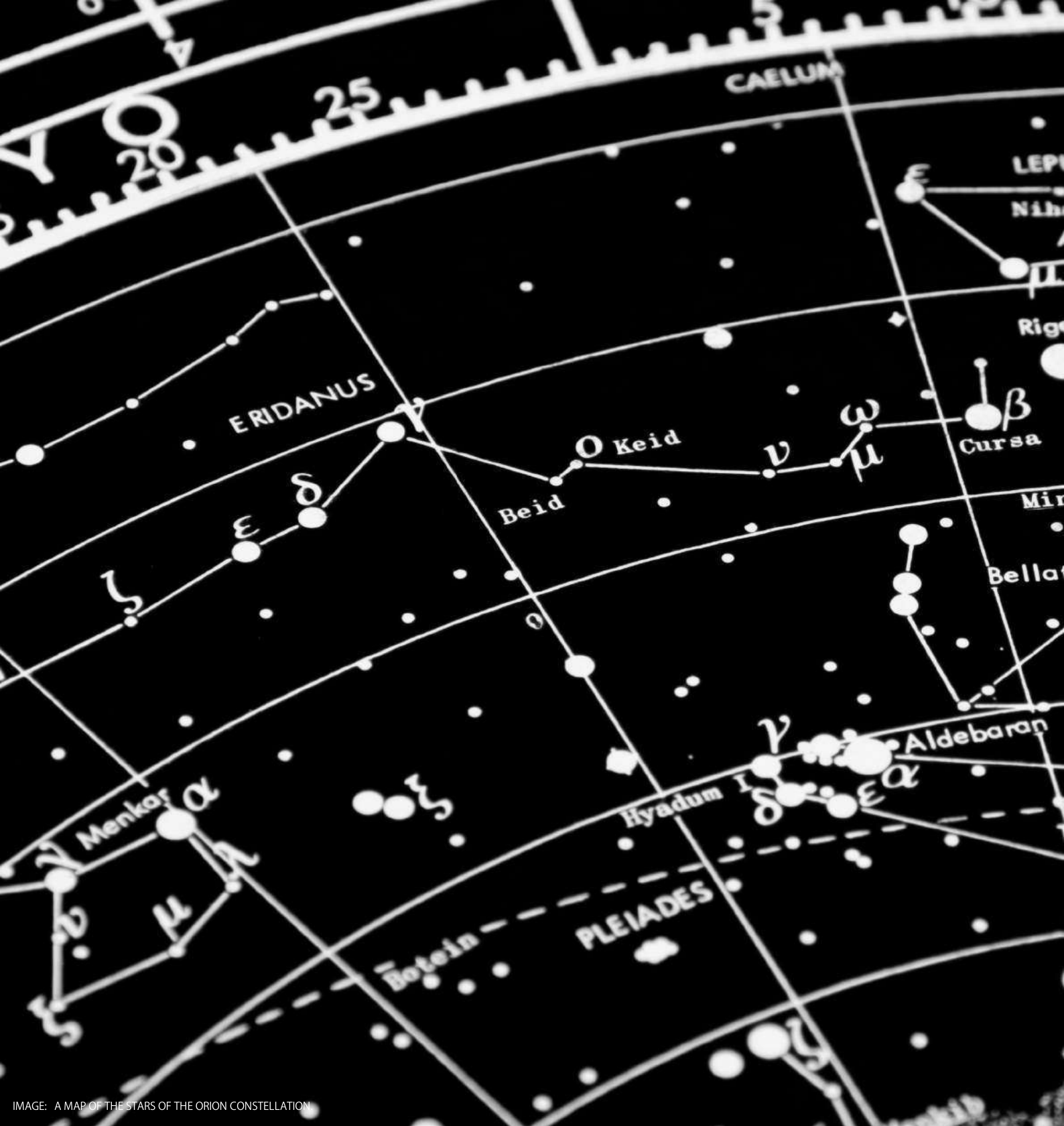

IMAGE: A MAP OF THE STARS OF THE ORION CONSTELLATION

# JournalPreview

London Journal of Medical & Health Research

Volume 24 | Issue 4 | Compilation 1.0



Great Britain  
Journals Press

# JournalPreview

London Journal of Medical & Health Research

This document is a pre-published view of London Journal of Medical & Health Research Volume 24, Issue 4 and Compilation 1.0. For any minor changes and updations kindly follow your paper's live editing URL given in given in sent email or get in touch with our support team at [support@journalspress.com](mailto:support@journalspress.com) or visit our website to use live chat support. This is a beta document thus order, content or existence of papers may alter in the published eJournal. You are requested to kindly acknowledge and approve your research paper in this JournalPreview within three days.

# Journal Content

In this Issue



- i. Journal introduction and copyrights
  - ii. Featured blogs and online content
  - iii. Journal content
  - iv. Editorial Board Members
- 

1. Zolpidem in Insomnia Management: Considerations and Side Effects Associated with Long-Term Indiscriminate use. **1-2**
  2. Nutritional Assessment of Advanced Cancer Patients Admitted to Home Palliative Care. **3-9**
  3. Hereditary Multiple Exostosis with Malignant Transformation: Case Report. **11-14**
  4. Recalcitrant Humeral Nonunion: Biological Reconstruction Technique. **15-22**
  5. Management of Coalescence of the Little Lips in Girls at the Pediatric Surgery Department of the Donka National Hospital (HND) of the Conakry Chu. **23-28**
- 

- V. Great Britain Journals Press Membership



Scan to know paper details and  
author's profile

# Zolpidem in Insomnia Management: Considerations and Side Effects Associated with Long-Term Indiscriminate use

*Amanda Moliterno*

## ABSTRACT

*Introduction:* Insomnia, characterized by difficulty initiating or maintaining sleep, is a common condition that significantly impacts individuals' quality of life and well-being. In the context of pharmacological treatment, zolpidem has emerged as a widely prescribed option for the effective management of sleep disorders. However, while this medication provides immediate relief for insomnia symptoms, growing concerns have been raised regarding its indiscriminate long-term use and potential side effects.

*Objectives:* This article aims to comprehensively explore the effectiveness of zolpidem in treating insomnia, while highlighting critical considerations and adverse effects associated with its prolonged use. By investigating the relationship between insomnia management with zolpidem and the implications of indiscriminate administration, this study seeks to provide a balanced perspective, fostering a deeper understanding of the risks and benefits involved in the long-term use of this medication.

*Keywords:* zolpidem, insomnia, and side effects.

*Classification:* NLM Code: QV 77

*Language:* English



Great Britain  
Journals Press

LJP Copyright ID: 392881

London Journal of Medical and Health Research

Volume 24 | Issue 4 | Compilation 1.0



© 2024, Amanda Moliterno. This is a research/review paper, distributed under the terms of the Creative Commons Attribution-Non-commercial 4.0 Unported License (<http://creativecommons.org/licenses/by-nc/4.0/>), permitting all noncommercial use, distribution, and reproduction in any medium, provided the original work is properly cited.

# Zolpidem in Insomnia Management: Considerations and Side Effects Associated with Long-Term Indiscriminate use

Amanda Moliterno

## ABSTRACT

*Introduction: Insomnia, characterized by difficulty initiating or maintaining sleep, is a common condition that significantly impacts individuals' quality of life and well-being. In the context of pharmacological treatment, zolpidem has emerged as a widely prescribed option for the effective management of sleep disorders.*

*However, while this medication provides immediate relief for insomnia symptoms, growing concerns have been raised regarding its indiscriminate long-term use and potential side effects.*

*Objectives: This article aims to comprehensively explore the effectiveness of zolpidem in treating insomnia, while highlighting critical considerations and adverse effects associated with its prolonged use. By investigating the relationship between insomnia management with zolpidem and the implications of indiscriminate administration, this study seeks to provide a balanced perspective, fostering a deeper understanding of the risks and benefits involved in the long-term use of this medication.*

*Methods: The methodology involved a literature review of articles published on the "Scielo" and "Pubmed" websites from October 2013 to October 2023. The cited publications are presented in Portuguese and English.*

*Keywords: zolpidem, insomnia, and side effects.*

## I. RESULTS

Zolpidem, belonging to the class of imidazopyridines, has emerged as an effective pharmacological option for the symptomatic treatment of insomnia. Its action occurs through

interaction with GABAergic receptors in the central nervous system, inducing a state of sedation that facilitates the initiation and maintenance of sleep. However, as its prescription has become more widespread, especially for cases of chronic insomnia, concerns regarding indiscriminate long-term use have been raised.

One central point in this discussion lies in the potential side effects associated with zolpidem when administered for prolonged periods. Studies have pointed to the possible occurrence of tolerance, dependence, and withdrawal syndrome, suggesting the need for caution in prolonged prescription. Psychological dependence may manifest with the development of compulsive behaviors to obtain the drug, while tolerance may require increasing doses to maintain the initial efficacy. Moreover, long-term use of zolpidem may be correlated with cognitive and psychomotor adverse effects, with reports of memory impairment, confusion, and falls in elderly patients. These implications underscore the importance of a thorough evaluation of benefits and risks before prescribing long-term zolpidem, particularly in more vulnerable populations.

Ethical considerations also emerge in the discussion of prolonged zolpidem use, especially when patients are not adequately informed about the potential associated risks. Patient autonomy must be respected, and shared decision-making between doctor and patient is crucial to ensuring a transparent and ethical approach. In light of these considerations, it is imperative to explore alternative strategies in insomnia management, including behavioral interventions, cognitive-behavioral therapies, and lifestyle modifications.

These approaches, when combined, can not only provide lasting benefits but also mitigate the potential risks associated with the long-term use of hypnotic medications.

## II. CONCLUSION

In conclusion, while zolpidem plays a crucial role in the immediate treatment of insomnia, it is essential to critically address the inherent challenges of its indiscriminate long-term use. The quest for a balance between clinical efficacy and long-term safety should guide clinical practices, promoting a holistic approach to caring for patients with sleep disorders. Interdisciplinary collaboration among physicians, psychologists, and other healthcare professionals is essential to ensure comprehensive and personalized management of insomnia, always respecting ethical principles and the quality of life of patients.

## REFERENCES

- Oliveira Azevedo, B., Fernandes dos Santos, E., Silva Lima, G., Tavares Pujol, J., Alexandrino Antunes, A., & Oliveira Passos Jesus, L. (2022). Perfil farmaco- terapêutico do Zolpidem. *Revista Brasileira De Ciências Biomédicas*, 3(1), E0642022 – 1. <https://doi.org/10.46675/rbcm.v3i1.64>.
- Foda NH, Ali SM. Zolpidem tartrate. *Profiles Drug Subst Excip Relat Methodol*. 2012; 37: 413-38. doi: 10.1016/B978-0-12-397220-0.00011-8. Epub 20 12 Mar 19. PMID: 22469325.
- Zhang J, Yetton B, Whitehurst LN, Naji M, Mednick SC. The effect of zolpidem on memory consolidation over a night of sleep. *Sleep*. 2020 Nov 12; 43(11): zsaa084. doi: 10.1093/sleep/zsaa084. PMID: 32330272; PMCID: PMC8064806.
- Hoehns JD, Perry PJ. Zolpidem: a non-benzodiazepine hypnotic for treatment of insomnia. *Clin Pharm*. 1993 Nov; 12(11): 814-28. Erratum in: *Clin Pharm* 1993 Dec; 12(12):881. PMID: 8275648.
- Castro, L. S., Otuyama, L. J., Fumo- dos-Santos, C., Tufik, S., & Poyares, D.. (2020). Sublingual and oral zolpidem for insomnia disorder: a 3-month randomized trial. *Brazilian Journal of Psychiatry*, 42(2), 175–184. <https://doi.org/10.1590/1516-4446-2019-0389>.
- Sukys-Claudino, L., Moraes, W. A. dos S., Tufik, S., & Poyares, D.. (2010). Novos sedativos hipnóticos. *Brazilian Journal of Psychiatry*, 32(3), 288–293. <https://doi.org/10.1590/S1516-44462010000300014>.



Scan to know paper details and  
author's profile

# Nutritional Assessment of Advanced Cancer Patients Admitted to Home Palliative Care

*Sebastiano Mercadante, Giuseppe Massimo Bellavia, Flavio Fusco, Lucia Adamoli, Carla Scibilia, Alessio Lo Cascio & Alessandra Casuccio*

*University of Palermo*

## ABSTRACT

**Objectives:** The aim of this study was to investigate the nutrition profile of advanced cancer patients who were admitted to specialized home palliative care.

**Methods:** A consecutive sample of home care patients at admission of home care was assessed. Depression, anxiety, nausea, poor appetite, and poor well-being were measured by numerical scale 0-10. Mini nutritional assessment form (MNA-SF), fatigue assessment scale (FAS), and sarcopenia by SARC-F. were performed. The use of drugs used for anorexia, including corticosteroids, progestins, or others, was recorded.

**Results:** Data of 135 patients were analyzed. Sixty-eight percent and 77% of patients resulted to be malnourished and sarcopenic. In the multivariate regression analysis, anxiety ( $p=0.036$ ) and total FAS ( $p=0.013$ ) were independently associated with malnutrition. Fifty-five percent of patients were receiving corticosteroids or megestol acetate. No significant associations with parameters examined were found.

**Keywords:** malnutrition, sarcopenia, advanced cancer, palliative care, home care.

**Classification:** NLM Code: WB 310

**Language:** English



Great Britain  
Journals Press

LJP Copyright ID: 392882

London Journal of Medical and Health Research

Volume 24 | Issue 4 | Compilation 1.0



© 2024, Sebastiano Mercadante, Giuseppe Massimo Bellavia, Flavio Fusco, Lucia Adamoli, Carla Scibilia, Alessio Lo Cascio & Alessandra Casuccio. This is a research/review paper, distributed under the terms of the Creative Commons Attribution-Noncommercial 4.0 Unported License <http://creativecommons.org/licenses/by-nc/4.0/>, permitting all noncommercial use, distribution, and reproduction in any medium, provided the original work is properly cited.

# Nutritional Assessment of Advanced Cancer Patients Admitted to Home Palliative Care

Sebastiano Mercadante<sup>α</sup>, Giuseppe Massimo Bellavia<sup>σ</sup>, Flavio Fusco<sup>ρ</sup>, Lucia Adamoli<sup>ω</sup>,  
Carla Scibilia<sup>✧</sup>, Alessio Lo Cascio<sup>§</sup> & Alessandra Casuccio<sup>x</sup>

## ABSTRACT

**Objectives:** *The aim of this study was to investigate the nutrition profile of advanced cancer patients who were admitted to specialized home palliative care.*

**Methods:** *A consecutive sample of home care patients at admission of home care was assessed. Depression, anxiety, nausea, poor appetite, and poor well-being were measured by numerical scale 0-10. Mini nutritional assessment form (MNA-SF), fatigue assessment scale (FAS), and sarcopenia by SARC-F. were performed. The use of drugs used for anorexia, including corticosteroids, progestins, or others, was recorded.*

**Results:** *Data of 135 patients were analyzed. Sixty-eight per cent and 77% of patients resulted to be malnourished and sarcopenic. In the multivariate regression analysis, anxiety ( $p=0.036$ ) and total FAS ( $p=0.013$ ) were independently associated with malnutrition. Fifty-five percent of patients were receiving corticosteroids or megestol acetate. No significant associations with parameters examined were found.*

**Conclusion:** *The majority of advanced cancer patients admitted to home palliative care were malnourished independently of the primary tumor diagnosis. Indeed, fatigue and anxiety were independently associated with malnutrition.*

**Keywords:** malnutrition, sarcopenia, advanced cancer, palliative care, home care.

### Key Messages

1. Information regarding the nutritional pattern in advanced cancer patients admitted to specialized home care is lacking.
2. This study reported that a large number of patients admitted to specialized home palliative care are malnourished and sarcopenic.
3. This study suggests systematically assess the nutritional status and evaluate the need for an intervention according to expected survival.

**Author** <sup>α</sup> <sup>σ</sup> <sup>ω</sup> <sup>✧</sup>: Regional home palliative care program, SAMOT, Palermo, Italy.

<sup>ρ</sup>: Palliative care unit, ASL3 Liguria, Genua, Italy.

<sup>α</sup> <sup>§</sup> <sup>x</sup>: Main Regional center for supportive and palliative care, La Maddalena Cancer center, Palermo, Italy @ University of Palermo.

## I. INTRODUCTION

About 18 million new cancer patients and 9.6 million cancer-related deaths occurred in 2018 worldwide. Many of these patients are living longer with metastatic disease due to advances in diagnostics and treatments [1]. Patients with severe, progressive, and incurable diseases, such as advanced cancer, should receive palliative care to improve quality of life through prevention and relief of suffering, pain, and other physical, psychosocial, and spiritual manifestations [2].

Palliative care in incurable cancer should be focused on symptom control, especially those impacting nutrition, and initiated simultaneously with active care at diagnosis since patients identify malnutrition as the primary cause of physical, cognitive, and social function loss [3]. It has been suggested that advanced cancer patients receiving palliative care should be assessed for nutritional deficiencies. Regardless of whether they are still on anticancer treatments or not, in these patients malnutrition leads to low performance status, impaired quality of life, unplanned hospitalizations, and reduced survival [4].

The role of nutritional support for cancer patients in palliative care is still a controversial issue [5].

In a recent review, the prevalence of weight loss and associated symptoms was quite heterogeneous. There was a large range of variability influenced by age and social factors, comorbidities, and setting of care. The advanced stage was found to be linked to a higher risk of developing malnutrition, as an expression of the relationship between tumor burden, inflammatory status, reduced caloric intake, and malabsorption [6].

Information regarding the nutritional status of advanced cancer patients admitted to home palliative care is lacking. Given the relevance of assessing nutritional and functional aspects of palliative care and the lack of studies addressing the topic, this study aimed to investigate the nutrition profile of advanced cancer patients who were admitted to specialized home palliative care.

## II. METHODS

This was a cross-sectional study of patients who were admitted to two specialized home palliative care programs in Italy, in Palermo and Genua. A group of home care physicians adhered to the protocol and were trained to use of the tools selected for this study, with the help of a dietician. A consecutive sample of advanced cancer patients at admission of home care was assessed for a period of six months. Inclusion criteria were: age >18 years and advanced cancer disease. Exclusion criteria were: refusal of informed consent, expected survival less than one week, cognitive failure or incapacity to help assessment, and language barriers.

Epidemiological data was recorded, including age, gender, primary diagnosis, and Karnofsky level. Items of Edmonton Symptom Assessment Scale including depression, anxiety, nausea, poor appetite, and poor well-being were measured.

The following parameters were assessed: mini nutritional assessment form (MNA-SF), fatigue assessment scale (FAS), and the SARC-F. The MNA-SF is a screening tool to help identify patients who are malnourished or at risk of

malnutrition. It consists of six items: decline in food intake, weight loss, mobility, psychological stress or acute disease, neuropsychological problems, and the BMI. The scale is scored out of a total of 14 points and values below a threshold of 12 were used to identify at risk patients. The range 8-11 points corresponds to risk of malnutrition, and patients with 0-7 points are malnourished [7]. FAS is a validated tool, which has psychometric properties. Each item is scored on a 5-point scale from 1 (never) to 5 (always); total scores range from 10 to 50 [8]. We examined the presence/absence of clinically significant fatigue by dichotomizing the scale at the validated threshold: no fatigue (scores of 10-21) versus fatigue (scores of 22-50) [9]. SARC-F is a clinical index for sarcopenia screening. It includes five components: aid for walking, falls, getting up from a chair, climbing stairs, and strength. The scores for each item range from zero to two, obtaining a total score between zero to 10 points.

A score greater than or equal to four is defined as risk of sarcopenia [10]. Drugs used for anorexia, including corticosteroids, progestins, or others, were recorded, and when available, laboratory data. Patient's informed consent and local ethical committee approval were obtained.

### 2.1 Statistical Analysis

Absolute and relative frequencies have been reported for qualitative variables, and means and standard deviation (SD) for quantitative variables. Frequency analysis was performed using the Pearson's chi-square test and Fisher exact test, as needed. An univariate and multivariable regression model was used to examine the correlations between malnutrition patient status (dependent variables), and clinical patient characteristics (independent variables). Odds ratios and related 95% confidence intervals (95% CI) were reported as well as the p-value. Data were analyzed by IBM SPSS Software 24 version (IBM Corp., Armonk, NY, USA). All p-values were two-sided and  $p \leq 0.05$  was considered statistically significant.

### III. RESULTS

Three-hundred-forty-three patients were consecutively assessed. Two-hundred-eight patients were not considered, according to the exclusion criteria: language barriers (n.8), no informed consent (n.13), poor prognosis-not collaborating (n.187).

Data of 135 patients were assessed. The principal characteristics of patients and parameters recorded are reported in Table 1.

Nine-two patients were malnourished and 35 were at risk of malnutrition (MNA-SF  $\leq 7$  and  $< 12$ , respectively). One-hundred-four patients (77%) had sarcopenia (SARC-F $\geq 4$ ).

At univariate analysis, age (P=0.015), Karnofsky (P =0.001), depression (P= 0.005), anxiety (P=0.008), poor appetite (P=0.031), poor well-being (P=0.006), total FAS (P=0.001), total SARC-F (P<0.0005), monocytes, (P=0.049) eosinophils (P=0.047), and d-dimer (P=0.045) were significantly associated with malnutrition. In the multivariate regression analysis, anxiety (OR 2.849, 95% CI 1.070-7.591; p=0.036) and total FAS (OR: 1.693 (95%CI 1.116-2.566; p=0.013) were independently associated with malnutrition. Seventy-five patients were receiving corticosteroids or megestol acetate. No significant associations with parameters examined were found.

*Table 1:* Principal characteristics and data of patients admitted to home care

Age (mean, SD)	75.6 (10.6)
Gender (m/f)	75/60
Karnofsky (mean, SD)	40.5 (10.2)
Primary tumor (n°)	135
Gastrointestinal	53
Lung	40
Urogenital	14
Hematologic	13
Breast	6
Head and neck	6
Other	3
Depression	4.3 (2.7)
Anxiety	4.3 (2.9)
Nausea	1.8 (2.6)
Poor appetite	4.7 (2.6)
Poor well-being	5.5 (2.4)
MNA-SF (mean, SD)	6.4 (3.0)
FAS (mean, SD)	29.7 (7.6)
SARC-F (mean, SD)	5.8 (2.6)

### IV. DISCUSSION

This study reported the data regarding the nutritional status of advanced cancer patients admitted to home care. About 68% of patients were malnourished, and 77% were sarcopenic. There was an independent correlation between malnutrition and fatigue measured with FAS. Of interest, a psychological symptom of ESAS,

namely anxiety, was independently associated with malnutrition. While psychological symptoms invariably belong to the cluster of poor appetite, nausea, weakness, or poor-well-being [11-15], nutritional status has not been taken into consideration.

No differences among primary tumors was found. Pancreatic, esophageal, gastroenteric cancers,

head and neck and lung cancer have been reported to be more likely associated with malnutrition [6]. This finding could be attributed to the very advanced stage of disease, flattening any difference among tumors, or may be the low number of patients in each tumor category.

Many patients were receiving drugs that are commonly used for a variety of symptoms other than improving appetite. The use of corticosteroids for the cluster of symptoms including, fatigue, lack of appetite, anorexia-cachexia, and well-being, remains controversial, as their efficacy may vary depending on the patients' general condition and seems to be reduced in patients with advanced stage of disease or poor performance status [16].

Corticosteroids and progestins have been found to have the potential to offer some benefit [17]. Recently, efficacy of corticosteroids for cancer-related cachexia was less relevant [16]. than that reported in a previous randomized controlled trials [18,19]. Given the cross-sectional design of this study it is difficult to draw information regarding the effect of these drugs in a population with a limited survival at time of admission to home palliative care. On the other hand, it is widely accepted that aggressive feeding interventions are not appropriate at the end of life, and weight loss and reduced food intake are inevitable part of the dying process [20-24]. In a recent opinion expert paper, it has been reported that any form of clinical assisted nutrition is primarily indicated for the prevention of death from malnutrition in selected individuals from specific groups of patients with advanced cancer, for patients with an inability to introduce sufficient nutrients, and/or an inability to digest sufficient nutrients, but not indicated for the management of anorexia, weight loss, cancer cachexia, or reduced oral intake due to nutrition impact symptoms [25].

Data regarding nutritional assessment of advanced cancer patients admitted to home palliative care is poor, and prevalently based on the use of parenteral nutrition [26-28] or performed at home with cancer and non-cancer diseases [29], or in other palliative care settings,

namely inpatient units [30-32]. Malnutrition and poor quality of life are prevalent among advanced cancer patients in home palliative care. In a small study with a cross-sectional design in patients receiving home palliative care, 52.5% of patients were moderately or suspected of being malnourished and 32.8% of them were severely malnourished. Patient-Generated Subjective Global Assessment (PG-SGA) score used in this study showed a lower total quality of life, psychophysiological well-being, functional well-being and social/spiritual well-being [33]. In a cross-sectional multi-center Spanish study performed in different settings including oncology, radiotherapy, and home palliative care, more than 50% of patients had moderate-severe malnutrition, assessed by PG-SGA [34]. It is likely that in home palliative care patients malnutrition rate would be higher, although this distinction among the settings was not reported.

Patients with advanced cancer are commonly more malnourished compared to cancer patients in earlier stages [35]. In this study, where patients with poor immediate prognosis were excluded, survival was, however, relatively short, mostly in the range of 2-3 months, considering the large range of an advanced cancer status, which can be 6-24 months [4].

There are some limitations of this study, such as the large number of excluded patients. This limitation is frequently reported in studies of palliative care patients in the late stage of disease.

Another limitation was the lack of monitoring of nutrient intake in these patients at this stage of disease for finding possible correlations with malnutrition, FAS, and SARC. Finally, the study lacks longitudinal assessment, having a cross-sectional evaluation at time of admission to home palliative care. However, this information may be useful for understanding the frequency of malnutrition in this population.

## V. CONCLUSION

The majority of advanced cancer patients admitted to home palliative care are malnourished independently of the primary

tumor diagnosis. Indeed, fatigue and anxiety were independently associated with malnutrition. Longitudinal studies may help to provide more information about these relationships. More studies should afford the question whether active treatments with orexant drugs or nutritional supplements may have a role in the comprehensive palliative care management to improve quality of life of very advanced cancer patients with a short survival time followed at home.

*No conflict of interest*

*No funding*

*Data available on request*

*Author contribution:*

SM: Conceptualization;

AL: Data curation; Supervision, writing original draft

AC; Formal analysis;

GB: Methodology

FF,GB, LA, CS ; Investigation;

All: Writing - review & editing.

## REFERENCES

1. Bray, F.; Ferlay, J.; Soerjomataram, I.; Siegel, R.L.; Torre, L.A.; Jemal, A. Global cancer statistics 2018: GLOBOCAN estimates of incidence and mortality worldwide for 36 cancers in 185 countries. *CA Cancer J. Clin.* 2018, 68, 394–424.
2. World Health Organization (WHO), National cancer control programmes: policies and managerial guidelines. 2nd ed. Geneva: World Health Organization; 2002. <https://www.who.int/cancer/nccp/en/>.
3. Lis CG, Gupta D, Lammersfeld CA, Markman M, Pankaj GV. Role of nutritional status in predicting quality of life outcomes in cancer e a systematic review of the epidemiological literature. *Nutr J* 2012; 11: 27.
4. Cotogni P, Stragliotto S, Ossola M, Collo A, Riso S. The Role of Nutritional Support for Cancer Patients in Palliative Care. *Cotogni Nutrients* 2021;13: 306.
5. Thomas, K.; Wilson, J. A.; Gold Standards Framework. National Gold Standards Framework Centre in End of Life Care. The Gold Standards Framework Proactive Identification Guidance (PIG). The National GSF Centre's Guidance for Clinicians to Support Earlier Identification of Patients Nearing the End of Life, Leading to Improved Proactive Person-Centred Care. 2016. Available online: [www.goldstandardsframework.org.uk](http://www.goldstandardsframework.org.uk) (accessed on 5 December 2020).
6. Bossi P, Delrio P, Mascheroni A, The Spectrum of Malnutrition/Cachexia/S arcope nia in Oncology According to Different Cancer Types and Settings: A Narrative Review. *Nutrients* 2021;13:1980.
7. Rubenstein LZ, Harker JO, Salva A, Guigoz Y, Vellas B. Screening for undernutrition in geriatric practice: developing the short-form mini-nutritional assessment (MNA-SF). *J Gerontol A Biol Sci Med Sci* 2001; 56: M3 66e72.
8. Michielsen HJ, De Vries J, Van Heck GL. Psychometric qualities of a brief self-rated fatigue measure: the Fatigue Assessment Scale. *J Psychosom Res.* 2003; 54: 345-52.
9. Thong MSY, Mols F, Wang XS, Lemmens VEPP, Smilde TJ, van de Poll-Franse LV. Quantifying fatigue in (long-term) colorectal cancer survivors: a study from the population-based patient reported outcomes following initial treatment and long term evaluation of survivorship registry. *Eur J Cancer.* 2013; 49: 1957-66.
10. Malmstrom TK, Miller DK, Simonsick EM, Ferrucci L, Morley JE SARC-F: a symptom score to predict persons with sarcopenia at risk for poor functional outcomes. *Malmstrom TK, Miller DK, Simonsick EM, Ferrucci L, Morley JE. J Cachexia Sarcopenia Muscle.* 2016; 7: 28-36.
11. Nardi M, Catalini A, Galiano A, Santangelo OE, Pinto E, Feltrin A, Nucci D, Gianfredi V Association between malnutrition and anxiety in cancer patients-aretrospective study. *Support Care Cancer.* 2024; 32: 152.
12. Yennurajalingam S, Tayjasanant S, Balachandran D, Padhye NS, Williams JL, Liu DD, Frisbee- Hume S, Bruera E Association

- between daytime activity, fatigue, sleep, anxiety, depression, and symptom burden in advanced cancer patients: a preliminary report. *J Palliat Med* 2016; 19(8): 849–56.
13. Chabowski M, Polański J, Jankowska-Polańska B, Janczak D, Rosińczuk J. Is nutritional status associated with the level of anxiety, depression and pain in patients with lung cancer? *J Thorac Dis* 2018; 10(4): 2303–10.
  14. Overcash J, Goetz R, Williams N Prediction of Malnutrition and the Relationships Among Pain, Function, Depression, and Cancer Stage in Older Women With Breast Cancer. *Clin J Oncol Nurs*. 2023; 27: 411-7.
  15. Gupta D, Lis CG, Granick J, et al Malnutrition was associated with poor quality of life in colorectal cancer: a retrospective analysis. *J Clin Epidemiol*, 2006; 59, 704-9.
  16. Miura T, Okizaki A, Hasuo H et al. Dexamethasone 8 mg for Cancer-Related Fatigue in Inpatients with Advanced Cancer Undergoing Palliative Care: A Multicenter Phase II Trial. *Palliat Med Rep* 2021; 2: 316-32.
  17. Saeteaw M, Sanguanboonyaphong P, Yoodee J, et al. Efficacy and safety of pharmacological cachexia interventions: systematic review and network meta-analysis. *BMJ Support Palliat Care*. 2021; 11: 75-85.
  18. Yennurajalingam S, Frisbee-Hume S, Palmer JL, et al.: Reduction of cancer related fatigue with dexamethasone: A double-blind, randomized, placebo-controlled trial in patients with advanced cancer. *J Clin Oncol* 2013; 31: 3076–82.
  19. Paulsen Ø, Klepstad P, Rosland JH, et al.: Efficacy of methylprednisolone on pain, fatigue, and appetite loss in patients with advanced cancer using opioids: A randomized, placebo-controlled, double-blind trial. *J Clin Oncol* 2014; 32: 3221–8.
  20. Cline D. Nutrition issues and tools for palliative care. *Home Healthc Nurse*. 2006; 24: 54-7.
  21. Good P, Cavenagh J, Mather M, Ravenscroft P. Medically assisted nutrition for palliative care in adult patients. *Cochrane Database Syst Rev*. 2008; (4): Cdo06274.
  22. Arends J, Baracos V, Bertz H, et al. ESPEN expert group recommendations for action against cancer-related malnutrition. *Clin Nutr* 2017; 36: 1187-96.
  23. Baxter JP, Fayers PM, Bozzetti F, et al. An international study of the quality of life of adult patients treated with home parenteral nutrition. *Clin Nutr*. 2019; 38: 1788-96.
  24. Alley DE, Metter EJ, Griswold ME, et al. Changes in weight at the end of life: characterizing weight loss by time to death in a cohort study of older men. *Am J Epidemiol*. 2010; 172: 558-65.
  25. Alderman B, Allan L, Amano K, et al. Multinational Association of Supportive Care in Cancer (MASCC) expert opinion/guidance on the use of clinically assisted nutrition in patients with advanced cancer. *Support Care Cancer* 2022; 30: 2983-92.
  26. Cotogni P, Monge T, Passera R, Brossa L, De Francesco A. Clinical characteristics and predictive factors of survival of 761 cancer patients on home parenteral nutrition: A prospective, cohort study. *Cancer Med* 2020; 9: 4686-98.
  27. Ruggeri E, Giannantonio M, Ostan R, Agostini F, Sasdelli AS, Valeriani L, Pironi L, Pannuti R Choice of access route for artificial nutrition in cancer patients: 30 y of activity in a home palliative care setting. *Nutrition*. 2021; 90: 111264.
  28. Sowerbutts AM, Lal S, Sremanakova J, et al. Burden S. Palliative home parenteral nutrition in patients with ovarian cancer and malignant bowel obstruction: experiences of women and family caregivers. *BMC Palliat Care*. 2019; 18: 120.
  29. Van der Pols-Vijlbrief R, Wijnhoven HA, Molenaar H, Visser M. Factors associated with (risk of) undernutrition in community-dwelling older adults receiving home care: a cross-sectional study in the Netherlands. *Public Health Nutr*. 2016; 19: 2278-89.
  30. Thoresen L, Fjeldstad I, Krogstad K, Kaasa S, Falkmer UG. Nutritional status of patients with advanced cancer: the value of using the subjective global assessment of nutritional status as a screening tool. *Palliat Med*. 2002; 16: 33-42.

31. Kwang AY, Kandiah M. Objective and subjective nutritional assessment of patients with cancer in palliative care. *Am J Hospice Palliative Med.* 2010; 27: 117-26.
32. Stevens T, Keller H, Williams N, Downar J, Guthrie DM. Cross-Sectional Nutrition Profile of Palliative Home Care Clients in Ontario and Performance of the interRAI Palliative Care Nutrition Clinical Assessment Protocol. *JPEN J Parenter Enteral Nutr* 2021;45:183-192.
33. Shahmoradi N, Kandiah M, Peng LS. Impact of nutritional status on the quality of life of advanced cancer patients in hospice home care *Asian Pac J Cancer Prev* 2009; 10: 1003-09.
34. Segura A, Pardo J, Jara C, Azuara ML, Casado J. An epidemiological evaluation of the prevalence of malnutrition in Spanish patients with locally advanced or metastatic cancer. *Clin Nutr* 2005;24:801-14.
35. Ravasco P, Monteiro-Grillo I, Vidal P, et al. Nutritional deterioration in cancer: the role of disease and diet. *Clin Oncol*, 2003;15, 443-50.

*This page is intentionally left blank*



Scan to know paper details and  
author's profile

# Hereditary Multiple Exostosis with Malignant Transformation: A Case Report

Gustavo Silva Reis

## ABSTRACT

*Introduction:* In this work we will approach a clinical case of hereditary multiple exostosis with malignant transformation. The pathogenesis of HMS is still unknown, and its clinical diagnosis, usually in the first decade of life, is associated with imaging exams. In cases of suspected malignancy, which is rare, the anatomopathological study is also used.

*Discussion:* EHM, an autosomal dominant disease with complete penetration, is the most common skeletal development abnormality. It is usually easy to diagnose due to the age group of those affected, and clinical characteristics, such as short stature and osteoarticular deformities. In the case of atypical forms and rare hypotheses of malignancy, more sophisticated imaging and anatomopathological exams are needed to conclude the diagnosis. Treatment is expectant, or surgical when there is compromised quality of life and tumor malignancy.

*Keywords:* osteochondroma, osteochondromatosis, bone neoplasms.

*Classification:* LCC Code: RD731-RD731.3

*Language:* English



Great Britain  
Journals Press

LJP Copyright ID: 392883

London Journal of Medical and Health Research

Volume 24 | Issue 4 | Compilation 1.0



© 2024. Gustavo Silva Reis. This is a research/review paper, distributed under the terms of the Creative Commons Attribution-Noncommercial 4.0 Unported License (<http://creativecommons.org/licenses/by-nc/4.0/>), permitting all noncommercial use, distribution, and reproduction in any medium, provided the original work is properly cited.

# Hereditary Multiple Exostosis with Malignant Transformation: A Case Report

Exostose Múltipla Hereditária Com Transformação Maligna: Relato De Caso

Gustavo Silva Reis

## RESUMO

*Introdução: Neste trabalho iremos abordar um caso clínico de exóstese múltipla hereditária (EMH) com transformação maligna. A patogênese da EMH ainda é desconhecida, sendo seu diagnóstico clínico, geralmente na primeira década de vida, associado a exames de imagem. Nos casos de suspeita de malignização, que é rara, o estudo anatomopatológico é também utilizado.*

*Apresentação do caso: Paciente de 41 anos, sexo masculino, há 5 meses apresentando protuberância óssea, na região do quadril direito, associada a dor, sinais flogísticos e aumento progressivo e agudo da lesão. O diagnóstico foi realizado através de dados clínicos, anatomopatológicos e de TC, que evidenciou lesão maligna no quadril direito, posteriormente sendo confirmado o quadro de condrossarcoma.*

*Discussão: A EHM, doença autossômica dominante com penetração completa, é a anormalidade do desenvolvimento do esqueleto mais frequente. Geralmente apresenta fácil diagnóstico devido a faixa etária dos acometidos, e das características clínicas, como baixa estatura e deformidades osteoarticulares.*

*Quando das formas atípicas e raras hipóteses de malignização, são necessários exames de imagem mais sofisticados e anatomopatológico para fechar o diagnóstico. O tratamento é expectante, ou cirúrgico quando há comprometimento da qualidade de vida e malignização tumoral.*

*Conclusão: A EMH é uma doença comum dos ossos, e raramente se maligniza. Contudo é de*

*suma importância a detecção desta anormalidade, com base no exame físico e exames de imagem, para estabelecer o tratamento precoce correto, e, assim, prolongar a sobrevida e qualidade de vida dos pacientes acometidos por ela.*

*Palavras-chave:* osteocondroma, osteocondromatose, neoplasias ósseas.

## ABSTRACT

*Introduction: In this work we will approach a clinical case of hereditary multiple exostosis with malignant transformation. The pathogenesis of HMS is still unknown, and its clinical diagnosis, usually in the first decade of life, is associated with imaging exams. In cases of suspected malignancy, which is rare, the anatomopathological study is also used.*

*Discussion: EHM, an autosomal dominant disease with complete penetration, is the most common skeletal development abnormality. It is usually easy to diagnose due to the age group of those affected, and clinical characteristics, such as short stature and osteoarticular deformities.*

*In the case of atypical forms and rare hypotheses of malignancy, more sophisticated imaging and anatomopathological exams are needed to conclude the diagnosis. Treatment is expectant, or surgical when there is compromised quality of life and tumor malignancy.*

*Conclusion: HMS is a common bone disease and rarely becomes malignant. However, it is extremely important to detect this abnormality, based on physical examination and imaging exams, to establish the correct early treatment,*

*and thus prolong the survival and quality of life of patients affected by it.*

**Keywords:** osteochondroma, osteochondromatosis, bone neoplasms.

**Author:** Filiação: Unirv - Goianésia.

## I. INTRODUÇÃO

A exostose hereditária múltipla, também denominada de osteocondromatose múltipla, foi primeiramente descrita há mais de um século por Hunter e Boyer<sup>1</sup>. Como forma de doença em 1849 Stanley a caracterizou, descrevendo um desarranjo do crescimento ósseo endocondral manifestado por protuberâncias ósseas, preferentemente metafisárias, cobertas por cartilagem hialina<sup>1</sup>.

Sua causa permanece desconhecida porém várias hipóteses têm sido aventadas. A lesão parece resultar da separação de um fragmento da cartilagem de crescimento que sofre uma herniação. O crescimento contínuo desse pedaço solto de cartilagem e sua subsequente ossificação endocondral formam uma saliência que se projeta da superfície óssea, recoberta com uma capa de cartilagem<sup>3</sup>. São as anormalidades do desenvolvimento do esqueleto mais freqüentes. A prevalência é aproximadamente de um para 50.000 indivíduos. O padrão de herança definido por gene autossômico dominante com penetração completa<sup>5</sup>.

Na forma múltipla da afecção são observadas: baixa estatura, deformidades dos ossos afetados e desproporção do tronco e dos membros. Encurtamento e deformidade osteoarticular, com consequente restrição da amplitude de movimento da articulação<sup>3</sup>. Os ossos mais comumente acometidos são os tubulares, escápula, pélvis e costelas. Apresentam menor envolvimento: carpo, tarso, patela, esterno, crânio, corpos vertebrais<sup>5</sup>. Diagnóstico pode ser feito por exames de imagem como radiografia simples e anatomopatológico.

O tratamento adequado implica ressecção completa do tumor e segmento do osso onde este surgiu<sup>2</sup>. O tratamento cirúrgico está indicado

quando há dor, irritação dos tecidos adjacentes, distúrbio do crescimento causando deformidade ou encurtamento dos membros, comprometimento da movimentação das articulações, compressão dos tendões, nervos periféricos, vasos e canal medular<sup>5</sup>.

## II. OBJETIVOS

O objetivo do estudo foi realizar um relato de caso de um paciente com transformação maligna da exostose múltipla hereditária. Ainda carece de mais esclarecimentos quanto à sua etiologia, manifestações clínicas e abordagem terapêutica.

## III. MÉTODOS

Relato de caso e análise de diagnóstico e conduta baseada na literatura publicada digitalmente referente a Exostoses múltiplas hereditárias com transformação maligna.

## IV. APRESENTAÇÃO DO CASO

Paciente de 41 anos, sexo masculino, há 5 meses apresentando protuberância óssea, na região do quadril direito, associada a dor, sinais flogísticos e aumento progressivo e agudo da lesão. O diagnóstico foi realizado através de dados clínicos, anatomopatológicos e de TC, que evidenciou lesão maligna no quadril direito, posteriormente sendo confirmado o quadro de condrossarcoma.

## V. DISCUSSÃO

A exostose múltipla hereditária (EMH) foi originalmente descrita há quase dois séculos por Hunter e Boyer. No entanto, como doença, quem a caracterizou foi Stanley, em 1849, descrevendo-a como uma falha do crescimento ósseo endocondral, manifestado por protuberâncias ósseas, cobertas por cartilagem hialina, ambas de aspecto histológico normal<sup>1</sup>. Sua causa etiologia é desconhecida, mas baseando-se na semelhança da capa cartilaginosa da exostose com a cartilagem de crescimento (fise), várias hipóteses têm sido propostas: todas relacionadas com alterações da fise<sup>3</sup>.

Alguns autores relatam que a prevalência da doença é de 1/50.000, embora outro estudo tenha

mostrado, na Europa, prevalência de 9/1.000.000<sup>2</sup>. Não existe predileção por gênero. Na maioria dos portadores há acometimento de outros membros da família<sup>5</sup>. As lesões raramente estão presentes no nascimento, sendo diagnosticados cerca de 80% dos casos durante a primeira década de vida<sup>5</sup>.

A exostose múltipla hereditária, apresenta quadro clínico extenso e de grande variabilidade de sinais e sintomas, o que faz com que a doença atinja de maneira bastante maléfica a qualidade de vida dos doentes acometidos. Variabilidade essa presente até em casos intrafamiliares, em que a genética é extremamente semelhante entre os portadores<sup>6</sup>. A presença de protuberâncias ósseas que se formam juntamente as placas ósseas dos ossos longos como fêmur, pelve e costelas. Devido ao tamanho os quais os tumores podem adquirir, possibilitando a compressão de várias estruturas, os acometidos podem vir desenvolver retardo e deformidade do crescimento esquelético, dor crônica e compressão neurovascular. Os tumores geralmente são simétricos nos ossos longos, e podem vir a causar deformidades principalmente em mãos, devido acometimento de ossos do carpo. Suspeita de transformação maligna advém de observação no aumento das tumorações e sensação de dor do doente.<sup>6</sup> Mais de 70 % apresentará algum tipo de deformidade, as mais típicas localizadas em antebraço e punho<sup>7</sup>.

O diagnóstico da EMH se faz baseado na ectoscopia clínica do paciente, associada a exames de imagem. Por se tratar de uma doença com aspectos bem determinados, a sua diferenciação com outras patologias de cunho ortopédico se torna, relativamente fácil, mas algumas apresentações atípicas podem dificultar. Como é uma patologia com manifestação clinicamente na primeira infância, sinais e sintomas sugestivos nessa faixa etária levam à suspeição da doença<sup>6</sup>. Radiologicamente as exostoses podem variar na sua forma, podendo ser sésil ou pediculada<sup>3</sup>, sendo a forma sésil a mais comum. Para determinar o diagnóstico clínico é preciso analisar os diferentes modos de apresentação da doença. O osteocondroma solitário, por exemplo, geralmente é assintomático, podendo vir a demonstrar incômodo no portador em dependência da sua

topografia<sup>3</sup>. Já osteocondromas múltiplos se apresentam com desproporção, do tronco e dos membros, com envolvimento severo de alguns ossos, que promovem encurtamento e deformidade osteoarticular, causando restrição de movimentos.

Por conseguinte, o uso de diagnóstico por imagem se mostra uma ferramenta indispensável para concluir o diagnóstico, quanto para analisar a severidade das lesões e decidir se a conduta será cirúrgica ou expectante. A radiografia reflete lesões compostas de tecido ósseo cortical e medular que se projeta para fora do osso acometido<sup>3</sup>, é exatamente essa projeção que se torna sinal patognomônico do osteocondroma. Nas radiografias com excesso de calcificação, podemos suspeitar de transformação maligna do osteocondroma.

Não obstante, alguns casos da doença podem se mostrar de formas atípicas, necessitando de outros métodos de imagem que possam mostrar mais detalhes das lesões. Sendo assim, a tomografia computadorizada complementa a radiografia, mostrando detalhes da continuidade do osso cortical, seus cortes axiais permitem melhor visualização de lesões em sítios anatômicos de maior complexidade como coluna vertebral e sítulo de membros inferiores e posteriores. Ao se optar por melhores imagens das estruturas adjacentes, a ressonância magnética é o método mais eficaz, auxiliando também na diferenciação de suspeita de malignização ao se analisar a espessura da cápsula que recobre o osteocondroma<sup>3</sup>. A cintilografia óssea não se mostrou tão benéfica na diferenciação e diagnóstico de EMH. Auxiliando o método clínico e radiológico, o estudo anatomopatológico pode vir a agregar na diferenciação de processos de malignização, mas é geralmente usado em casos mais avançados e de maior complexidade<sup>3</sup>

O tratamento básico para a EMH se baseia na ressecção cirúrgica, sendo indicado quando os osteocondromas comprometem estruturas vasculonervosas, interferem no funcionamento de algum membro, apresentam sinais radiográficos de malignidade ou, então, quando se tornam antiestéticos. O tratamento cirúrgico consiste na

exérese do osteocondroma, juntamente com uma parte do osso normal em seu pedículo e com o periosteio e bolsa sinovial que o recobrem<sup>(3, 4)</sup>.

Na EHM, a taxa de malignização, principalmente para condrossarcoma, é de 11% a 25% e o tratamento nesses casos também é cirúrgico, seguindo critérios oncológicos rigorosos e tentando ao máximo diminuir a morbidade do paciente<sup>(3, 4)</sup>. A taxa de recidiva após a retirada cirúrgica é de cerca de 5%, podendo ser precoces ou tardias. Já foram descritas recidivas de 6 meses a 14 anos de pós operatório.<sup>4</sup>

## VI. CONCLUSÃO

Por se tratar de uma comorbidade com significativo impacto na qualidade de vida dos pacientes que a possuem, a Exostose Múltipla Hereditária requer estudos clínicos direcionados ao esclarecimento do diagnóstico e manejo adequados. O estudo em questão demonstra que o exame clínico mostra-se indispensável na suspeição da doença, bem como sua correta correlação com a radiografia e, em casos selecionados, tomografia ou ressonância magnética. Destaca-se, ainda, a importância do estudo anatomopatológico na diferenciação dos processos de malignização, porém, método este que permanece reservado para casos mais complexos. O desafio em questão trata-se do diagnóstico precoce da EMH, pautado na ectoscopia associada aos exames de imagem, visando reduzir as taxas de malignização e melhorar o prognóstico do paciente. Requer, ainda, aperfeiçoamento do tratamento não cirúrgico, bem como das técnicas cirúrgicas, objetivando a minimização das taxas de recidivas e menor morbidade ao paciente.

## REFERÊNCIAS

1. DAVID, Alexandre, Vilson Dalmina, Victor de Souza, Carlos Poisel Junior, and Gustavo K. de Oliveira. "Exostose múltipla hereditária", *Rev. bras. ortopedia*, n. 30, p. 855-60, 1995.
2. GOMES, Anna Caroline Nobre, Cláudio Régis Sampaio Silveira, Roberto Guido Santos Paiva, Antônio Gilson Monte Aragão Jr, and José Roberto Cavalcante Castro Jr. "Condrossa-

roma em paciente com osteocondromatose múltipla: relato de caso e revisão da literatura", *Radiologia Brasileira*, n. 6, p. 449-451, 2006.

3. SOUZA, Antônio Marcelo Gonçalves de, and Rosalvo Zósimo Bispo Júnior. "Osteocondroma: ignorar ou investigar?", *Revista brasileira de ortopedia*, n. 6, p. 555- 564, 2014.
4. ZYLBERSZTEJN, Sérgio, Orlando Rigueso, Luciano Ramires, Paulo César Nery, Gustavo Kaempf de Oliveira, and Ricardo Kaempf de Oliveira. "Osteocondroma cervical: relato de caso", *Rev. bras. ortopedia*, n.1, p. 73-5, 1998.
5. JR. RUIZ, Raul Lopes, Fernando Geraldi Dias, Ricardo Lucatto Baida, Daniele Cristina Cataneo, Antonio José Maria Cataneo. "OSTEOCONDROMATOSE MÚLTIPLA HEREDITÁRIA COM ENVOLVIMENTO COSTAL", *Rev. Col. Bras. Cir.*, 2006.
6. JENNES, I. et al. Multiple Osteochondromas: Mutation Update and Description of the Multiple Osteochondromas Mutation Database (MOdb). Human Genome Variation Society. Antwerp, v. 30, n. 12, p. 1620-1627, dec. 2009. JONES, K. B. Glycobiology and the Growth Plate: C



Scan to know paper details and  
author's profile

# Recalcitrant Humeral Nonunion: Biological Reconstruction Technique

Alejandro Meritano

## ABSTRACT

*Introduction:* Nonunion of the humeral shaft occurs in between 2% and 10% of non-surgically treated fractures and up to 15% of fractures treated with initial open reduction and internal fixation. The definition of recalcitrant nonunion is still under debate. The purpose of this study is to present the outcomes of a series of patients with recalcitrant pseudarthrosis of the humerus who were treated with stable osteosynthesis combined with biological reconstruction using allograft utilizing a novel surgical approach.

*Materials and Methods:* The series included 33 patients treated between 2012 and 2021. 20 women and 13 men, with a mean age of 65.4 years. The evolution time of recalcitrant pseudarthrosis was 33.3 months. The mean follow-up was 33.2 months.

*Keywords:* nonunion; recalcitrant; allograft; humeral fractures.

*Classification:* NLM: WB 600

*Language:* English



Great Britain  
Journals Press

LJP Copyright ID: 392884

London Journal of Medical and Health Research

Volume 24 | Issue 4 | Compilation 1.0



© 2024. Alejandro Meritano. This is a research/review paper, distributed under the terms of the Creative Commons Attribution-Non-commercial 4.0 Unported License <http://creativecommons.org/licenses/by-nc/4.0/>, permitting all noncommercial use, distribution, and reproduction in any medium, provided the original work is properly cited.

# Recalcitrant Humeral Nonunion: Biological Reconstruction Technique

Alejandro Meritano

## ABSTRACT

*Introduction: Nonunion of the humeral shaft occurs in between 2% and 10% of non-surgically treated fractures and up to 15% of fractures treated with initial open reduction and internal fixation. The definition of recalcitrant nonunion is still under debate. The purpose of this study is to present the outcomes of a series of patients with recalcitrant pseudarthrosis of the humerus who were treated with stable osteosynthesis combined with biological reconstruction using allograft utilizing a novel surgical approach.*

*Materials and Methods: The series included 33 patients treated between 2012 and 2021. 20 women and 13 men, with a mean age of 65.4 years. The evolution time of recalcitrant pseudarthrosis was 33.3 months. The mean follow-up was 33.2 months.*

*Results: Out of a total of 33 patients treated with this technique, 32 (97%) achieved a complete consolidation and one patient had a partial consolidation. The average consolidation period was 4.6 months and the complete osseous integration of the allograft was 8.1 months. For the functional evaluation, the visual analog scale (VAS), ASES score, Constant score and elbow motion arcs were taken into account.*

*Conclusions: Even among experienced surgeons, the treatment of recalcitrant pseudarthrosis of the humerus remains an obstacle and an unsolved challenge. The use of a specialized osteosynthesis material added to a bone allograft fixed with screws significantly increases mechanical stability, allowing early range of motion, and works as an osteoinductive and osteo-conductive scaffold, all of which are essential for consolidation.*

**Keywords:** nonunion; recalcitrant; allograft; humeral fractures.

## I. INTRODUCTION

Humeral diaphysis fractures occur between the upper edge of insertion of the pectoralis major proximally and the supracondylar ridge distally. These injuries constitute 1.2% of all fractures in adults,<sup>1</sup> and have an annual incidence of between 10 and 20 per 100,000 inhabitants.<sup>2-5</sup> In published studies, the incidence of nonunion in humerus fractures varies considerably, from 2% to 10% of conservatively treated fractures, and 15% of operated fractures.<sup>6-8</sup> This variance is attributed to the unusual vascular contribution of the humeral diaphyseal area, which in 93.8% of cases is represented by a nutrient foramen.<sup>9</sup> Most foramina are located in three-fifths of the humerus and have a downward direction towards the elbow joint.<sup>10,11</sup> Fractures located in this segment can damage the nutrient supply and bring problems for consolidation, especially when extrinsic factors or morbidities, or intrinsic factors related to the type of immobilization or fixation used, coexist, altering the 'diamond concept' of Giannoudis et al.<sup>12</sup> needed for healing. In this way, the evolution of the fracture can be towards hypertrophic or atrophic non-union, the latter is the most frequent. Pseudarthrosis of long bones remains a major problem worldwide and that of the humerus is no exception, it is a condition difficult to treat even in expert hands.

The term nonunion has been defined in several ways, and there is up to 55% disagreement about the right time to consider it.<sup>13</sup>

The US Food and Drug Administration defines it as a "fracture that is at least 9 months old and has not shown any signs of healing for 3 consecutive months." Others have recommended that, for long bones, the entity should be considered within a period of six months, during which no signs of radiological consolidation of the fracture are evident.<sup>14</sup>

Accordingly, the definition of 'recalcitrant non union' is even more difficult. According to some authors, it refers to nonunion that does not respond to conventional treatment in any of its variants in patients who have had surgery at least three times over a two-year period.<sup>15</sup> Others consider them as those that require more than one intervention to heal.<sup>16</sup> In their study of 125 patients, Wiss and Garlich argue that the main risk factors for this type of condition are the number of previous procedures, the history of infection and the initial treatment of the fracture.<sup>16</sup> We define recalcitrant nonunion as a fracture that does not respond to conservative or surgical treatment with at least one of the following characteristics:

- For conservative treatment, we take into account the lack of consolidation over a period of two years, in patients without major risk factors, and one year in those with two or more risk factors (mentioned below);
- for surgical treatment, a minimum of two previous operations without clinical and radiological signs of consolidation.

Although numerous studies have been published on the treatment of nonunion when there is no diaphyseal consolidation of the humerus, where surgical reduction and osteosynthesis combined with autologous bone graft is considered the gold standard, little has been written about the difficult scenario that represents the management of recalcitrant nonunion.

The objective of this article is to communicate the clinical and radiological outcomes obtained in a consecutive series of patients with recalcitrant nonunion of the humerus evaluated retrospectively, by prospective treatment with stable internal osteosynthesis associated with biological reconstruction with non-irradiated frozen structured allograft using a telescope technique or a novel 'Onlay 90°- 90°' technique of placement, according to the deficit of bone stock and the type of nonunion to be rescued.

## II. MATERIALS AND METHODS

It is a series of 37 patients with recalcitrant nonunion of the humerus, evaluated retros-

pectively, analytically and descriptively, between 2012 and 2021, in the Hand and Reconstructive Upper Limb Surgery Service, operated on by a level V expert surgeon and a level IV advanced surgeon, from the same surgical team, according to the Tang classification.<sup>17</sup>

The following inclusion criteria were considered: 1) patients with recalcitrant nonunion of the humerus, with previous failed conservative treatment or surgery including those with a history of infection, 2) patients with definitive failed treatment by our surgical team and 3) patients with a postoperative follow-up of at least one year. The exclusion criteria were: treatment of nonunion with a different technique from that proposed.

This reduced the sample to 33 patients. In the first evaluation, all consulted for pain and functional impairment.

The series consisted of 20 women and 13 men, with an average age of 65.4 years (range 27-80). They were grouped according to the kinematics of trauma into high-energy (patients <50 years) and low-energy accidents, such as falls from own height (patients >50 years). The progression time of recalcitrant nonunion was 33.3 months (range 3-120). The average number of previous surgeries was 3.28. Patients treated conservatively (15.15%) averaged 31.2 months until surgery (range 12-51) (Tables 1 and 2).

The mean follow-up of all patients was 33.2 months (range 12-75) and the clinical evaluation included the Constant-Murley score, visual analog scale (VAS), *American Shoulder and Elbow Surgeons Score* (ASES) and elbow functionality using goniometry. In the treated patient population, different risk factors for the development of this condition were identified (Table 3).

The following studies were requested as routine and preoperative planning: comparative anteroposterior and lateral humerus radiographs, preferably digital; computed tomography with 3D reconstruction and 'skip' punch biopsy of the affected segment in cases of doubt or history of infection. In four patients with several previous

anteroposterior and lateral humerus radiographs, preferably digital; computed tomography with 3D reconstruction and 'skip' punch biopsy of the affected segment in cases of doubt or history of infection. In four patients with several previous surgeries (more than 4) and more than one osteosynthesis plate, rapid printing 3D models were used for preoperative planning in order to quantify the bone defect zone and correctly choose the implant and the exact length of the bone graft or non-irradiated frozen structural intercalary allograft. In the remainder, the measurement was performed with the routine preoperative studies requested. If a larger bone resection was necessary because of the infeasibility or doubtful vitality of the ends observed during surgery, planning was modified during the surgical procedure. It should be noted that this in situ modification does not create a complication, since, in all cases, a homolateral total humerus allograft is requested.

Radiological evolution was analyzed with digital anteroposterior, lateral and oblique radiographs and computed tomography at 6 weeks, 3, 6 and 9 months.

On the other hand, for rescue surgery with the proposed technique to be successful, we believe that several fundamental factors must be taken into account in planning. For this, we developed the 'hexagon rule' which is very useful for diagnosis and preoperative planning in these difficult scenarios (Figure 1). This scheme takes into account the patient's inherent risk factors, joint stiffness, disuse bone atrophy, range of motion and resorption at the level of the nonunion focus and operculum closure. We believe that the previous analysis of this hexagon allows us to evaluate therapeutic possibilities, choose the best reconstruction technique for each particular case and assemble an intraoperative logical sequence during the technique.

We propose a technique based on three essential principles of fracture treatment:

- Rigid stabilization of fragments
- Stimulation of the osteogenesis process
- Early range of motion exercises

To these principles, we add Giannoudis' diamond concept.<sup>18,19</sup>

### *Surgical technique*

As already mentioned, this technique was designed based, firstly, on the classic concepts of diamond healing described by Giannoudis,<sup>18,19</sup> where the presence of osteogenic cells, osteoinductive mediators and an osteoconductive matrix in the focus is necessary; and secondly, risk factors (summarized with the hexagon rule), where bone stock, disuse osteoporosis and the stiffness of neighboring joints (shoulder and elbow) produce, biomechanically, greater stress at the level of the focus and are common causes of failures in traditional methods. Some published complications due to morbidity of the autologous bone donor zone, such as pain, functional impairment and bruising, were also considered, especially if the bone stock requirements were large and required hospitalization of certain patients. Through meticulous preoperative planning, two modalities of biological reconstruction can be used as an adjunct to stable internal osteosynthesis according to bone stock deficit and bone quality at the time of intervention. We chose 5 cm of bone defect as a cutting point because we can shorten the limb to that extent without compromising neurovascular structures and obtain a rigid assembly with the technique used, facilitating soft tissue healing and patient tolerance, even though we prefer to maintain anatomical length whenever possible.

*Deficit <5 cm in length:* biological plate or strut cortical frozen non-irradiated humerus allograft placed in an arrangement we call 'Onlay 90°- 90°' associated with ground allograft (canopy technique).

*Deficit >5 cm in length:* non-irradiated frozen structured allograft of the humerus, intercalary or 'telescope' associated with intramedullary ground allograft.

A correct preoperative planning can minimize errors and speed up surgical times (Figure 2).

### *Key sequence and steps*

- General anesthesia or plexus block assisted by ultrasound and sedation. Positioning of the

patient in the dorsal position at 45° (beach chair position), with the exception of the distal third performed in the ventral or lateral position with a support at elbow level.

- Expanded or posterior deltopectoral approach when nonunion is near the supracondylar region with electroscalpel (Covidien®) to reduce bleeding and pain, and improve skin aesthetics.
- Frozen or punch biopsy when there is doubt or history of infection (in cases with >5 polymorphonuclear leukocytes per field a cement spacer is made with antibiotic - Masquelet technique).
- Antibiotic prophylaxis 30 min before surgery with 2g IV cefazolin, followed by a booster dose within 2 hours of starting the procedure.
- Resection of keloid scars, if any.
- Neurolysis and repair of the radial or ulnar nerve under microsurgical magnification. This step can be time consuming especially if the patient has had several previous surgeries or radial nerve neuropraxia.
- Treatment of the nonunion focus: decortication, saucerization of the site without consolidation, resection of bone tissue with macroscopic aspect of necrosis, regularization of ends, alignment (Figure 3).
- Osteosynthesis: with 3.5/4.5 LC-DCP plate with at least four bicortical screws at each end; Phyllos® type plates or anatomical plates for the lower end of the humerus according to the topography of the recalcitrant nonunion to be treated (Figure 4).

In defects <5 cm in length, structural humerus allograft (biological plate) struts of equal length to that of the osteosynthesis plate are used, fixed to the native bone by 3.5/4.5 mm compression screws placed anterior to 90° of the plate that is usually located on the lateral face acquiring a fixation system of 90°-90° ("Onlay 90°-90°"). In this way, a rigid and stable assembly is obtained that allows early range of motion, favors the incorporation of the allograft and prevents its reabsorption (Figure 4). At the native bone-structural allograft interface, a ground allograft is placed in the form of a 'canopy' (Figure 5) to generate greater osseointegration and fill the spaces that may remain at that interface. Figure 6

shows a schematic of the surgical technique when the defects measure <5 cm.

In defects >5 cm in length, a frozen non-irradiated humerus allograft is placed in structural intercalary or 'telescope' form to increase the rigidity of the assembly, associated with osteosynthesis in lateral compression of the same characteristics as those used for defects <5 cm and placement of ground allograft in an intramedullary way (Figure 7).

In both techniques, vancomycin 2 g powder is always added to the allograft.

If there is joint stiffness due to immobilization or previous surgeries (shoulder-elbow), an arthrolisis of the glenohumeral or distal joint is performed at the elbow level, a key step to achieve a normal distribution of forces and avoid overloads at the repair site.

Intradermal skin closure is performed, without drainage and usually without static immobilization. Postoperative antibiotic prophylaxis is not administered.

### III. REHABILITATION PROTOCOL

After one week, the protocol of assisted passive range of motion of the shoulder and elbow joint, and treatment of surgical scarring are initiated. From the third week onwards, active range of motion and increased muscle toning exercises are indicated, the exercises should have a progressive controlled load until corroborating the osseointegration by CT scan with metal suppression.

### IV. RESULTS

At the last evaluation, 32 of the 33 patients (97%) treated with this technique had complete consolidation; six (18.18%) had been treated with intercalary graft in the 'telescope' form and 27 (81.81%), by allograft strut; in one case, partial consolidation was achieved that did not require a new procedure, because the patient had no symptoms (Table 2).

The period of consolidation observed on CT scan for the presence of bridges of bone trabeculae

across the focus of nonunion was 4.6 months (range 4-9). The time required for complete allograft osseointegration is even longer and is around 8.1 months on average (range 7-11) (Figure 8). The average follow-up was 33.2 months (minimum 12, maximum 75).

In two cases, platelet-rich plasma was used as an adjuvant. One was intercalary and the other 'Onlay 90°-90°'. This method was chosen due to the poor bone quality of the region of the humerus near the focus of consolidation and the number of previous surgeries (more than 7). There was no difference from treatment without platelet-rich plasma in terms of consolidation times, although we believe it is an additional biological contribution.

Patients with more rapid consolidation had fewer previous surgeries (<2), no history of infections and fewer or no comorbidities (<3 risk factors [Table 1]).

Shoulder arthrolysis was performed in seven cases (6 in the proximal humerus and the remaining in the diaphyseal location) and elbow arthrolysis was performed in four cases (distal humerus), no post-surgical infections or radial nerve palsy were recorded. Three patients had suffered a previous infectious condition treated with surgical debridement and intravenous antibiotics. In no case was resection of more than 1 cm of nonunion focus necessary. One patient required a second intervention for material breakage ("Onlay 90°-90°" technique) after a fall from his own height, two months after surgery. The material was removed and a new osteosynthesis was performed with the same reconstruction technique and the final consolidation occurred after nine months. There were no major complications, such as deep or superficial infection, loosening of osteosynthesis material or nerve lesions (radial paralysis), reabsorption or allograft fracture, with any of the aforementioned techniques. As negative outcomes, we must mention the aesthetic defect in some patients, which is directly proportional to the number of previous surgeries but has no impact on interpersonal life; the transient postoperative pain referred to the volume of the implant, which

disappears after the ninth month of rehabilitation; and the postoperative hematoma, which may appear with the consequent increased risk of infection if a thorough hemostasis is not performed.

Visual analog scale (VAS), ASES score, Constant-Murley scale and elbow arcs of motion were considered for the functional assessment (Table 4).

According to the VAS, the average preoperative score was 8.7 (range 7-10). One month after the operation, it was 5.2 (range 3-8); at six months, 2.2 (range 1-5); and at 12 months, 0.9 (range 1-3).

Regarding the ASES score, only the patient-reported section was used. The average score was 12.3 (range 7-15) before surgery; 17.1 (range 11-19) after the first month; 22.5 (range 20-25) at 6 months; and 27.1 (range 24-30) after a year.

The postoperative evaluation of shoulder function according to the Constant-Murley scale was performed after one year and yielded the following results: excellent (14 patients; 42.4%), good (13 cases; 39.3%) and fair (6 cases; 18.1%) (Figure 9).

Regarding elbow function, the range of motion was also evaluated at one year, and the results were: 10-130° (22 patients; 66.6%), 15-130° (5 cases; 15.1%), 20-115° (3 cases; 9%), 30-115° (2 cases; 6%) and 40-105° (1 case; 3%).

The poorer outcomes were obtained in those patients whose focus of nonunion was closer to the joint (shoulder/elbow), and when the evolution time was >4 years, with extensive soft tissue compromise or previous infectious process.

## V. DISCUSSION

Even among experienced surgeons, the treatment of recalcitrant pseudarthrosis of the humerus remains an obstacle and an unsolved challenge. The personal history, the time of disease evolution, and the condition of the soft tissue and bone quality as a result of previous surgeries or disuse make preoperative planning and surgical technique difficult, and the results unpredictable,

resulting in a not insignificant rate of complications.

Stable internal fixation and autologous bone grafting remains, for many, the gold standard procedure for the management of humeral nonunion with satisfactory outcomes in terms of consolidation. Its use is not without complications or morbidity, especially from the donor area when grafting is performed in large numbers; in addition, some of these patients require hospitalization to control pain.

At the same time, the allograft has been shown to be useful as a structural and biological contribution, especially advantageous if there are large bone defects, avoiding the morbidity of the donor zone,<sup>20,21</sup> but with possible risks of infection or reabsorption.

Several authors have described the use of autologous and heterologous grafting in the treatment of humerus nonunion with very good outcomes.

Garbayo Marturet et al. presented five patients >65 years with diaphyseal nonunion of the humerus of more than 18 months of evolution, treated with LCP locking plates, decortication, and ground allograft or autograft, with a 100% consolidation rate. They define recalcitrant nonunion as a major bone defect caused by implant mobilization, a biological factor significantly altered by the loss of vascular supply as a result of multiple interventions, and a functional loss characterized by joint stiffness and muscle and tendon alterations, similar to the Giannoudis diamond concept, regardless of the time since nonunion or the number of previous operations.<sup>22</sup> Campochiaro et al. added the use of platelet-rich plasma to the treatment of nonunion using LCP locking plates and structural allograft, treating nine patients and achieving complete consolidation in an average of seven months.<sup>23</sup>

Gogus et al. use structural bone allograft for complex primary fractures of the humerus and femur in patients with osteopenia (mostly elderly) and describe it as a novel idea.<sup>24</sup> Unlike in this study, stabilization is performed in parallel. We

believe that the “Onlay 90°-90°” arrangement gives more rigidity and better mounting for fixing.

Van Houwelingen et al. treated six patients with a technique similar to one of our suggestions (structural allograft plus rigid osteosynthesis), with the exception that the graft was fixed with plate screws as a 180° ‘sandwich’ (lateral plate plus medial structural allograft) with 100% consolidation in an average of three months.<sup>9</sup> The difficulty of this technique lies in the placement of the allograft at the level of the medial face of the humerus, since the humeral artery and vein, and the median and ulnar nerves run through this zone. Also, as already mentioned, the parallel placement and not at 90° could be less rigid in certain circumstances.

In a series of 10 patients with humeral diaphyseal nonunion treated similarly to Van Houwelingen, Hornicek et al. obtained a 100% consolidation rate at three months, except for one case at six months, and established that cortical allograft struts provided the structural support and osteoinduction to improve healing of fracture nonunion.<sup>25</sup>

Marinelli et al. treated 57 patients with diaphyseal nonunion of the humerus using locking plates associated with structural allograft with 93% consolidation. The comparison of the success rates of the various bone fixation techniques is limited by the fact that, in the relatively few published studies, the series are small and heterogeneous; in addition, the highly variable clinical and radiographic presentation of nonunion (mobile-rigid, atrophic-hypertrophic), surgical difficulties (osteoporosis, maintenance of bone stock, presence of fixation devices, shortage of soft tissue and previous scarring) and comorbidities (smoking, alcoholism and obesity) prevent comparison of the different series.<sup>26</sup>

The association between the use of a special osteosynthesis material for the humerus (Phylos® type plate for the proximal extremity, LC-DCP for the diaphysis and anatomical for the lower end of the humerus), added to the structured bone allograft, either in the form of a bone strut or intercalary telescope, fixed with screws,

considerably increases the mechanical stability, this allows an early range of motion, and acts as an osteoinductive and osteoconductive scaffold, helping to reconstruct bone defects and eliminate the increases in tension in the osteosynthesis material that could lead to a failure in the case of a native bone of poor bone quality, and thus has a more even distribution of loads.

The stable internal fixation and lack of irradiation of the bank allograft used in the processing not only prevent reabsorption, but also favor the integration usually observed in our casuistry eight months after the operation. We have not observed infections or rejections in treated patients, but reports of a low rate of disease transmission have been published, and would therefore be one of the weaknesses of using this type of biological input, although we think that this variable has a direct relationship with the quality of processing of the tissue bank. We think that the addition of vancomycin as perioperative prophylaxis along with allograft placement could explain this result in addition to what has already been mentioned.

Although levels of consolidation are high with the technique used, functional outcomes vary depending on the location of nonunion, they are poorer the closer it is to the joint, especially the glenohumeral. Despite this, patients have marked symptom relief, the VAS score drops significantly and they resume independence for daily living tasks.

Recalcitrant nonunion of the humerus usually occurs at the diaphyseal level.<sup>8,16,19,22</sup> There are several risk factors that predispose patients to this type of condition, some of them more preponderant than others. In most cases, it is due to incorrect management of conservative treatment or defects in the surgical technique used in the management of the initial fracture added to the type of patient to be treated. It is critical to consider the 'hexagon rule,' which is extremely useful for preoperative planning since it allows for the consideration of aspects that could lead surgical rescues to fail in the approach of this entity.

We present a new surgical technique of biological reconstruction with frozen non-irradiated

allograft that has achieved encouraging outcomes, which could address the adverse scenario represented by recalcitrant humeral nonunion.

Like other authors,<sup>21</sup> we observed that younger patients have a lower consolidation time rate than older patients. Another advantage of allograft use is the possibility of doing it on an outpatient basis. 87.8% of our cases were done under this modality, with immediate monitoring the next day of the procedure. This could be considered an advantage of the method as it reduces hospitalization time and costs, and the possibility of resolution in times such as the recent SARS-CoV-2 pandemic.

The use of locking plates in the treatment of this condition is of vital importance, because many cases of nonunion present with poor bone quality, as well as the use of structural allograft that provides additional rigid support.

As strengths of the study, we believe that our sample size is considerable in relation to the prevalence of the disease treated. The results in terms of consolidation and postoperative function are encouraging. The technique proposed in its two modalities is reproducible and offers certain advantages, such as avoiding the morbidity of the patient's own grafting and, in this way, being able to carry out the procedure on an outpatient basis and thus have the possibility of reducing hospitalization costs. In addition, the rigidity of the assembly obtained in the nonunion focus allows to quickly recover the mobility of the limb and thus improve the quality of life of patients, especially those who have been immobilized for more than a year.

On the other hand, it is important to mention that the study has certain weaknesses, such as its retrospective nature, without a control group of patients treated as standard and with a heterogeneous sample, although we think that, due to its frequency, it is difficult to find published comparative studies.'

## VI. CONCLUSIONS

We present a new technique to treat the difficult and unusual recalcitrant nonunion of the humerus using a non-irradiated frozen structured

allograft of the homolateral humerus, by means of two forms of assembly, according to the defect to be treated, associated with a rigid and stable internal osteosynthesis.

In our experience, the addition of ground allograft when using a 'strut' ('canopy technique') in the 'Onlay 90°- 90°' configuration or in the 'telescope' form has allowed us to obtain a high rate of osseointegration and, therefore, consolidation, with a rate of excellent and good outcomes in 81.7% of patients. When the location was close to either the glenohumeral or elbow joint, the outcomes were poorer.

The 'hexagon rule' provides relevant information that assists the surgeon in preoperative planning, and that could explain the rate of good outcomes achieved combined with a refined surgical technique.



Scan to know paper details and  
author's profile

# Management of Coalescence of the Little Lips in Girls at the Pediatric Surgery Department of the Donka National Hospital (Hnd) of the Conakry CHU

*Barry TS, Sacko MLS, Keita B, Baldé AB, Sangaré M, Dioubaté IK, Condé M & Agbo-Panzo D*

*Gamal Abdel Nasser University of Conakry*

## SUMMARY

**Introduction:** Coalescence of the labia minora, also called coalescence of the nymphs, is an acquired pathology of prepubescent little girls. It is relatively common but poorly understood by practitioners. The objective of this study is to report the management of this pathology in our African social conditions.

**Patients and Methods:** We carried out a retrospective descriptive study of the files of child patients aged less than 15 years treated for coalescence of the labia minora in the pediatric surgery department over a period of 5 years. The epidemiology, diagnosis, therapeutic and evolutionary aspects were studied.

**Keywords:** coalescence of the labia minora, vulva, little girl, treatment.

**Classification:** NLM Code: WP 103

**Language:** English



Great Britain  
Journals Press

LJP Copyright ID: 392885

London Journal of Medical and Health Research

Volume 24 | Issue 4 | Compilation 1.0



© 2024. Barry TS, Sacko MLS, Keita B, Baldé AB, Sangaré M, Dioubaté IK, Condé M & Agbo-Panzo D. This is a research/review paper, distributed under the terms of the Creative Commons Attribution-Noncommercial 4.0 Unported License <http://creativecommons.org/licenses/by-nc/4.0/>, permitting all noncommercial use, distribution, and reproduction in any medium, provided the original work is properly cited.

# Management of Coalescence of the Little Lips in Girls at the Pediatric Surgery Department of the Donka National Hospital (Hnd) of the Conakry CHU

Barry TS<sup>α</sup>, Sacko MLS<sup>σ</sup>, Keita B<sup>ρ</sup>, Baldé AB<sup>ω</sup>, Sangaré M<sup>✳</sup>, Dioubaté IK<sup>§</sup>, Condé M<sup>x</sup> & Agbo-Panzo D<sup>v</sup>

## SUMMARY

*Introduction: Coalescence of the labia minora, also called coalescence of the nymphs, is an acquired pathology of prepubescent little girls. It is relatively common but poorly understood by practitioners. The objective of this study is to report the management of this pathology in our African social conditions.*

*Patients and methods: We carried out a retrospective descriptive study of the files of child patients aged less than 15 years treated for coalescence of the labia minora in the pediatric surgery department over a period of 5 years. The epidemiology, diagnosis, therapeutic and evolutionary aspects were studied.*

*Results: We collected 28 files of coalescence of the labia minora and the annual incidence was 5.6 cases per year. The average age of our patients was 13 months with a range of 4 months and 2 years 9 months. Twenty-five patients (89.29%) were less than 2 years old. The circumstances of discovery were made by the mother at home by chance in 100%. The main reason for consultation was spontaneous vaginal closure. In the history we noted a case of perineal erythema and a urinary infection. In this study there were 20 cases of total form coalescence and 8 cases of partial form. All patients were asymptomatic.*

*Surgical detachment was done with the Halsted forceps (22 cases) and by the thermometer (6 cases). Local antiseptic care and 72 hours of oral antibiotic therapy were prescribed for all patients. Five patients were given an adjunct to a*

*prescription for estrogen- based colpotrophin ointment. The postoperative course was simple. After a 1-year follow-up, no recurrence was found in our study.*

*Conclusion: Coalescence of the labia minora remains an acquired and benign pathology in little girls. Surgical detachment under local anesthesia in a single attempt in our social context remains the only effective treatment.*

*Keywords:* coalescence of the labia minora, vulva, little girl, treatment.

*Author α σ ρ ✳ § χ v:* Department of Pediatric Surgery, Donka National Hospital of Conakry University Hospital, Gamal Abdel Nasser University of Conakry (UGANC)-Guinea.

*ω:* Department of Pediatrics Albert Royer Children's Hospital (HAER) in Fann de Dakar- UCAD.

## I. INTRODUCTION

The coalescence of the labia minora or nymphs is a fusion on the midline, of the free edges of the two labia minora of the vulva: the vaginal opening is then invisible. It is one of the least common and asymptomatic benign pediatric gynecological pathologies; it is always acquired [1, 2, 4]. It would be due to a lack of maternal hormones and a hygiene problem in the little girl [3, 4, 5]. Its diagnosis is clinical but often poorly understood by medical personnel and a source of anxiety for parents [1]. Its management differs in the literature [1, 4, 5, 6]. In this study, we report the experience of the Pediatric Surgery Department of the Donka National Hospital (HND) of the Conakry University Hospital by studying the

aspects: epidemiology, diagnosis, therapeutic and evolution of this anomaly.

## II. PATIENTS AND METHODS

This was a retrospective descriptive study carried out in the pediatric surgery department of the Donka national hospital of the Conakry University Hospital from January 1, 2017 to December 31, 2021 (i.e. a period of 5 years). All files of patients under the age of 15, seen in outpatient clinics and treated in outpatient settings for coalescence of the labia minora, were included in this study.

Incomplete files, other gynecological anomalies such as: congenital absence of the vagina, hymenal imperforation were excluded from this study. Data collection was done from patient consultation files and analysis was done using SPSS statistical software. The anonymity of the patients and the confidentiality of the data collected were guaranteed in this study. The aim of this was to report the epidemiological aspect, namely: the annual incidence, the circumstances of discovery, the age at consultation (age of diagnosis), the referent, the antecedents; - the diagnostic aspect: the character total or partial joining of the labia minora, the associated signs and the therapeutic and progressive aspect, that is to say the treatment and the results of the treatment. All patients were taken on an outpatient basis. The girls were placed in the gynecologist position. Exploration of the perineum revealed a vulva appearing flat without relief; we could not see the labia minora, the urethra or the vaginal opening. Traction of the labia majora showed the adjoining of the labia minora on the midline in the form of a translucent, avascular line from the vulvar frog to the clitoris. Treatment by the surgeon consisted in all cases of detachment (adhesiolysis) using curved Halsted forceps or the soft-tipped electronic thermometer under local anesthesia with EMLA cream or aqueous xylocaine gel 2 %; after asepsis of the vulva, the tip of the instrument was introduced, either into the opening if it was a partial form, or through the translucent median membrane of the labial adhesion in the case of a total form; the jaws of the pliers were then spread gently and quickly until completely opened. For

the thermometer we slide it up to the opening of the vagina. We see the reappearance of the labia minora, the vaginal orifice and the hymen as well as the urethral meatus. This procedure is painless and successful in a single attempt. Usually there is no bleeding or very minimal bloody oozing that resolves quickly. After the separation, a compress soaked in Betadine was introduced into the separation area for a few hours until the first urination or toilet. Post-operative care consisted of analgesics and antiseptics for local hygiene.

This treatment was associated in certain cases according to the surgeon with local hormonal treatment based on natural estrogen applied locally. A clinical appointment was given to the child for a clinical check-up.

## III. RESULTS

We identified 28 cases of coalescence of the labia minora in our study over a period of 5 years (January 2017-December 2021). The annual incidence was 5.6 cases per year. The average age of our patients was 13 months with a range of 4 months and 2 years 9 months. *Twenty-five patients (89.29%)* of the 28 patients were less than 2 years old. The circumstances of discovery were accidental by the parents at home (28 cases) during baths or when the girls' mother was wearing a diaper. Twenty-one patients were referred directly by the mother to the pediatric surgery consultation; seven out of 28 patients were referred by medical personnel. Two patients had a history of perineal erythema and a urinary infection respectively. The epidemiological profile of coalescence of the labia minora of our patients is recorded in Table 1.

All patients were seen in outpatient clinics. We noted in the consultation files 20 coalescences (71.43%) of total form and 8 cases (28.57%) of partial form (figure 1). Surgical undermining was the therapeutic procedure performed in all patients. This separation was done using the Halsted forceps (22 cases) and the thermometer (8 cases) under local anesthesia (figure 2). Oral antibiotic therapy and local antiseptic treatments were prescribed to the child. Five patients were prescribed colpotrophin (estrogen) ointment

postoperatively. The postoperative course was simple and after a 12-month follow-up, no recurrence was found in our study. Table 2 summarizes the diagnostic, therapeutic and evolutionary aspects.

#### IV. DISCUSSION

The coalescence of the labia minora results in complete or partial adhesion of the labia minora to the median raphe in pre-pubertal girls, making the hymen invisible [7]. Labial adhesion is uncommon according to several studies, it occurs in 0.6 -3.3 of prepubescent girls with an average of 1.5% of girls [5]. Its annual incidence varies depending on the studies. In our study the annual incidence was 5.6 cases and lower than that found in the literature (table 3). This difference could be explained by the type of study. Our study was not multicenter with a long study period like the study by Dieth et al [1]. The average age of discovery in our study was 13 months with extremes of 4 months and 2 years 9 months. *Twenty-five patients (89.29%)* of our 28 patients had an average age of less than 24 months. This situation is found in most studies with an average age of 12 months-23 months [1,5]. Late discovery is rare, as some authors point out [1, 2,4]. The discovery of the anomaly was made by chance by the parents (100%) and with the main reason for consultation: a spontaneous closure of the vagina noted by the girls' mothers. Some authors have mentioned the absence of a vagina as a reason for consultations [4]. Total labial adhesion was the most common (20 cases) in our study compared to 8 partial cases as in most studies [1, 2, 3]. All patients were asymptomatic. We did not note any associated signs or genitourinary malformations in the files. One patient had a history of perineal erythema and a second patient had been treated for a urinary infection. This antecedent situation is mentioned in the literature as a factor favoring the coalescence of the labia minora [1, 2,3]. It is anxiety about the sexual future of young girls that pushes parents to consult in our African context.

The management of coalescence of the labia minora is a subject of controversy. Most Western authors are in favor of therapeutic abstention, especially for asymptomatic children [4, 5, 6].

Therapeutic abstention is based on the impregnation of the vulva by the rise of estrogen hormones in the hope of spontaneous resorption (80%) [4,5]. On the other hand, other authors recommend treating the child as soon as the diagnosis is made in order to avoid complications such as urinary infection [1]. Hormone therapy would be the safest first-line treatment according to Scholer reported by Dieth et al [1], but this treatment takes 3 - 4 months on average without forgetting the side effects. Cases of recurrence and persistence of labial adhesion treated with hormonal therapy are reported in the literature and which subsequently required surgical release [6]. In our study, all the girls underwent surgical adhesiolysis under local anesthesia in a single attempt and hygiene measures with simple follow-ups. Our results are comparable to all reviews in our regions [1, 2, 3]. The arguments put forward in favor of our surgical treatment are that in our African context the long-term follow-up of patients is uncertain and many patients are lost to follow-up; on the other hand, conditions that affect the sex are poorly tolerated by our populations and the desire for an immediate result is almost required, at the risk of seeing these patients in the hands of traditional practitioners or unqualified medical personnel [1,2].

#### V. CONCLUSION

Coalescence of the labia minora is a relatively common benign condition in pre-pubescent girls, often overlooked by practitioners. Its diagnosis is clinical. There is no consensus in its therapeutic management. In our context, simple surgical removal of the labial coalescence of small children by a specialist would avoid genital mutilation by a non-specialist with psychological consequences for the child and his family.

## APPENDICES

*Table 1:* Epidemiological Aspect of Our Patients

Characteristics	N=28	n (%)
<b>Age groups (in months)</b>		
[4months-9months [		13(46.43)
[10 months-15 months [		6(21.43)
[16months-21months [		5(17.86)
[22-month-27month [		3(10.71)
[28 months-33 months]		1((3.57)
Total 28(100)		
<b>Circumstances of discovery</b>		
The mother 28		(100)
<b>Reference mode</b>		
Mother of girls		21(75)
Medical staff		7(0.25)

*Average age:* 13 months with extremes of 4 months and 2 years 9 months

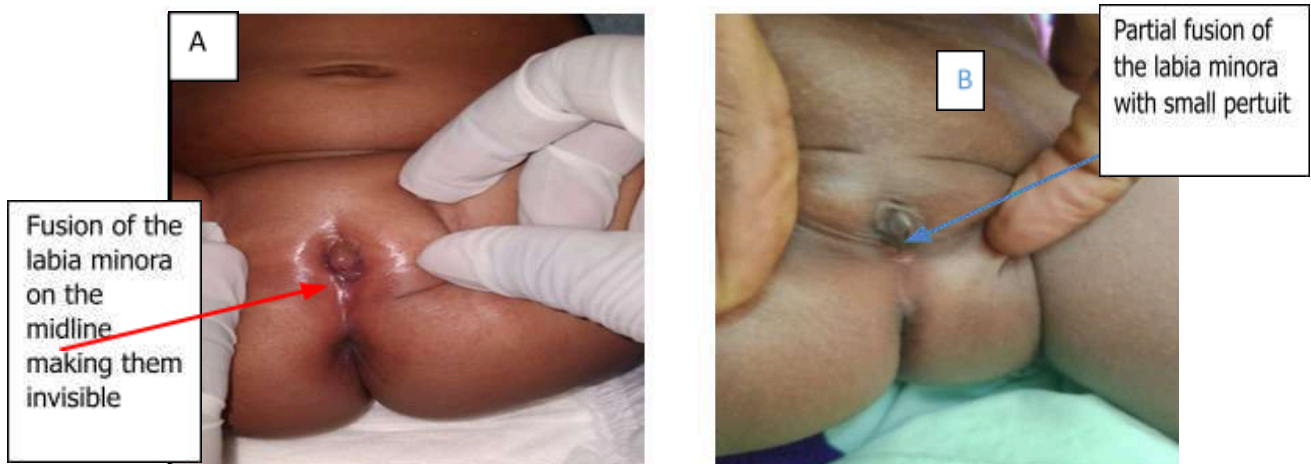*Table 2:* Diagnostic, Therapeutic and Evolutionary Aspects

Features	N=28	n (%)
<b>Reason for consultation</b>		
Spontaneous closure of the vagina		28(100)
<b>Type of abnormality</b>		
Total form		20(71.43)
Partial form		8(28.57)
<b>Therapeutics gesture</b>		
Adhesiolysis using Halsted forceps		22(78.57)
Adhesiolysis with the thermometer		6(21.43)
<b>Post-operative care</b>		
Antiseptic room		28(100)
Estrogen ointment		5(17.86)
<b>Aftermath of surgery</b>		
Simple		28(100)

*Table 3:* Annual Incidence According to the Authors

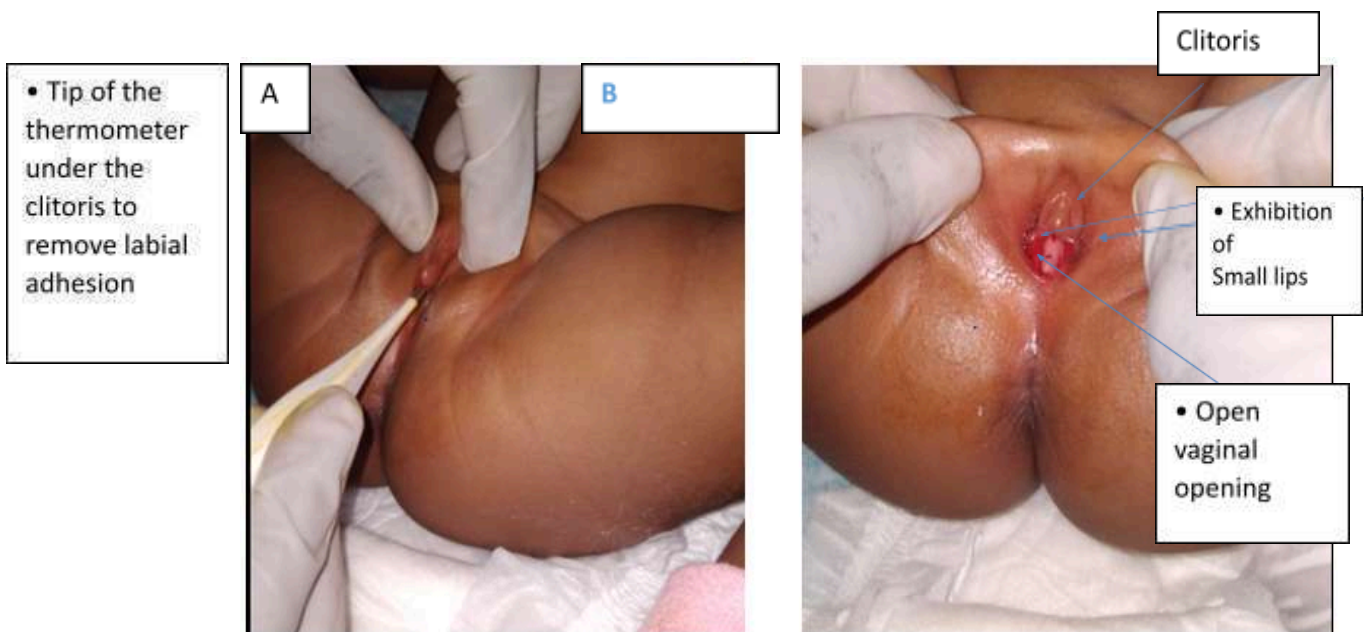
Authors	annual incidence
E. Thibaud [ 4]	40 cases/ year
Lahourou Grah Franck et al [2]	12 cases/ year
Dieth et al [1]	8 cases/ year
Coulibaly MB et al [3]	6 cases/ year
<b>• Our study</b>	<b>5.6 cases/ year</b>

• *Iconography*



*Figure 1:* Distribution according to clinical form:

[A]: Complete Form (infant 4 months );  
 [B]: Partial Form (6 months old infant)



*Figure 2:* 7 month old girl with coalescence of the labia minora

[A]: Thermometer separation under local anesthesia;  
 [B]: Satisfying result

**BIBLIOGRAPHICAL REFERENCES**

1. Dieth Atafy Gaudens et al. The coalescence of nymphs in the pediatric surgery department of Yopougon University Hospital: about 108 cases. Health Notebooks vol. 18, n°1, January-February-March 2008.
2. Lahourou Grah Franck et al. Coalescence of the labia minora in girls in 30 cases: Our experience. MALI MEDICAL 2021, Volume XXXVI, n°3, P 24-27.
3. Coulibaly MB et al. Preliminary experience of the management of coalescence of the labia minora in children: about 12 observations. Journal of Surgery and Specialties of Mali (JCSM) Volume2(2022), Number1, P: 1-5.

4. E. Thibaud, C. Duflos. Coalescence of the labia minora: should it be treated. *Journal of Pediatrics and Childcare* 17(2004) 411-413.
5. Charlene RIGOLLET. Coalescence of the labia minora in girls: physiopathogenesis, diagnosis and management. Available online at: [http://anciensite.clge.fr/IMG/pdf/Rigollet\\_coalescence\\_des\\_petites\\_levres.pdf](http://anciensite.clge.fr/IMG/pdf/Rigollet_coalescence_des_petites_levres.pdf) JC Mièret
6. *Stephanie Knudtzon, Stein Erik Haugen, Arne Kristian Myhre* . Labial adhesion – diagnosis and treatment. *Tidsskr Nor Legeforen* nr. 1st 2017; 137: 31 – 5. Available at: <https://tidsskriftet.no/en/2017/01/original-article/labial-adhesion-diagnostics-and-treatment>.
7. E. Medium, I. Ondima , AS Bachir , G. Moyen. Coalescence of nymphs in the pediatric surgery department at the hospital and university center of Brazzaville (Congo). *Journal of scientific research of the University of Lomé*, Vol.20N°4 (2018). Available at: <https://www.ajol.info/index.php/jrsul/article/view/184529> .